

Red Cerebral Veins: The Science, the Art, and the Craft

H. Hunt Batjer, MD, Salah G. Aoun, MD, Rudy J. Rahme, MD, and Bernard R. Bendok, MD

Since my earliest days in neurosurgery, vascular malformations of the brain have intrigued me as perhaps the most complicated and fascinating entity we are called to treat. I remember well the times of my internship when I walked into the operating room at Parkland Hospital in Dallas and watched Dr Duke Samson take on a large and complicated arteriovenous malformation (AVM). Typically, the early phases of the operation were very elegant and beautiful with the stunning features of the cortical representation of the lesions and the bright red hugely dilated veins. Also typically in those days when we had no endovascular capability for preliminary reduction in arterial input, the later phases of the operation were substantially less elegant with persisting arterial hemorrhage from the margins and often progressive distention of the brain itself with larger lesions, reflecting some unusual pathophysiological dysfunction.

Early in my career, I found and cited an article by Feindel and Perot¹ titled “Red Cerebral Veins: A Report on Arteriovenous Shunts in Tumors and Cerebral Scars.” The authors actually referenced some of the early observations of Penfield, who noted clear evidence of intraoperative arteriovenous shunting during seizure activity, and translated those unique observations into findings from the various traumatic, cerebrovascular, and neuro-oncologic conditions known to be associated with arteriovenous shunting.

The Honored Guest presentation focuses on 4 questions because of time constraint issues:

1. Why do AVMs form and recur?
2. Why do they become biologically active?
3. What causes the derangement of brain metabolism and function commonly observed?
4. Who should be treated and how?

A number of observations have been well established in the literature and should be used as baseline information. In a series of 5850 consecutive autopsies, McCormick² detected AVMs in 0.5% of brains studied. Numerous intraoperative and pathologic observations have clarified that there is direct arterial venous shunting without an intervening capillary bed. Typically, patients present at about 40 years of age, and common manifestations of this condition include headache, seizures, stroke, cognitive impairment, and hemorrhage.

THE SCIENCE

What do we know at this point? First, there is little evidence to support the congenital hypothesis that was prevalent during the early years of my training and practice. The idea was that the lesions probably form within the first 4 to 8 weeks of gestation as a result of failure of development of regional brain tissue, leaving direct connections or shunts that later mature into the adult form of AVM. We now know that AVMs can grow and occasionally regress spontaneously. We know that they recur in children. At least 5% of AVMs definitively treated in children ultimately recur either locally or at a site remote from the initial pathology. We know that AVMs can develop *de novo*. Thirty-four cases have been reported in the English language in the past 50 years in which clear documentation was achieved that at some point in the past a patient did not have an AVM but later developed one.³ AVMs are rarely familial. Twenty five cases of hereditary hemorrhagic telangiectasia families have been reported,⁴ and I personally have seen 2 additional families who were not reported. A variety of genetic studies have been reported that have implicated 900 genes that have been found to be either upregulated or downregulated in AVM tissue.³

When one inspects a cortically based AVM, one can immediately appreciate the beauty of these lesions. In addition to the striking aesthetics of the bright red veins and the tortuous vascularity, the observer has a clear sense of the ominous nature of these lesions. On reflection, one is confronted by the question: How could these lesions have ever developed? Traditionally, it was believed that AVMs developed in utero and remained static through life but with a propensity for becoming destabilized. The best evidence today suggests that some individuals are likely congenitally susceptible to developing AVMs but that environmental events can play a clear role in the initial formation of an AVM and lead to a very complex and dynamic behavior pattern in each patient. A number of points can be made regarding the pathobiology of these fascinating lesions. Clearly, genetics are involved, which can lead to vascular dysplasia and likely relate to the 2-hit hypothesis that is so prevalent in our understanding of many disease states today. Growth factors must play a large role, as do ischemic changes in tissue and hypoxia. Inflammation has a prominent role in what must destabilize lesions, leading to hemorrhage. In addition, unlike other types of vascular malformations such as cavernomas, AVMs produce unique hemodynamic stress on the cerebral circulation. Finally, powerful angiogenic factors

must also play an important role. In Figure 1, LeBlanc and colleagues highlight the role of the genes involved in the endoglin pathways, activin-like kinase-1 pathways (*ALK1*) and *SMAD4*.^{4a} Mutations in these growth factor pathways can lead to nuclear vascular dysplasia in the individual cell. Figure 2 illustrates that the first congenital mutation renders tissue increasingly vulnerable to further damage. This damage (the 2-hit hypothesis) can come from either environmental factors such as inflammation and growth factor overexpression or an additional somatic mutation. The second injury could subsequently lead to what we know as an intracranial AVM. As mentioned above, other factors also are highly important. Tissue hypoxia has been implicated in AVM genesis, recurrence, and growth. Inflammation has been linked to genesis, growth, and hemorrhage. Hemodynamic stress, which is unique to AVMs, likely predisposes to vascular injury and to the development of nidal and prenidial aneurysms. The arteriovenous shunt itself predisposes to tissue hypoxia in the brain surrounding the malformation.

As we know from a number of disease states, inflammation, which can be episodic and of unknown origin, has a strong impact on not only the genesis but also the behavior of AVMs. When inflammatory genes are upregulated, there can be a massive release of interleukin 6, which is a potent stimulator of the immune response; tumor necrosis factor, which is a potent inflammatory factor; apolipoprotein E2; and matrix metalloproteinase 9, which participates in the breakdown of the extracellular matrix.⁵ Figure 3 graphically illustrates the participation of inflammatory activity in destabilizing vascular malformations and leading to hemorrhage. A recent patient of ours brings up a visually obvious illustration of the role of angiogenesis in the role of AVM development. This patient presented with a right-sided cerebral ischemic episode related to unilateral moyamoya disease. As every component of their condition, these patients have some sort of angiogenesis factor leading to the proliferation of deep collateral circulation into the ischemic areas as a result of progressive obliteration of the internal carotid arteries. In this particular case, the patient also

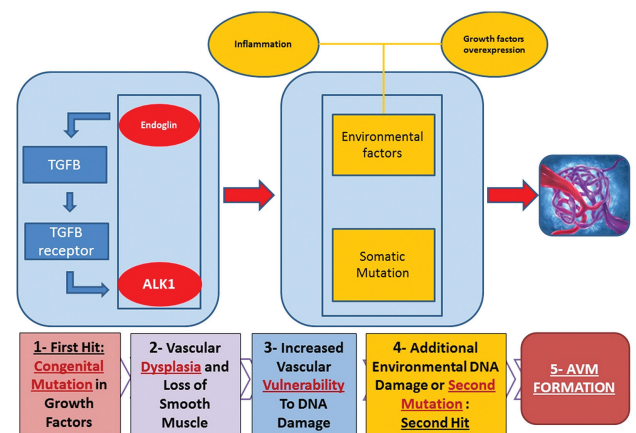


FIGURE 2. Illustration of the 2-hit hypothesis. AVM, arteriovenous malformation; TGFβ, transforming growth factor-β.

harbored an ipsilateral AVM (Figure 4). Finding both conditions in the same cerebral hemisphere without a shared pathophysiology seems extremely unlikely.

Why do AVMs recur in children? Moftakhar and colleagues⁶ suggested that there must be angiographically silent secondary areas or hidden compartments associated with AVMs in children. As indicated by some of my own experience and an interesting report by Sonstein and colleagues,⁷ this just seems improbable. In this report, all of the recurrent AVMs in children were associated with major elevations in vascular endothelial growth factor. Thus, it seems likely on the basis of a variety of scientific milestones and clinical observations that the formation and individual behavior of AVMS result from a complex biological tug of war involving heterogeneous factors, including hemodynamic stress, systemic and local inflammation, tissue ischemia and hypoxia, and angiogenesis.

Remarkable advances have occurred in the realm of advanced noninvasive imaging. Our imaging tools give us

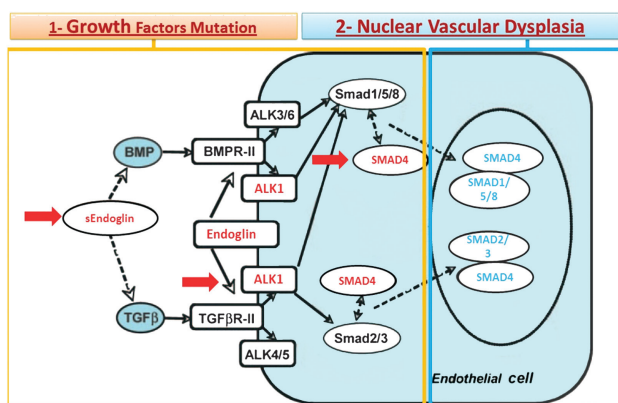


FIGURE 1. Possible model of the genes and pathways involved in arteriovenous malformation formation. Adapted from LeBlanc et al. BMP, bone morphogenetic protein; TGF, transforming growth factor.

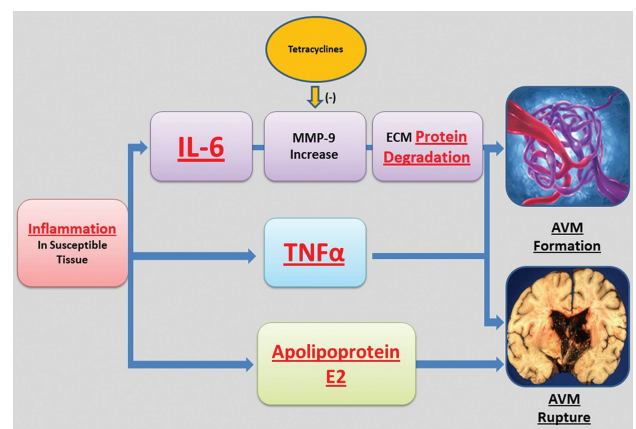


FIGURE 3. Role of dysregulated inflammation in arteriovenous malformation formation (AVM). ECM, extracellular matrix; IL-6, interleukin-6; MMP-9, matrix metalloproteinase-9; TNF-α, tumor necrosis factor-α.

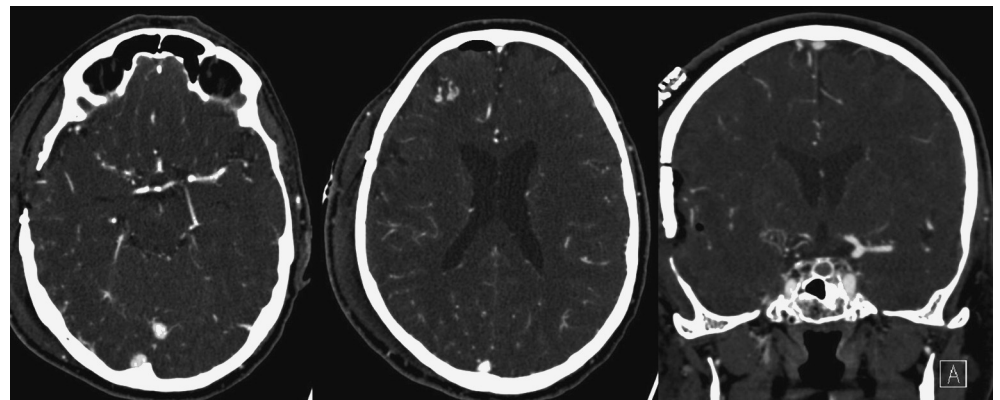


FIGURE 4. Cerebral computed tomography angiography of a patient with concomitant arteriovenous malformation and moyamoya disease.

a number of critical capabilities. First, the structure of an AVM can be defined. In my view, the 3-dimensional morphological information that can be gleaned from magnetic resonance imaging (MRI) gives us the most important information in considering whether to treat or not and, in fact, how to achieve an appropriate surgical exposure. These structural data are critical in patient selection. Functional MRI has added to our capabilities dramatically in that we can see cortical activation related to specific neurological functions in individual patients and relate them to the margins of the AVM. Finally, physiologic data can also be obtained noninvasively with quantitative MR perfusion techniques. Figure 5 illustrates the MRI data from a young teenager who suffered from intractable seizures. He had an AVM in the anatomic left motor cortex that was clearly shown on functional MRI not to be involved with motor activity in his right arm and leg. His AVM was resected, and interestingly, he awoke with a dense right hemiparesis that spontaneously cleared within 48 hours. Figure 6 also sheds important dynamic information on the physiology of AVMs. This particular patient underwent 4 embolization procedures as a prelude to surgical resection of a left temporal AVM. The functional MRI data in Figure 6 show a progressive increase in motor activation from his left hemisphere as flow was progressively reduced in the AVM and thus perfusion in the

normal brain was being restored. Dr Tim Carroll from Northwestern has developed unique capabilities that allow noninvasive and non-radiation-requiring imaging to, in many cases, replace catheter angiography. His technique, a radial sliding window at 6 frames per second, remarkably translates an intravenous injection of contrast into images that are superimposable on selective intra-arterial injections during digital subtraction angiography (Figure 7).⁸ His work allows the clinicians to gain critical information on the flow patterns within the AVM, any prenidial and intranidal aneurysms, and patterns of venous drainage.

Considerable research over the years has focused on the understanding of the surrounding brain both as an element of natural history and as a dynamic manifestation of incremental therapies directed at the obliteration of the AVM. Both single-photon techniques and positron emission tomography have been used to gain quantitative information, but both of these techniques require radiation. Dr Carroll's recent work with MR quantitative perfusion has given very comparable data

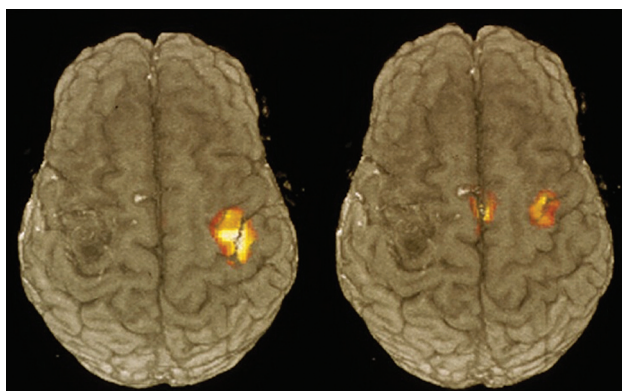


FIGURE 5. Quantitative magnetic resonance perfusion imaging scan showing sparing of the anatomic left motor cortex.

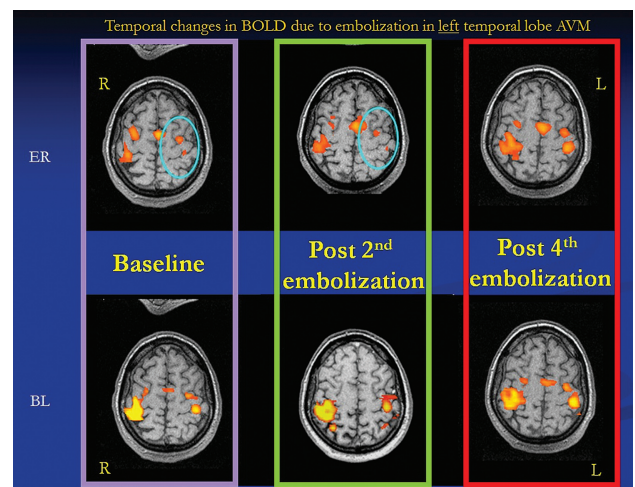


FIGURE 6. Functional magnetic resonance imaging showing a progressive activation of the left motor cortex with arteriovenous malformation (AVM) embolization and renormalization of cortical flow. BL, blocked design; ER, event-related design.

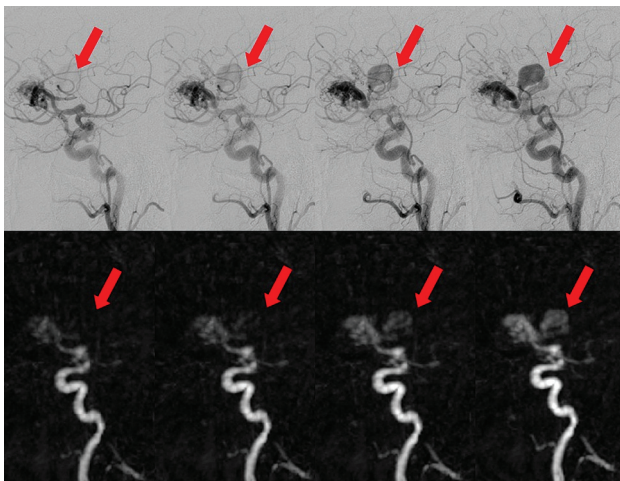


FIGURE 7. Comparative images of conventional digital subtraction angiography (series above) and 4-dimensional radial acquisition contrast-enhanced magnetic resonance angiography (series below) for cerebral arteriovenous malformations.

regarding the surrounding brain without the need for radiation (bookend spin-echo quantitative magnetic resonance perfusion; Figure 8). Recently, Dr Michael Markl was recruited to Northwestern University and has developed a very strong interest in intracranial vascular disease. His unique technique using 4-dimensional flow MRI has given us a novel means of understanding what is going on within the cerebrovasculature in the matrix of AVMs and in specific areas of venous drainage (Figure 9). These 4-dimensional data include clear and obvious 3-dimensional anatomy but also quantitative flow velocities in feeding arteries and draining vasculature. These images can be manipulated to interrogate even a single vascular pedicle and to give the clinician a fascinating way to predict the impact of a specific embolization procedure.

An area that has not been the focus of great attention but in fact deserves it is the cognitive impact of AVMs and their effects on quality of life. A couple questions can be asked:

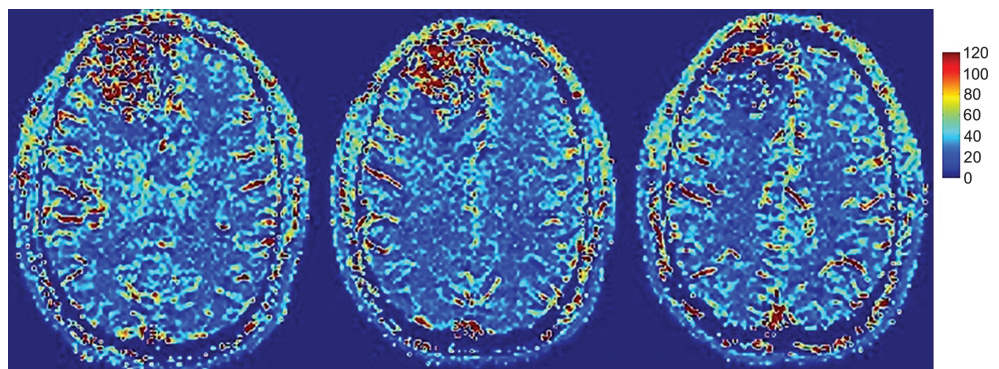
1. Why do AVM patients demonstrate baseline cognitive impairment?

2. Why does therapy often improve cognition, affect, and quality of life?

Unfortunately, to date, there is little hard evidence to bring to bear on these questions. Clinical reports have been conflicting in some areas, and there have been no prospective long-term studies. In addition, there has not been a standardized set of testing parameters used across populations. What has been shown, however, is that AVM patients have below-normal performance in the areas of intelligence, memory, and attention. It has been shown that AVM patients have 4 times the rate of disability from developmental learning disorders compared with the normal population. These deficits can be brought out with higher frequency if one uses more complex and demanding tasks. Figure 10 shows the areas of impairment commonly seen in AVM patients.⁹ They include reading disorders, impulse control problems, disorganization, drawing problems, and mathematical deficits. Anecdotal data have demonstrated that most treated AVM patients improve in these parameters over time. Often, there is an initial decline in function immediately after surgery that subsequently reverses over time. The improvement has been noted in both hemispheres and is most marked in the specific region of the AVM location. Improvements in neuropsychological and neurocognitive outcomes appear to be independent of age and sex, presenting symptoms, whether a hemorrhage has occurred, the mode of AVM treatment, or the size and grade of the AVM. Therefore, a number of hypotheses can be considered, including whether patients are initially impaired because of fear and reactive depression related to knowledge of their disease, ischemic impairment of the brain resulting from steal, direct compression of brain tissue by the lesion, or perhaps the effects of isolated or repetitive hemorrhage. This area of outcomes science is a very fertile area for exploration. Clearly, down the road, we are going to need to be able to demonstrate outcomes in very specific ways, unlike our current reporting methodology. Obviously, gross motor skills, hemiparesis, cranial neuropathy, etc, are important, but we need to be thinking ahead to executive functions and quality-of-life indicators both before and after treatment to determine the exact impact that this disease has on our patients and what the effects of interventions actually are.

A very important area in the national medical debate concerns the issue of radiation exposure. Vascular malformations

FIGURE 8. Bookend spin-echo quantitative magnetic resonance perfusion.



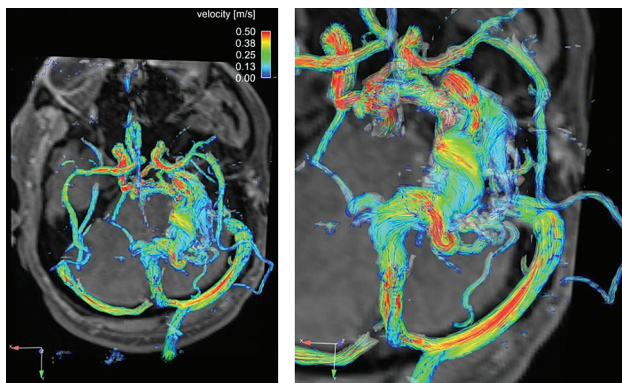


FIGURE 9. 4-Dimensional flow MRI.

of the brain are a major problem in terms of both diagnostic imaging and therapeutic imaging in the endovascular era. Little has been reported in this regard, but all of us have seen patients with substantial alopecia and often burns to the scalp and external ear after repetitive embolizations. Studies by Dr Minesh Mehta and colleagues from Northwestern have looked carefully at hippocampal dosage and its impact on subsequent cognitive impairment. In a recent study of patients undergoing fractionated radiotherapy for adult low-grade and benign tumors, neurocognitive testing was obtained at baseline and at 18 months. The authors noted that when there was a bilateral hippocampal dose of > 7.3 Gy, the patients ultimately developed cognitive impairment. The authors hypothesized, from their own rodent studies, that these findings may be due to a loss of radiosensitive neural stem cells in the subgranular layer. The implication of this work is that these stem cells are critical to our maintenance of cognitive functioning over time.

We now know a great deal about the actual dose that each of us receives from natural background radiation. In addition, doses from all of our traditional imaging studies such as x-rays, computed tomograms (CTs), CT angiograms, and diagnostic angiography have been quantified carefully. For example, catheter cerebral angiography carries a dose of 0.005 Gy, and brain CT angiography carries a dose of 0.004 Gy. Remarkably, AVM or aneurysm embolization procedures carry a dose of > 3.7 Gy. This is critically important because these doses are essentially half-way to the level of the hippocampal dose that could wipe out native stem cells. Obviously, many AVM patients receive more than a single embolization procedure. In a report by Moskowitz et al¹⁰ in 2010, cumulative radiation doses in a group of subarachnoid hemorrhage patients were studied. Remarkably, the strong majority of patients received > 7 Gy. We have modeled a number of individual clinical vignettes with representative AVM cases. The first vignette (Figure 11) represents a 2-cm basal ganglia AVM with intraventricular hemorrhage from an intranidal aneurysm. This patient underwent a typical surveillance imaging for hydrocephalus monitoring and ultimately an embolization procedure targeting the nidal aneurysm. Subsequently, Gamma Knife radiosurgery was deployed. The cumulative radiation dosage received in this model is 3.816 Gy plus 8 to 25 Gy for the Gamma Knife procedure. A second vignette illustrating a 4-cm parietal occipital AVM with intracerebral hemorrhage and intraventricular hemorrhage is also concerning (Figure 12). This patient underwent the routine critical care imaging surveillance followed by 2 embolization procedures for 2 vascular pedicles and ultimately surgery and postoperative angiography. In this model, the cumulative radiation received was 7.542 Gy. The big concern is whether the bilateral hippocampal dose was the same as predicted in this model. Ongoing research at Northwestern under Dr Mehta will ultimately settle this issue, but the preliminary results are very concerning for the long-term outcomes of our patients.

THE ART

Cleary, the art of managing simple and complex vascular malformations centers around the question of who should be treated and how. The primary consideration in dealing with this issue is achieving a best guess at that individual patient's natural history risks vs the risk of the various therapeutic alternatives, including expectant observation or anticonvulsants. Steve Ondra's important publication in 1990 studied the natural history of Professor Troupe's patient series in Scandinavia during an era when no real treatment was offered to patients. In a consecutive series of 160 symptomatic patients with a follow-up of 24.7 years, the authors detected a 4% yearly bleeding risk. This translated into an annual morbidity rate of 1.7% and an annual mortality rate of 1.0%. From the relatively primitive angiography studies available during those decades, important issues such as nidal aneurysms or venous stenosis simply cannot be determined.

J.P. Mohr and colleagues have made a very important contribution to this natural history question.¹¹ In their 2006 publication, they described a series from New York in which

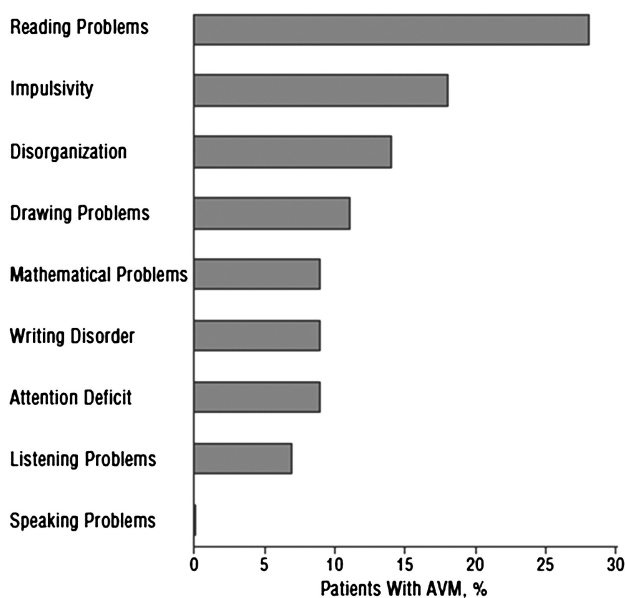


FIGURE 10. Common disabilities found in arteriovenous malformation (AVM) patients.

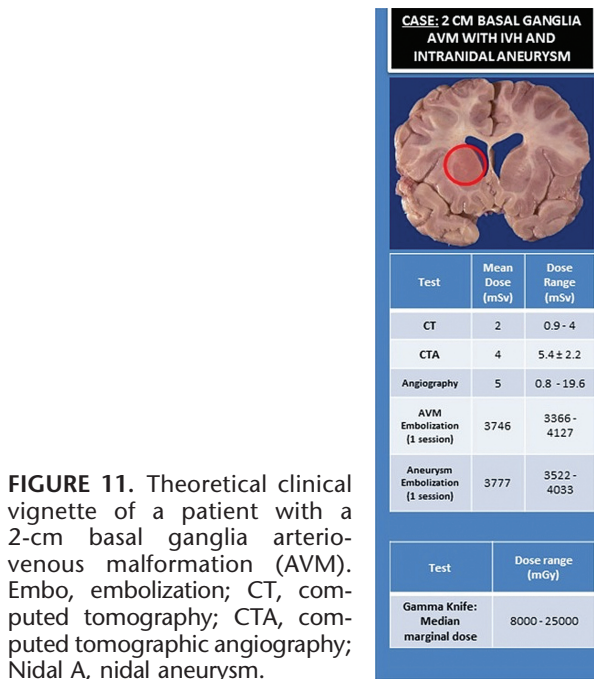
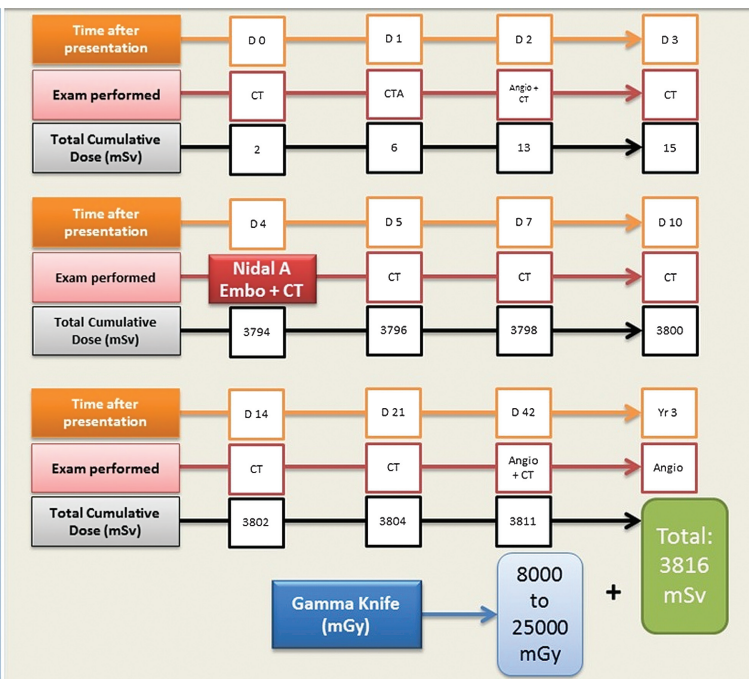


FIGURE 11. Theoretical clinical vignette of a patient with a 2-cm basal ganglia arteriovenous malformation (AVM). Embo, embolization; CT, computed tomography; CTA, computed tomographic angiography; Nidal A, nidal aneurysm.



patients were followed up from the time of diagnosis until the time that the first treatment was rendered. The days were cumulated, and the mean pretreatment follow-up was 829 days but with a median of 102 days. During that time, 6% of patients experienced an AVM hemorrhage. It is important to remember the very brief actual median follow-up. The authors found that there were 4 independent predictors of subsequent hemorrhage: older age, prior hemorrhage, deep

location, and deep venous drainage. A remarkable finding was that in patients with prior hemorrhage, deep location, and deep venous drainage, there was a 34% risk of subsequent bleeding before the first therapeutic intervention. This is very important because it is exactly those older patients with deep ruptured AVMs who are considered the optimal candidates for stereotactic radiosurgery. Clearly, a third of the patients in this series would have bled before any intervention

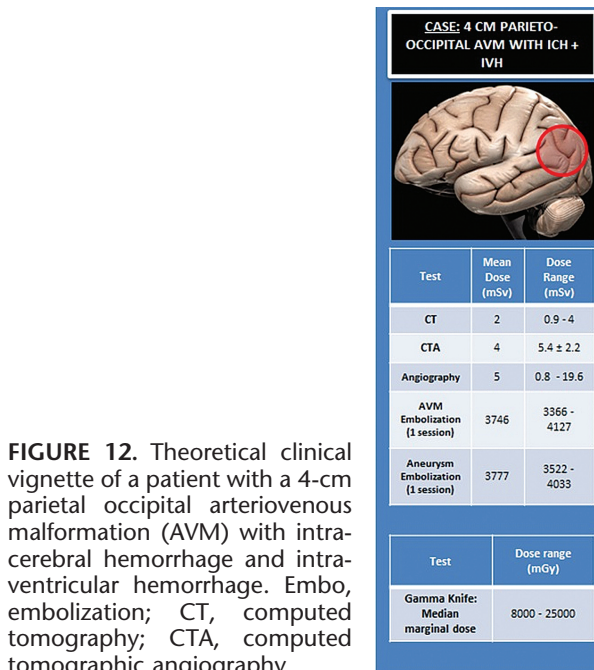
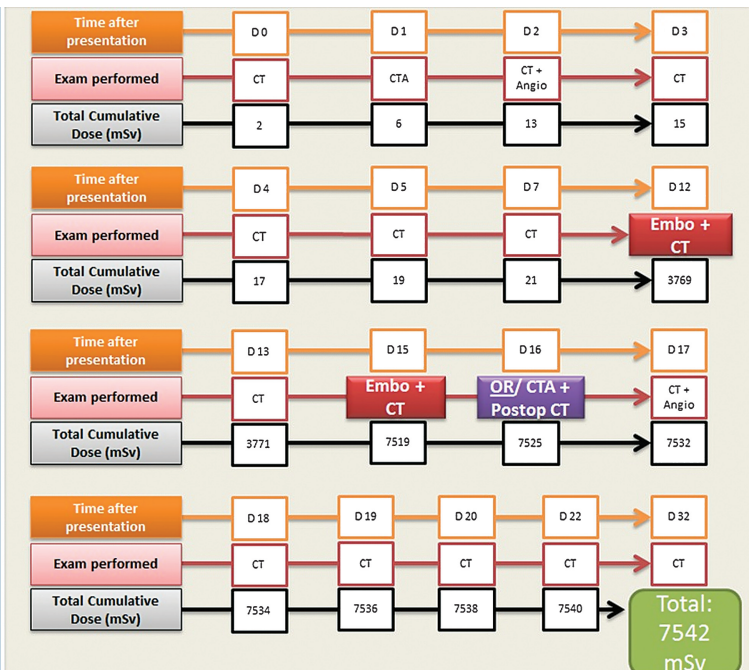


FIGURE 12. Theoretical clinical vignette of a patient with a 4-cm parietal occipital arteriovenous malformation (AVM) with intracerebral hemorrhage and intraventricular hemorrhage. Embo, embolization; CT, computed tomography; CTA, computed tomographic angiography.



could offer protecting benefit. Hernesniemi followed up Troupe's series by adding his own patients from Helsinki, so this series actually spans the interval from 1942 to 2005.¹² Two hundred thirty-eight patients were followed up for a mean of 13.5 years. Dr Hernesniemi detected a 2.4% annual hemorrhagic risk. The highest risk was in those who had previously bled, were of a younger age, had deep or infratentorial lesions, had lesions with exclusively deep venous drainage, and were in the first 5 years after the first hemorrhage. Clearly, there were some differences in these important experiences, but they represent the state of the art.

The question not answered by these data is, of course, whether there are modifiers to the natural history risk such as prenidial or intranidal aneurysms or venous stenosis at any point in the outflow network. Figure 13 illustrates an extraordinary case of a young Asian violinist who was seen in 2005 with a totally asymptomatic occipital AVM. She was very risk averse because of the potential threat to her visual system. When she was seen again in 2008, she had developed a complete homonymous hemianopia, and her imaging studies defined a new Chiari malformation (Figure 14). Remarkably, the morphology of her AVM had also changed dramatically. She now had a very angiomatous lesion with very limited venous outflow as a result of a progressive venopathy (Figure 15). Ultimately, it was necessary to perform an endovascular stenting procedure to keep one of her transverse sinuses open while embolization and definitive surgery could be accomplished. Her hemianopia did not improve. One very interesting patient is a 52-year-old woman whom I had seen 10 years before this presentation. She had a posterior fossa AVM, and treatment was advised. She did elect not to follow through and was seen 10 years later when she got a new neurologist and had a follow-up MRI. This study showed an important

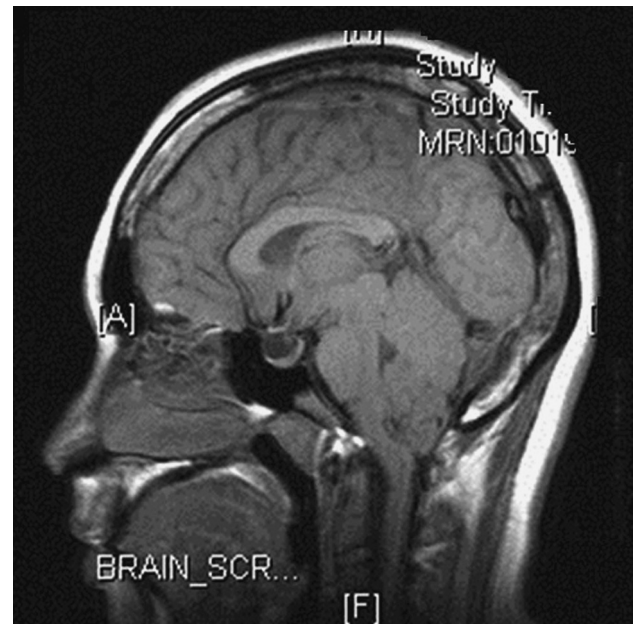


FIGURE 14. Magnetic resonance angiogram in the same patient as in Figure 13 with newly acquired Chiari malformation.

difference in that she had developed new fluid-attenuated inversion-recovery (FLAIR) signal right around the AVM. Repeat diagnostic angiography demonstrated that she had lost some of the anterior venous drainage of her AVM. At surgery, there were clearly thrombotic changes in the anterior drainage and a small amount of parenchymal hemorrhage adjacent to that thrombotic segment. Figure 16 illustrates the case of a 30-year-old man with a new-onset seizure disorder. His initial CT right after the seizure was negative. There was a very faint gradient echo abnormality and a clear FLAIR abnormality adjacent to the AVM (Figure 17). At surgery, the exact anatomic site of the FLAIR abnormality was found to be related to a very faint area of clear intraparenchymal hemorrhage and some old hemosiderin. This type of experience led us to be concerned that perhaps FLAIR signal or hypodensity on CT might in fact be a marker for biological activity in previously dormant AVMs. Right about that time, we saw a fascinating 51-year-old woman with

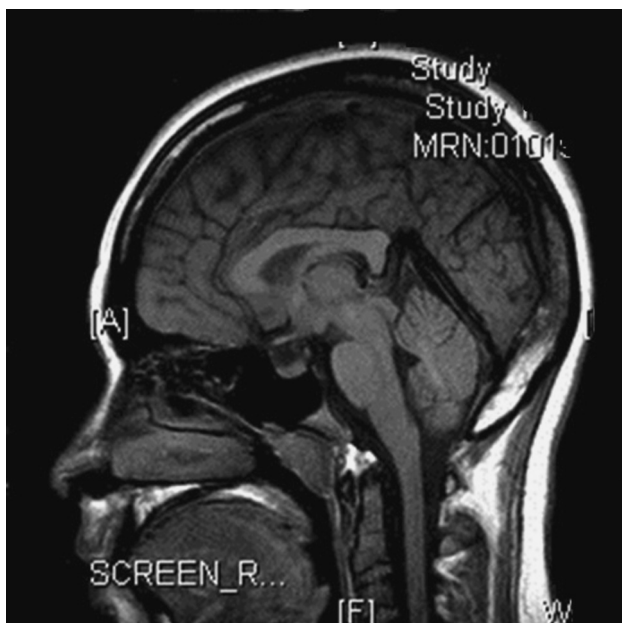

FIGURE 13. Magnetic resonance angiogram showing an occipital arteriovenous malformation.

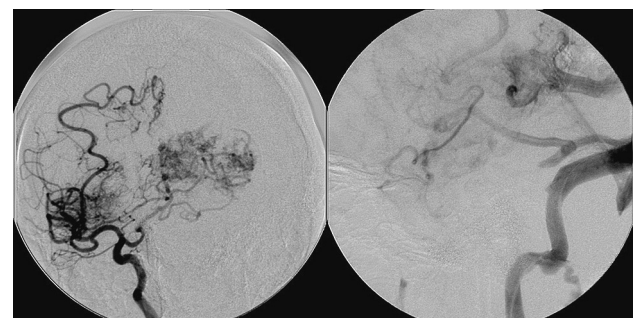


FIGURE 15. Evolving arteriovenous malformation with progressive venopathy and angiomatous transformation.

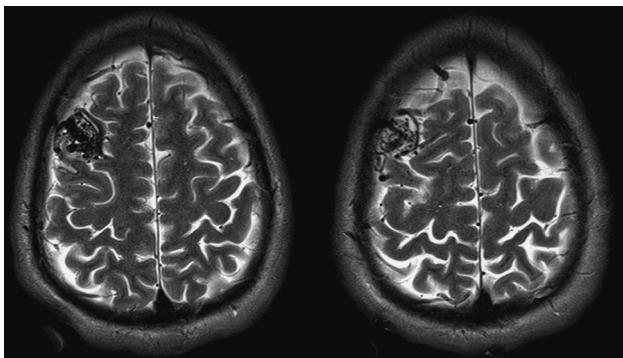


FIGURE 16. Case example: T2 sequence brain MRI showing a right parietal arteriovenous malformation.

rapidly progressing aphasia, hemiparesis, and complete visual field cut. I had seen her at least 10 years before; she was known to have a deep gangliar AVM and was completely asymptomatic at that time. I thought that surely she would be one with massive FLAIR abnormality. As noted in Figure 18, however, the amount of FLAIR abnormality in her drain adjacent to the AVM areas was quite trivial related to the magnitude of her neurological symptoms. Interestingly, her quantitative MR perfusion studies were not terribly impressive either. What could be causing this dramatic neurological progression without crystal-clear imaging signatures?

We went back and looked at a consecutive series from our own practice of 371 patients. We had appropriate clinical data available for 54% of those patients and also had high-quality imaging data on 36%. We noted that the only prior publication that we are aware of concerning FLAIR and AVMs was by Essig et al¹³ in 2000. They reported 45 consecutive untreated patients and found no correlation between FLAIR signal on MR and presenting symptoms. When we studied our data, we found that FLAIR was present on the initial MRI in 57% of patients. Interestingly, it was present in the majority of patients who presented for hemorrhage and was almost always absent in incidentally discovered AVMs. That led us to the perplexing question of whether we were dealing with “the chicken or the egg” problem. In other words, was the FLAIR a manifestation and result of prior hemorrhage, or had it been present before the bleed as a surrogate for regional inflammatory activity or activation of the AVM? Further analysis of our data showed that, interestingly, there was a subgroup of patients who initially had no FLAIR signal but on subsequent imaging had developed new changes. This key subpopulation of patients merits prospective studies. Following up a significant number of patients would indeed answer the question of whether we are looking at the chicken or the egg. Therefore, the real clinical consideration is whether FLAIR signal implies gliosis and inflammatory changes leading to AVM growth or rupture or whether in fact the rupture is the

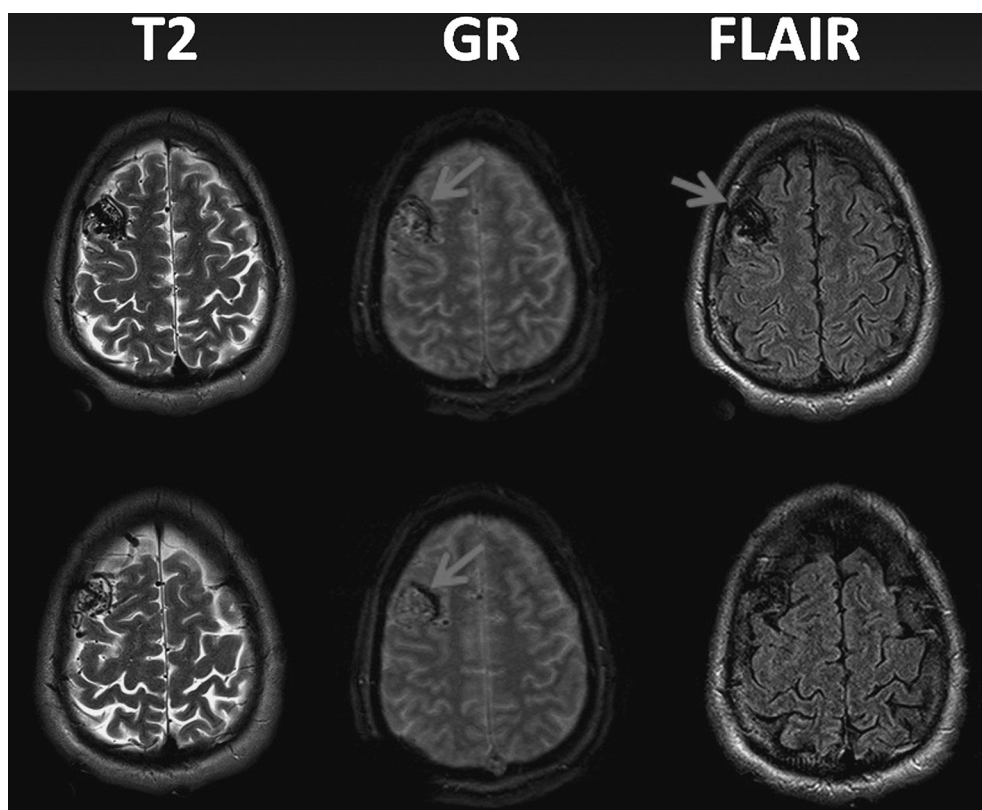


FIGURE 17. Case example: MRI T2, gradient, and fluid-attenuated inversion-recovery (FLAIR) sequences showing a right parietal arteriovenous malformation.

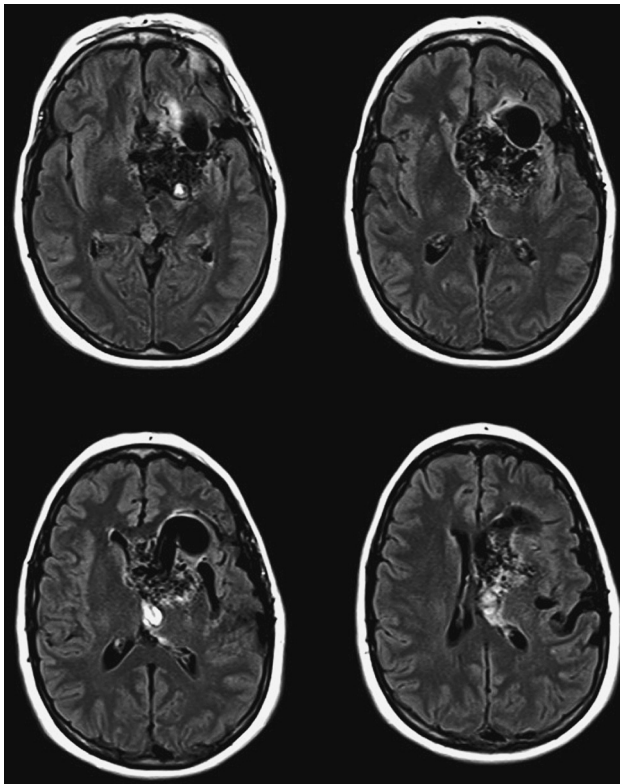


FIGURE 18. Case example: symptomatic deep ganglionic arteriovenous malformation with minimal amount of surrounding fluid-attenuated inversion-recovery signal.

cause of the gliotic and inflammatory changes leading to FLAIR signal.

The Spetzler-Martin grading system is a very nice and universally applied scale that considers size, eloquence, and patterns of venous drainage in a weighting of 1 to 5 with increasing complexity. During my years with Dr Samson, we worked very hard to develop our own grading scale and simply found that there were so many variables that the manifestations of this condition defied a simplistic scale. One has to consider not only the characteristics that may suggest a higher natural history risk but also the characteristics that would provide clues as to when treatment is extremely safe or highly dangerous. Therefore, I have adapted a scale that is focused on patient variables and lesion variables. As noted in the Table, the patient’s specific factors include age, sex (the Troupe data suggested that the year of pregnancy put a woman at substantially high risk of hemorrhage), presentation or biology, neurology of the patient, the general health of the patient, the patient’s understanding of the natural and treatment risks, and consideration of whether the family truly understood the issues at hand. The specific factors of the lesion that I feel are very important include size (however, lobar lesions are an exception), physiologic eloquence defined by functional MRI or intraoperative mapping, the morphology of the lesion (embryonal or angiomatous), the presence of nidal aneurysms/varices, venous stenosis, incorporation of perforators into the feeding system, and

TABLE. Patient and Lesion Factors for Arteriovenous Malformation Surgical Case Selection^a

Patient Factors	Lesion Factors
Age	Size (lobar?)
Sex	Physiologic eloquence
Presentation/biology	Embryonal vs angiomatous
Neurology	Nidal aneurysm/varix
General health	Venous stenosis
Understanding of risks	Perforators
Family on the same page	FLAIR?

^aFLAIR, fluid-attenuated inversion-recovery.

possibly the presence of FLAIR signal. Clearly, elderly patients do not tolerate interventions terribly well, but on the other hand, it is clear that even very large lesions that are purely lobar can be treated quite safely. In cortical or subcortical lesions near important neuronal tissue, the specific morphology (embryonal vs angiomatous) is absolutely critical. The angiomatous lesions definitely have viable brain tissue at their margins that is at risk. The recruitment of perforators also is a highly important variable because surgical treatment can result in bleeding from these fragile vessels and in their retraction into eloquent brain regions beneath the lesion, resulting in neurologic deficit.

THE CRAFT

I have had the great advantage of having been mentored by Drs Samson and Charles Drake in the surgical management of AVMs. Clearly, there are nuances and pearls that are critically important, but in contemporary AVM surgery, nothing is as important as prudent, conservative, and expert endovascular therapy before operative intervention. Simple polar and cortically based AVMs do not necessarily need preliminary embolization, but the more complicated lesions can be transformed from predictable surgical disasters to extremely straightforward exercises. The limit and length of this discussion preclude a detailed analysis of strategic deployment of endovascular therapy for this disease, but the bottom line is that, in my view, it should be used conservatively. The risk of stroke or hemorrhage increases with each embolization attempt. When you have a condition with a natural history risk of 2.5% to 4% annually, you cannot afford to waste much risk in the angiography suite unless the lesion happens to be one of those 5% to 10% of AVMS that are curable with contemporary techniques.

The dissection technique that I think is the most valuable is the use of spiral circumferential dissection. It is seductive to work the subarachnoid space and have the dissection go along beautifully, but if you are seduced into the depth in that minimal exposure, when you encounter hemorrhage down at the base, you have no room to deal with it. Avoiding that problem requires discipline. The subarachnoid dissection early on in a circumferential fashion is critical to understand the feeding anatomy and sacrifice

vessels only as they arborize into the AVM. Preliminary angiography will give many clues about the specific vessels en passage, but there are always surprises, and it is critical for the surgeon to be looking for branches that simply continue on past the AVM. Another critical moment in the dissection is when it is necessary to enter the brain. Ultimately, the subarachnoid space is elegant and beautiful and is extremely helpful in defining arterial anatomy, but it is not a safe anatomic plane in complex AVMs. By simply entering the pia in a deep sulcus, one can dissect around the gliotic and often hemosiderin-stained tissue that defines the perfect plane around the AVM. A point should be made about transvenous surgery. When AVMs are located subcortically and have no surface representation, the surgeon should look for venous drainage that does come to a brain surface. Using the subarachnoid space around such a vein provides a spectacular corridor of access down to the nidus itself.

We use 3 clinical vignettes to illustrate some of the more basic principles of technical AVM surgery:

The first is a young female patient who had been treated for a mesial occipital AVM 8 years before referral to our center (Figure 19). She had developed new and progressing visual loss and was found to have major FLAIR signal in the area of her prior radiosurgery and well beyond. The malformation had not been cured by radiosurgery, although it was altered. The dissection of her lesion was quite straightforward, as it usually is after prior radiosurgery. A small difficulty to manage was the arteriolar vessels that were in fact fibrotic. This lesion could be treated very much like a lobar resection.

The second patient presented with a major intracerebral hemorrhage. His lesion was fed heavily by the anterior cerebral artery on the right, and he had a deep intracerebral hemorrhage with dense deficit in both his left arm and left leg. In my view, any patient with a major intracerebral hemorrhage such as this and a relatively complicated AVM is much better managed by intensive and critical care means in an attempt to stabilize them and get them over the acute phase of the illness. Clearly, trying to perform an elegant microsurgical procedure on a brain in the condition that this patient's brain

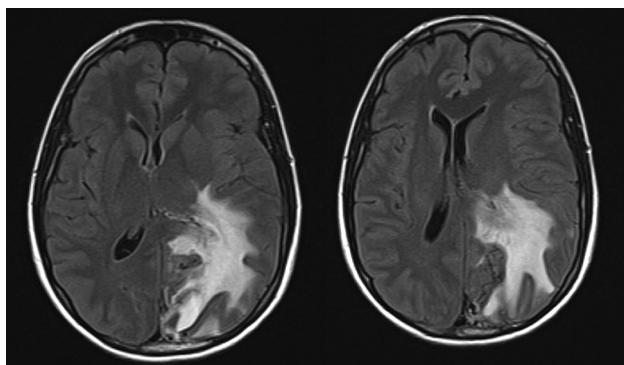


FIGURE 19. Case example: MRI showing major fluid-attenuated inversion-recovery signal in the area where a mesial occipital arteriovenous malformation was treated with radiosurgery 8 years ago.

was in is fraught with trouble. Unfortunately, in his case, as the edema front progressed, he actually deteriorated and required intervention within several days of his presentation. As shown in Figure 20, his initial angiogram demonstrated a crystal-clear major vessel en passage that passed his AVM and irrigated the motor cortex. Therefore, the entire surgical exercise was designed around preserving that vessel. The surgical nuance here was to get a very wide exposure across the superior sagittal sinus to give us easy access into the interhemispheric fissure to control and dissect fully the anterior cerebral feeding system. As expected, the brain was extremely distended, and we initially performed a corticectomy and evacuated a considerable portion of his intracerebral hemorrhage, which decompressed the brain nicely, gave us access to the hemispheric fissure, and allowed the dissection and obliteration of all feeding vessels. The critical vessel en passage had to be skeletonized completely because it gave off 20 or 25 feeding vessels directly into the AVM itself. Once the AVM was mobilized from that vessel, it could be moved around nicely and was resected uneventfully. The postoperative arteriography clearly showed preservation of that critical artery, and as a result, the patient made an outstanding recovery.

The final clinical vignette involves a 30-year-old man with a severe seizure disorder. He had a huge left frontal polar AVM (Figure 21). Once the decision to intervene was made, we performed 4 preliminary embolization procedures directed at various pedicles from the anterior and middle cerebral circulation. These embolization procedures were separated by a week to 10 days to give his brain time to accommodate to the new flow hemodynamics. As illustrated in the surgical video material, the dissection of the lesion itself was

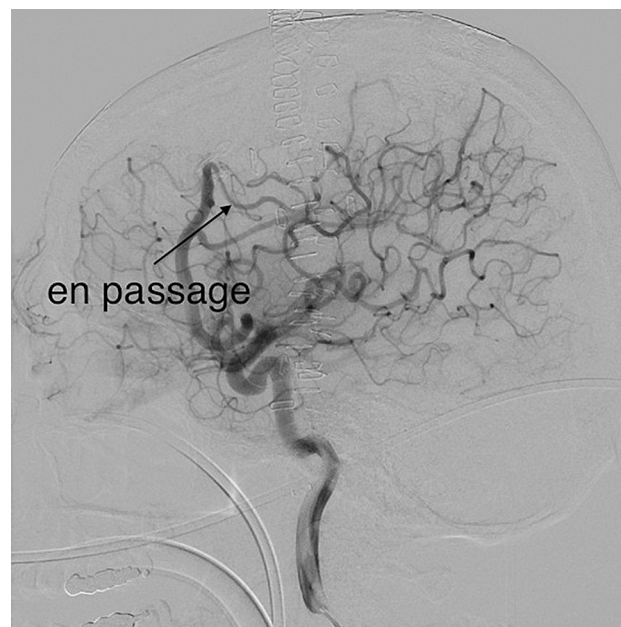


FIGURE 20. Case example: cerebral angiogram showing a big vessel en passage feeding the arteriovenous malformation and irrigating the motor cortex.

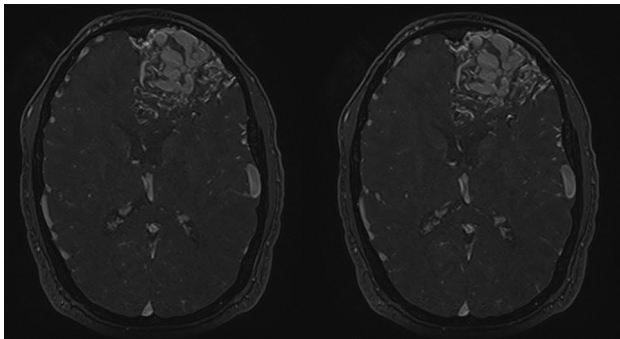


FIGURE 21. Case example: magnetic resonance angiography showing a very large left frontal polar arteriovenous malformation.

predicated first on a very wide craniotomy and subsequently by a frontal lobectomy initiated at the surface of the AVM where there was residual middle cerebral feeding (See the video file here: <http://links.lww.com/NEU/A484>). Even a huge lesion like this could be removed with minimal blood loss and an excellent clinical result. The nuances to success in that particular lesion were a deliberate series of conservative embolization procedures culminating in surgical treatment only when maximal benefit had been achieved. Surgery was essentially a frontal lobectomy with careful preservation of uninvolved middle and anterior cerebral vasculature.

Deep AVMs deserve an important but brief mention. I believe it is important to avoid the reflex to default to radiosurgery whenever one encounters a deep AVM. The question must be asked, “Is there a corridor of access?” Such closures can be present through the interhemispheric fissure, through the subarachnoid space, transventricularly, along a draining vein, or through a spontaneous hematoma. The case illustrated in Figures 22 and 23 is that of a male 18-year-old with 3 prior hemorrhages, prior radiosurgery, and a spastic hemiparesis. He was cognitively normal, and his most recent hemorrhage (Figure 22) resulted in distention and dissection of brain tissue right to the insula. This gave us beautiful access to a lesion via a transsylvian, transinsular opening, as well as an opening into the temporal horn in the lateral ventricle to control the anterior choroidal filling.

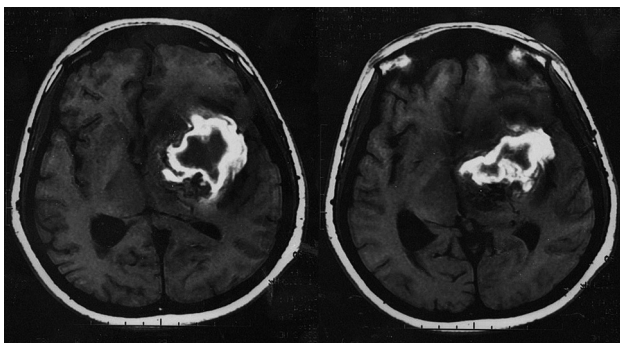


FIGURE 22. Case example: MRI showing a deep ruptured left gangliar arteriovenous malformation with intracerebral hemorrhage.

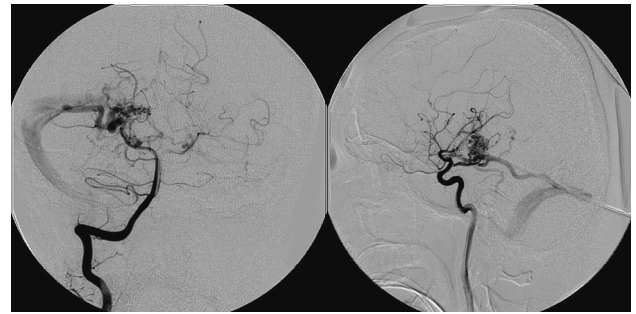


FIGURE 23. Case example: preoperative MRI showing the deep arteriovenous malformation.

This allowed removal of that deep gangliar AVM without worsening his neurologic deficit. His first postoperative angiogram is demonstrated in Figure 24.

HOW CAN WE ADVANCE THE FIELD?

We have a number of great opportunities to work collaboratively in specific areas that will allow us to learn more about this disease and its impact on the brain and to treat patients with less empiric strategies. It is critical that we refine our knowledge concerning clinically discoverable indicators of disease and stability. It is my belief that these will probably be imageable, but it may well be that there are other biological markers that we have yet to discover that will become relevant. This will allow us to intervene in patients who are currently asymptomatic but will not be so for very long. It is critical that those of us involved in educating the next generation continue to teach future endovascular, radiosurgical, and microsurgions the unique nuances of this set of diseases. As noted, our patients are being subjected to an enormous amount of radiation. We must develop means to more accurately measure and reduce radiation exposure. Ultimately, hybrid MR-based suites will be available to allow embolization procedures to be done without radiation. Subtle technological advances, including new device discovery, are required to realize this dream. The issues regarding quality of life are going to be critically important as we refine our ability to develop better outcome assessments. Detailed cognitive assessments with existing and new tools will allow us to better understand the impact of the disease itself on the patient’s neurological function and quality

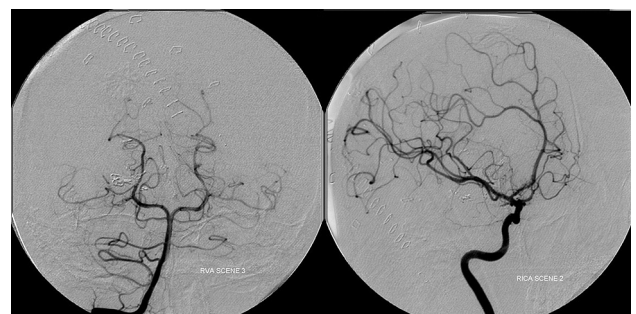


FIGURE 24. Case example: postoperative MRI showing complete excision of the arteriovenous malformation.

of life and certainly the impact of therapeutic intervention on these same parameters, including executive functions.

As illustrated in the preceding discussion, major advances are accruing at a rapid pace in neuroimaging techniques. We are now able to understand brain physiology at a baseline state and throughout the course of successive interventions. We can clearly see brain physiology and metabolism surrounding the lesions and dynamic 4-dimensional data from within. Our molecular biology colleagues have given us many very interesting and useful tools to understand what may create and activate brain AVMs. Further work may result in our ability to actually modify the behavior pattern of a lesion through nonsurgical means.

It should be completely understood that there are few areas of medicine in which team medicine and team science are required to manage complex cerebrovascular disease. Multidisciplinary teams of physicians, scientists, and technologists are required to develop a unique strategic plan for each patient and to execute that strategy with care, compassion, experience, and great attention to detail. A large amount of technological and human infrastructure is required to achieve great outcomes in this unique and nuanced cerebrovascular malformation.

Disclosure

The authors have no personal financial or institutional interest in any of the drugs, materials, or devices described in this article.

REFERENCES

1. Feindel W, Perot P. Red cerebral veins: a report on arteriovenous shunts in tumors and cerebral scars. *J Neurosurg.* 1965;22:315-325.
2. McCormick W. Vascular diseases. In: Rosenberg RN, Schochet SS Jr, eds. *The Clinical Neurosciences: Neuropathology.* Vol 3. London, UK: Churchill Livingstone; 1983:35-83.
3. Moftakhar P, Hauptman JS, Malkasian D, Martin NA. Cerebral arteriovenous malformations, part 1: cellular and molecular biology. *Neurosurg Focus.* 2009;26(5):E10.
4. van Beijnum J, van der Worp HB, Schippers HM, et al. Familial occurrence of brain arteriovenous malformations: a systematic review. *J Neurol Neurosurg Psychiatry.* 2007;78(11):1213-1217.
- 4a. Leblanc GG, Golanov E, Awad IA, Young WL. Biology of vascular malformations of the brain. *Stroke.* 2009;40(12):e694-e702.
5. Kim H, Marchuk DA, Pawlikowska L, et al. Genetic considerations relevant to intracranial hemorrhage and brain arteriovenous malformations. *Acta Neurochir Suppl.* 2008;105:199-206.
6. Moftakhar P, Hauptman JS, Malkasian D, Martin NA. Cerebral arteriovenous malformations, part 2: physiology. *Neurosurg Focus.* 2009;26(5):E11.
7. Sonstein WJ, Kader A, Michelsen WJ, Llana JF, Hirano A, Casper D. Expression of vascular endothelial growth factor in pediatric and adult cerebral arteriovenous malformations: an immunocytochemical study. *J Neurosurg.* 1996;85(5):838-845.
8. Eddleman CS, Jeong HJ, Hurley MC, et al. 4D radial acquisition contrast-enhanced MR angiography and intracranial arteriovenous malformations: quickly approaching digital subtraction angiography. *Stroke.* 2009;40(8):2749-2753.
9. Lazar RM, Connaire K, Marshall RS, et al. Developmental deficits in adult patients with arteriovenous malformations. *Arch Neurol.* 1999;56(1):103-106.
10. Moskowitz SI, Davros WJ, Kelly ME, Fiorella D, Rasmussen PA, Masaryk TJ. Cumulative radiation dose during hospitalization for aneurysmal subarachnoid hemorrhage. *AJNR Am J Neuroradiol.* 2010;31(8):1377-1382.
11. Stapf C, Mast H, Sciacca RR, et al. Predictors of hemorrhage in patients with untreated brain arteriovenous malformation. *Neurology.* 2006;66(9):1350-1355.
12. Hernesniemi JA, Dashti R, Juvela S, Väärt K, Niemelä M, Laakso A. Natural history of brain arteriovenous malformations: a long-term follow-up study of risk of hemorrhage in 238 patients. *Neurosurgery.* 2008;63(5):823-829; discussion 829-831.
13. Essig M, Wenz F, Schoenberg SO, Debus J, Knopp MV, Van Kaick G. Arteriovenous malformations: assessment of gliotic and ischemic changes with fluid-attenuated inversion-recovery MRI. *Invest Radiol.* 2000;35(11):689-694.