

Cervical Disk Arthroplasty: Patient Selection

Dale Ding, MD, and Mark E. Shaffrey, MD

The treatment of symptomatic cervical degenerative disk disease through an anterior transcervical retropharyngeal approach dates back to the late 1950s when the anterior cervical discectomy and fusion was first described.^{1,2} Since its inception, the anterior cervical arthrodesis has evolved into the gold standard treatment of symptomatic cervical spondylosis.³ Fusion rates for cervical arthrodesis are well over 90%, and more important, the procedure boasts excellent clinical success rates.⁴ However, cervical arthrodesis is not without its shortcomings. Fusion of ≥ 2 cervical vertebrae reduces the physiologic cervical range of motion and increases the biomechanical load on the remaining vertebrae, which likely accelerates adjacent-level degeneration.⁵ Radiographic evidence of adjacent-level disease will eventually be seen in the vast majority of patients after cervical arthrodesis,⁶ and the rate of symptomatic adjacent-level disease requiring reoperative is approximately 3% annually.⁷

Cervical disk arthroplasty was conceived with the goals of preserving physiologic cervical range of motion and reducing the incidence of adjacent-level disease. Although initial experiences with cervical arthroplasty in the 1960s produced disappointing results,^{8,9} 3 decades of technological advances have allowed the reemergence of more successful implant designs in the 1990s.¹⁰ Since then, several clinical studies have been undertaken worldwide to evaluate the efficacy of various cervical disk arthroplasty designs.¹¹ Preliminary results from randomized controlled trials are promising in the comparison of cervical arthroplasty and cervical arthrodesis for single-level degenerative disk disease.¹²⁻¹⁵ Although treatment of multilevel cervical spondylosis with arthroplasty has been reported with some early success,^{16,17} long-term prospective data have yet to be published.

Compared with cervical arthrodesis, cervical arthroplasty is still a relatively new procedure, accounting for $< 1\%$ of anterior cervical surgeries performed in the United States.¹⁸ Because of the innovative nature of the arthroplasty devices and some negative connotation associated with “fusion” procedures for patients, surgeons must resist the temptation to expand the indications for disk replacement surgery until the results are appreciated in an ideal patient population. It must always be remembered that anterior cervical discectomy and fusion and posterolateral laminoforaminotomy are excellent procedures with proven outcomes. Cervical disk arthroplasty will never replace these procedures in the majority

of circumstances. Thus, as with any relatively new surgical procedure, patient selection is a crucial determinant of success. Here, we define favorable and unfavorable clinical and radiographic characteristics for cervical arthroplasty and present patient cases demonstrating successful and unsuccessful use of cervical arthroplasty.

ILLUSTRATIVE CASE PRESENTATIONS

The following cases are illustrative of the tenets for proper patient selection and of the undesirable outcomes that can result from poor patient selection.

The first case is a 42-year-old man who presented with a 3-month history of axial neck pain and bilateral upper-extremity pain, left greater than right, that failed to respond to physical therapy and epidural steroid injections. On physical examination, he had bilateral triceps weakness, 4-5 on the left and 4/5 on the right, and left second, third, and fourth digit numbness. Figure 1 shows his preoperative cervical spine magnetic resonance image demonstrating a broad C6-7 disk bulge resulting in central canal and left greater than right bilateral neuroforaminal stenosis. The patient underwent a C6-7 arthroplasty with postoperative improvement in his radicular pain and triceps strength. At the 4-year follow-up (Figure 2), lateral flexion-extension and anteroposterior lateral bending x-rays showed good preservation of cervical range of motion.

The second case is a 44-year-old man with a 5-month history of axial neck pain and right upper-extremity pain refractory to physical therapy and epidural steroid injections. His neurological examination was significant for 4/5 right triceps weakness and right third digit numbness. His preoperative magnetic resonance image, shown in Figure 3, demonstrated a paracentral C6-7 disk protrusion, resulting in severe right neuroforaminal stenosis. A C6-7 arthroplasty was performed, resulting in postoperative improvement in radiculopathy. Figure 4 shows the patient's 4-year follow-up lateral flexion-extension x-rays, showing good preservation of cervical motion. A C-spine computed tomography demonstrates lack of both heterotopic ossification and osteolysis.

The third and final case is a 39-year-old woman with axial neck pain and bilateral upper-extremity pain unresponsive to conservative management. On examination, she had 4/5 bilateral wrist extensor weakness, right thumb and second digit numbness, and bilateral lower-extremity hyperreflexia. Her preoperative computed tomographic myelogram (Figure 5)

FIGURE 1. Preoperative magnetic resonance image of a 47-year-old man presenting with bilateral cervical radiculopathy. Lateral (A) and axial (B) C-spine magnetic resonance image at the level of C6-7 demonstrates a broad-based central disk bulge resulting in central canal and bilateral neuroforaminal stenosis that is worse on the left (arrow).

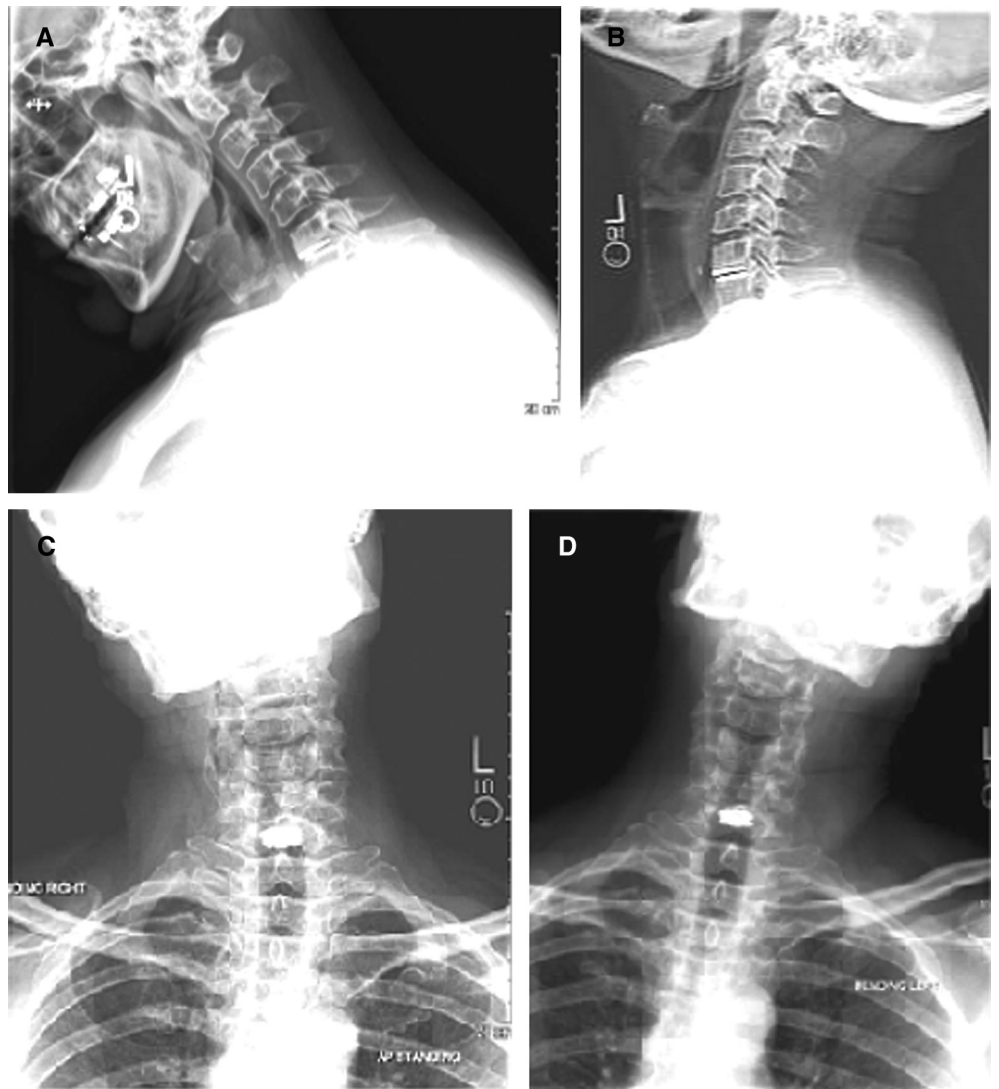
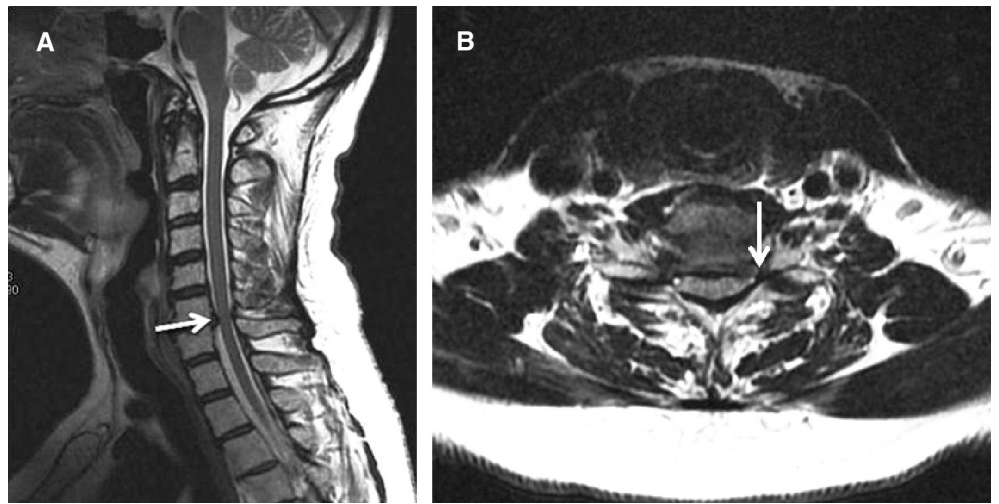
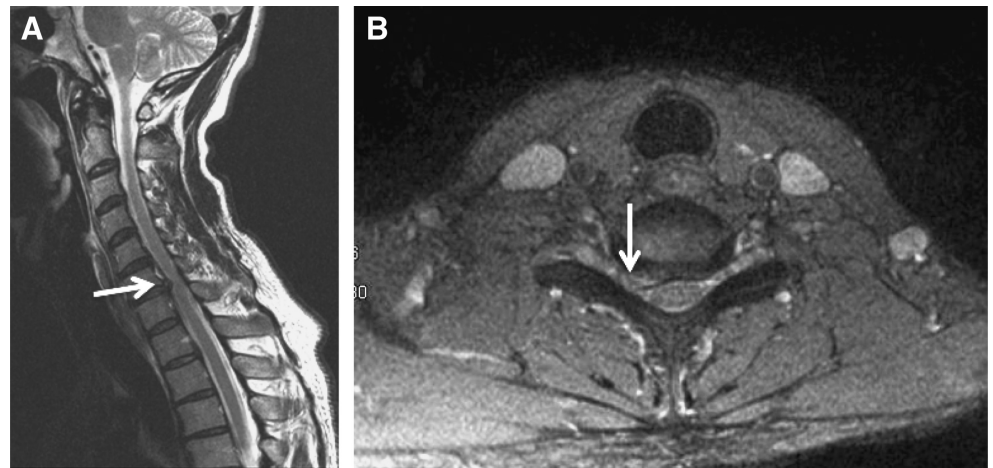


FIGURE 2. Postoperative lateral flexion (A) and extension (B) and anteroposterior lateral (C and D) bending x-rays at the 4-year follow-up of the same patient as in Figure 1 demonstrating preservation of dynamic cervical motion.

FIGURE 3. Preoperative magnetic resonance image in a 42-year-old man presenting with right-sided cervical radiculopathy. Lateral (A) and axial (B) C-spine magnetic resonance image at the level of C6-7 showing a paracentral disk herniation resulting in severe right neuroforaminal stenosis.



showed a collapsed C5-6 disk space and a paracentral disk protrusion at that level, resulting in central canal and right greater than left neuroforaminal stenosis. The patient underwent C5-6 arthroplasty with postoperative improvement in her radiculopathy and myelopathy and good cervical range of motion at the 1-year follow-up, as shown on the flexion-extension x-rays in Figure 6. However, she presented with recurrent C5-6 radiculopathy 3 years postoperatively. Figure 7 shows her subsequent flexion-extension x-rays demonstrating anterior implant migration and resultant restenosis of the C5-6 neural foramina. This patient ultimately required supplemental C5-6 posterior instrumentation with lateral mass screws to reopen the neural foramina and to alleviate her recurrent radiculopathy. In retrospect, the degree of preoperative disk space collapse, shown in Figure 5A, made her a poor candidate for cervical arthroplasty.

INDICATIONS AND CONTRAINDICATIONS FOR CERVICAL ARTHROPLASTY

It would be an erroneous assumption that cervical arthroplasty faces issues similar to the notable challenges that lumbar disk arthroplasty faces. There are significant dissimilarities in indications, patient selection, implant design, surgical approaches, potential complications, and complexity of revision surgery that greatly distinguish the procedures. There is a vast difference in the physiological load experienced by the cervical spine compared with the lumbar spine that affects implant design and wear. Therefore, the selection of candidates for cervical and lumbar arthroplasties differs significantly. Although lumbar arthroplasty is for axial back pain, cervical arthroplasty is for radiculopathy and possibly myelopathy.

The current indication for cervical arthroplasty in the United States is single-level cervical degenerative disease.

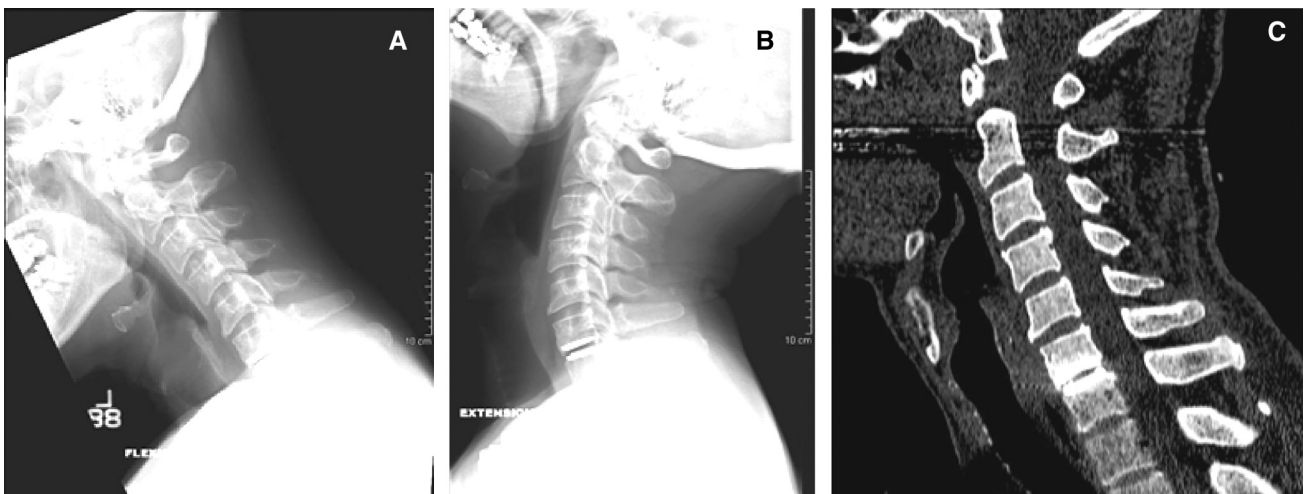


FIGURE 4. Postoperative lateral flexion (A) and extension (B) C-spine x-rays of the same patient as in Figure 3 at the 4-year follow-up demonstrating preservation of dynamic cervical motion. C, postoperative C-spine computed tomography at the 4-year follow-up showing lack of osseous fusion.

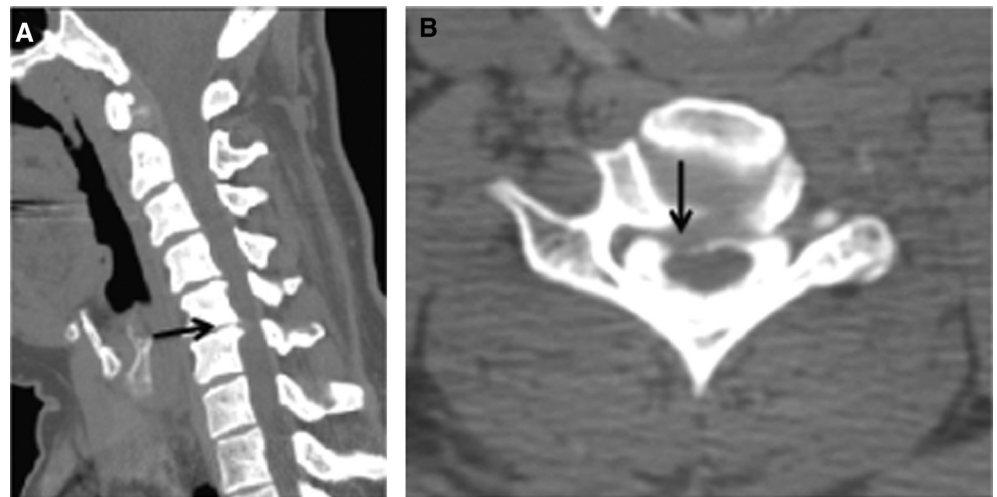


FIGURE 5. Preoperative computed tomography myelogram in a 39-year-old woman presenting with cervical radiculopathy and myelopathy. Lateral (A) and axial (B) C-spine computed tomographic myelogram at the level of C5-6 showing a para-central disk protrusion resulting in significant central canal and right greater than left neuroforaminal stenosis.

However, outcomes for multilevel procedures are reported.¹⁹ Investigational device exemption studies in the United States for 2-level cervical disk arthroplasties are currently underway. For single-level cervical disk involvement, there should be signs and symptoms of neurologic compression. These measures are usually expressed by neck and arm pain visual analog scores, Neck Disability Index, and the accurate recording of motor, sensory, and reflex function. There is some evidence that cervical disk arthroplasty is an acceptable treatment for cervical myelopathy when the cord compression is anterior and exists at the level of the disk space.²⁰ The results are not proven when the anterior compressive pathology exists behind the vertebral body such as in ossification of the posterior longitudinal ligament. However, it must be kept in mind

that the pathology should be anterior (not circumferential) and that there should not be a dynamic contribution to the myelopathy. Motion preservation in the face of dynamic instability would be misguided. The success of cervical disk arthroplasty solely for axial neck pain is unclear. However, it could clearly be problematic if segmental motion were preserved in the face of axial neck pain resulting from significant facet arthropathy. Arthrodesis would be the best choice for this indication.

Although advancing age is not, per se, a contraindication to cervical disk arthroplasty, there is little doubt that many contraindications become more prominent in an aging population. Facet arthropathy, disk space collapse, segmental instability, kyphotic deformity, and osteoporosis are

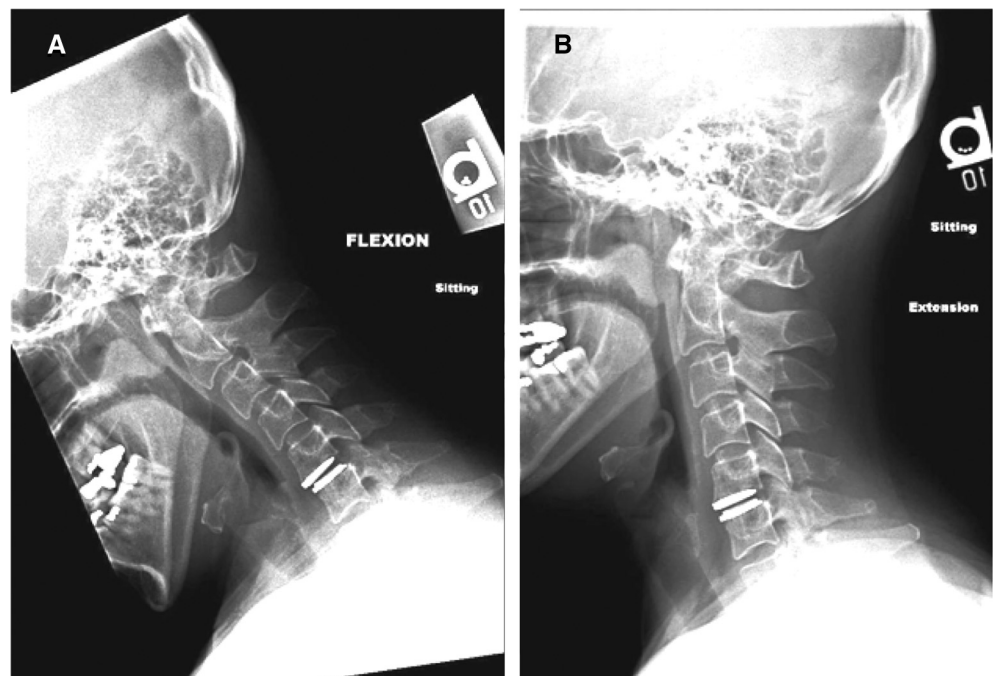


FIGURE 6. Postoperative lateral flexion (A) and extension (B) C-spine x-rays of the same patient as in Figure 5 at the 1-year follow-up demonstrating good preservation of cervical motion.

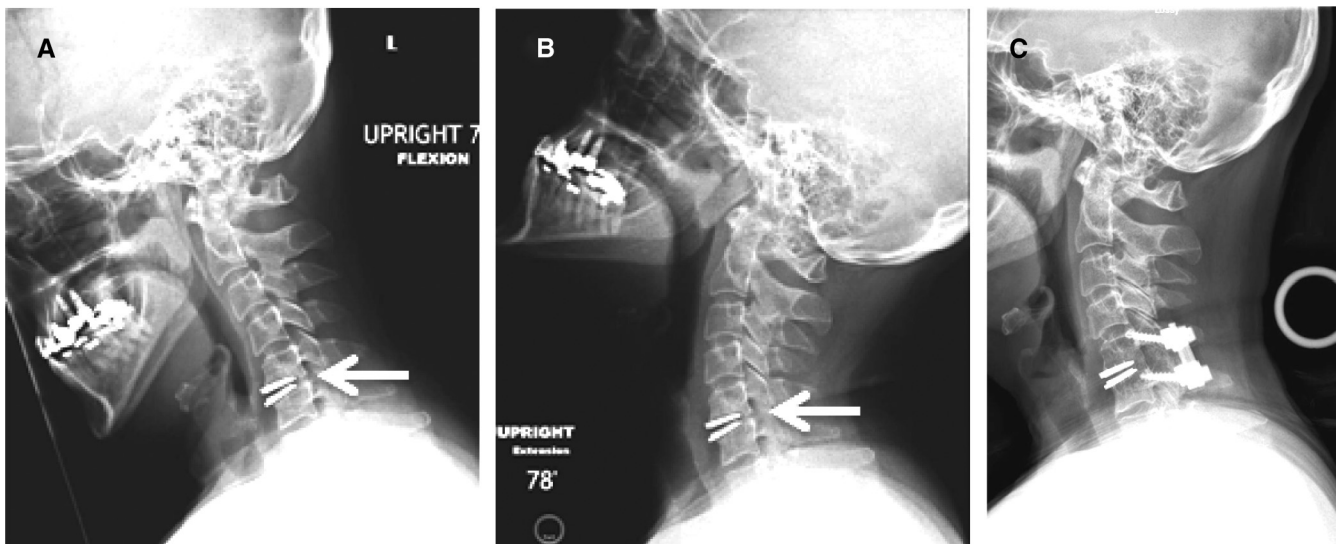


FIGURE 7. The same patient as in Figure 5 re-presented at 3-year follow-up with recurrent cervical radiculopathy. Lateral flexion (A) and extension (B) C-spine x-rays showed anterior migration of the graft resulting in posterior disk space collapse and recurrent neuroforaminal stenosis. C, a C5-6 posterior instrumented fusion with lateral mass screws was performed to reopen the neural foramina at that level.

more prevalent in older patients. We recommend a minimal disk height of 3 mm for successful cervical disk arthroplasty. Excessive disk space collapse can prevent appropriate implant sizing. Forcing an implant into a narrow disk space can lead to poor implant performance and over-distraction (ie, “overstuffing”) of the disk space and facet joints, which can actually increase axial neck pain. With progressive disk space collapse, segmental motion will decline and osteophyte formation will increase. It is critical to recognize that once segmental motion is lost as a result of a combination of disk space collapse, osteophyte formation, and facet arthropathy, it cannot be restored effectively. The concept of cervical disk arthroplasty is for motion preservation and not motion re-creation. Thus, a full series of dynamic plain cervical x-rays is an important component of the presurgical evaluation. The preoperative cervical films with dynamic views also provide an opportunity to assess for segmental instability and kyphotic deformity. Currently, disk replacement devices should not be used to correct significant cervical sagittal imbalance. We define segmental instability as > 3.5 mm sagittal plane translation on dynamic imaging. We denote kyphotic deformity when there is $\geq 15^\circ$ sagittal angulation.

Osteoporosis is a contraindication for cervical disk arthroplasty. Osteoporosis can both affect the potential for subsidence of the implant and increase the chance of device displacement if the bone surrounding the device is weakened. Other conditions that can affect spinal stability or bone quality are also contraindications and include trauma, infection, and neoplasm. Patients who have had previous posterior decompressive laminectomies likely should not be considered for arthroplasty, although previous posterolateral foraminotomy can be acceptable if other selection criteria are fulfilled.

CERVICAL ARTHROPLASTY VS ARTHRODESIS

The following are not meant to be guidelines but rather recommendations regarding which patients are most likely to benefit from arthroplasty vs arthrodesis (Table). We recommend considering cervical disk arthroplasty in patients with single-level disease, primarily anterior or disk-related pathology, preserved cervical range of motion, no significant facet arthropathy, and normal sagittal alignment. In contrast, we recommend cervical arthrodesis for multilevel disease, combined anterior and posterior disease, lack of preoperative segmental motion, collapsed disk space, segmental ankylosis, osteoporosis, significant kyphosis, segmental instability, tumor, trauma, and infection.

It is important to note that simple technical errors are as likely to result in poor outcomes as poor patient selection for

TABLE. Selection Criteria for Anterior Cervical Surgery

Patient Selection	
Consider Arthroplasty	Consider Fusion
Single-level disease	Multilevel disease
Primarily anterior or disk-related pathology	Combination of anterior and posterior pathology
Preserved segmental motion	Loss of segmental motion
Preserved disk space height	Collapsed disk space
No significant facet arthropathy	Segmental ankylosis
Normal sagittal alignment	Osteoporosis
	Significant kyphosis
	Segmental instability
	Tumor, trauma, infection
	Previous decompressive laminectomies

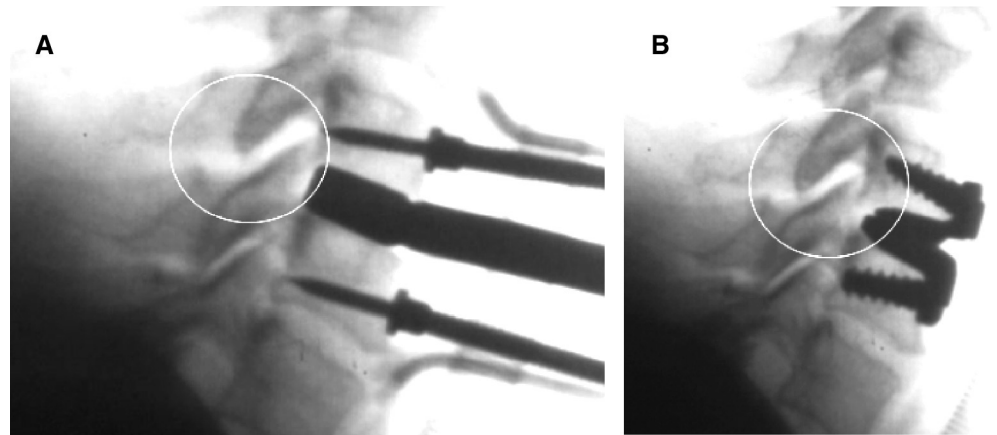


FIGURE 8. Lateral C-spine x-ray in a case of intradiskal overdistraction resulting in overdistraction of the facets before (A) and after (B) implant placement.

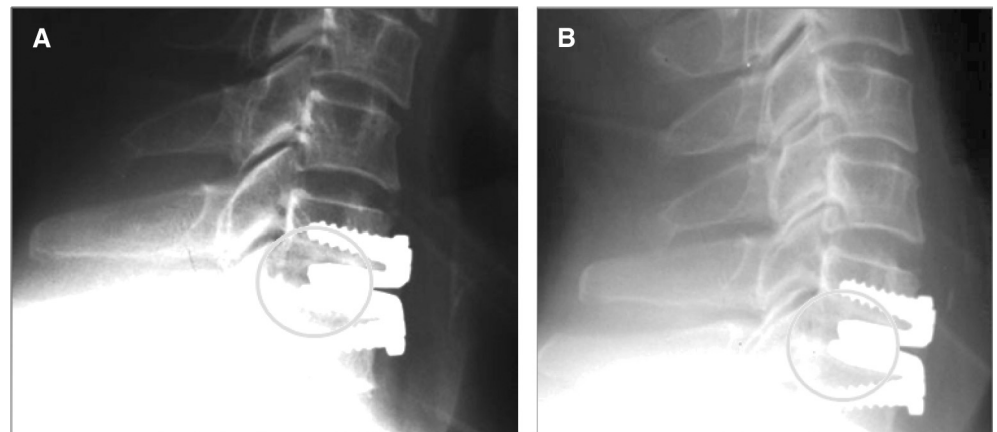


FIGURE 9. Lateral flexion (A) and extension (B) x-rays demonstrating restricted cervical range of motion in a patient in which the implant did not cover the posterior endplate.

cervical arthroplasty procedures. One frequent technical error mentioned previously is overstuffing or intradiskal overdistraction, as shown in Figure 8. This results in overdistraction of the facets, which can cause axial neck pain and

referred intrascapular pain. Another common technical pitfall is using an implant that does not provide adequate geographic coverage of the endplates, as shown in Figure 9. Inadequate coverage of the posterior endplate results in posterior osteophyte

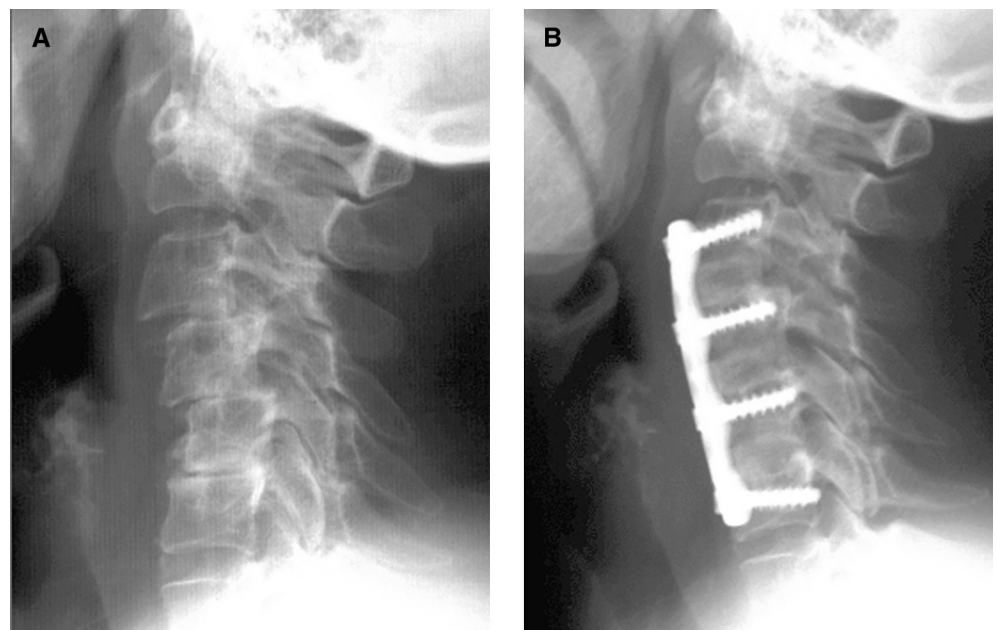


FIGURE 10. A, upright lateral C-spine x-ray showing loss of anterior column support in this patient who presented with cervical myelopathy. B, anterior column support was restored with a 3-level C3-6 cervical arthrodesis.

reformation, encourages heterotopic ossification, and causes poor implant performance, all of which ultimately result in restricted cervical range of motion.

Technical errors and poor patient selection are the 2 most common causes of poor outcomes after cervical arthroplasty. Cervical arthrodesis, rather than arthroplasty, should be used to treat loss of anterior column support (Figure 10). Patients with circumferential cervical stenosis in the absence of cervical lordosis will also be unlikely to benefit from arthroplasty. Additionally, it is important to note that cervical myelopathy can have both a static and a dynamic component. Arthroplasty may successfully treat cervical myelopathy, but the patients must be chosen very carefully. Until more literature is available, the decision for arthroplasty vs arthrodesis for the treatment of cervical degenerative disease will vary, depending on the surgeon's individual experience and patient-specific characteristics and concerns.

CONCLUSION

In the last decade, cervical disk arthroplasty has emerged as a promising alternative to cervical arthrodesis for the treatment of symptomatic cervical degenerative disk disease. However, we do not expect cervical arthroplasty to supplant all of the current treatments for cervical myelopathy and radiculopathy, including anterior cervical arthrodesis and posterior cervical decompression with or without arthrodesis. Additionally, posterior cervical foraminotomy and microdiscectomy will remain successful operations for posterolateral cervical disks. At this time, significant prospective data exist only for single-level cervical arthroplasty in the United States, but the literature for multilevel cervical arthroplasty continues to evolve.

Disclosure

The authors have no personal financial or institutional interest in any of the drugs, materials, or devices described in this article.

REFERENCES

1. Cloward RB. The anterior approach for removal of ruptured cervical disks. *J Neurosurg*. 1958;15(6):602-617.
2. Smith GW, Robinson RA. The treatment of certain cervical-spine disorders by anterior removal of the intervertebral disc and interbody fusion. *J Bone Joint Surg Am*. 1958;40-A(3):607-624.
3. Irwin ZN, Hilibrand A, Gustavel M, et al. Variation in surgical decision making for degenerative spinal disorders, part II: cervical spine. *Spine (Phila Pa 1976)*. 2005;30(19):2214-2219.
4. Boakye M, Mummaneni PV, Garrett M, Rodts G, Haid R. Anterior cervical discectomy and fusion involving a polyetheretherketone spacer and bone morphogenetic protein. *J Neurosurg Spine*. 2005;2(5):521-525.
5. Matsunaga S, Kabayama S, Yamamoto T, Yone K, Sakou T, Nakanishi K. Strain on intervertebral discs after anterior cervical decompression and fusion. *Spine (Phila Pa 1976)*. 1999;24(7):670-675.
6. Goffin J, van Loon J, Van Calenbergh F, Plets C. Long-term results after anterior cervical fusion and osteosynthetic stabilization for fractures and/or dislocations of the cervical spine. *J Spinal Disord*. 1995;8(6):500-508; discussion 499.
7. Hilibrand AS, Carlson GD, Palumbo MA, Jones PK, Bohlman HH. Radiculopathy and myelopathy at segments adjacent to the site of a previous anterior cervical arthrodesis. *J Bone Joint Surg Am*. 1999;81(4):519-528.
8. Reitz H, Joubert MJ. Intractable headache and cervico-brachialgia treated by complete replacement of cervical intervertebral discs with a metal prosthesis. *S Afr Med J*. 1964;38:881-884.
9. Fernström U. Arthroplasty with intercorporeal endoprosthesis in herniated disc and in painful disc. *Acta Chir Scand Suppl*. 1966;357:154-159.
10. Cummins BH, Robertson JT, Gill SS. Surgical experience with an implanted artificial cervical joint. *J Neurosurg*. 1998;88(6):943-948.
11. Cepoiu-Martin M, Faris P, Lorenzetti D, Prefontaine E, Noseworthy T, Sutherland L. Artificial cervical disc arthroplasty: a systematic review. *Spine (Phila Pa 1976)*. 2011;36(25):E1623-E1633.
12. Mummaneni PV, Burkus JK, Haid RW, Traynelis VC, Zdeblick TA. Clinical and radiographic analysis of cervical disc arthroplasty compared with allograft fusion: a randomized controlled clinical trial. *J Neurosurg Spine*. 2007;6(3):198-209.
13. Murrey D, Janssen M, Delamarter R, et al. Results of the prospective, randomized, controlled multicenter Food and Drug Administration investigational device exemption study of the ProDisc-C total disc replacement versus anterior discectomy and fusion for the treatment of 1-level symptomatic cervical disc disease. *Spine J*. 2009;9(4):275-286.
14. Nabhan A, Ahlhelm F, Pitzen T, et al. Disc replacement using Pro-Disc C versus fusion: a prospective randomised and controlled radiographic and clinical study. *Eur Spine J*. 2007;16(3):423-430.
15. Sasso RC, Smucker JD, Hacker RJ, Heller JG. Clinical outcomes of BRYAN cervical disc arthroplasty: a prospective, randomized, controlled, multicenter trial with 24-month follow-up. *J Spinal Disord Tech*. 2007;20(7):481-491.
16. Pimenta L, McAfee PC, Cappuccino A, Bellera FP, Link HD. Clinical experience with the new artificial cervical PCM (Cervitech) disc. *Spine J*. 2004;4(6 suppl):315S-321S.
17. Pimenta L, McAfee PC, Cappuccino A, Cunningham BW, Diaz R, Coutinho E. Superiority of multilevel cervical arthroplasty outcomes versus single-level outcomes: 229 consecutive PCM prostheses. *Spine (Phila Pa 1976)*. 2007;32(12):1337-1344.
18. Nesterenko SO, Riley LH 3rd, Skolasky RL. Anterior cervical discectomy and fusion versus cervical disc arthroplasty: current state and trends in treatment for cervical disc pathology. *Spine (Phila Pa 1976)*. 2012;37(17):1470-1474.
19. Cardoso MJ, Rosner MK. Multilevel cervical arthroplasty with artificial disc replacement. *Neurosurg Focus*. 2010;28(5):E19.
20. Riew KD, Buchowski JM, Sasso R, Zdeblick T, Metcalf NH, Anderson PA. Cervical disc arthroplasty compared with arthrodesis for the treatment of myelopathy. *J Bone Joint Surg Am*. 2008;90(11):2354-2364.