

## Spinal Reconstruction: Quo Vadis?

Jeffrey J. Laurent, M.D., Erica F. Bisson, M.D., and Mark N. Hadley, M.D., F.A.C.S.

Spinal surgery has evolved from early Egyptian times to the present through generations of new concepts, designs, procedures, and technology. In 1862, Edwin Smith discovered the works of Imhotep, Vizer of Djoser, who recorded his treatment of spinal cord injury, as well as spinal dislocation and subluxation, around 2000 B.C.<sup>11,20</sup> In 1882, William F. Wilkins described and performed the first spinal stabilization procedure in a neonate with T12–L1 dislocation.<sup>38</sup> In the years that followed, several individuals began to develop instrumentation systems to help accomplish the goal of operative spinal stabilization. Dr. Berthold Hadra first described the use of wire and the technique of securing spinous processes together in the treatment of a cervical fracture.<sup>38</sup> In 1909, Fritz Lange described the use of steel rods or celluloid bars secured to spinous processes with either wire or silk to help stabilize the spine.<sup>6,7,53</sup>

The idea of onlay bone to accomplish fusion was introduced in 1911 by Fred Albee.<sup>1</sup> He harvested thin strips of tibia and placed them into the base of splint spinous processes. Hibbs decorticated the lamina and placed overlapping autogenous strips over the decorticated dorsal surfaces to facilitate fusion.<sup>6,7,47</sup>

After the advent of dorsal onlay fusion, unique instrumentation concepts were advanced. In the 1940s, Don King<sup>51</sup> reported the use of facet screws for spinal stabilization. The use of the pedicle as a fixation point was initially described by H.H. Boucher of Vancouver in 1959.<sup>10</sup> However, it was Harrington and Tullos who simultaneously described pedicle spinal fixation using screws in conjunction with hooks linked to steel rods to achieve spinal stabilization.<sup>6,7,42,43</sup>

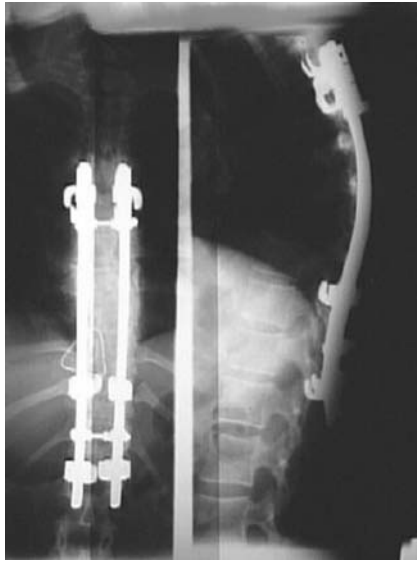
Harrington's system was developed for the treatment of spinal deformities that developed as a sequela to poliomyelitis. Initially, Harrington used facet screws to achieve spinal stability. Although the immediate correction was satisfactory, his early constructs subsequently failed.<sup>41</sup> This led to system modification, akin to present day systems, of a threaded rod and hook construct (*Fig. 25.1*). It became apparent over time that using Dr. Harrington's hook-rod construct without bone grafting had its limitations. This form of non-segmental

instrumentation without attempted bony fusion had a high rate of hook and rod failure with recurrence of deformity.

Segmental spinal stabilization, which capitalizes on load sharing by multiple vertebral levels, thereby enhancing construct durability, was subsequently developed. The first of these systems was the Luque instrumentation system utilizing segmental sublaminar wires.<sup>6,7,20,59,60</sup>

Despite the improved success rates of hook-rod with sublaminar wire constructs, there was still sufficient hardware failure to drive the search for more appropriate and substantial spinal fixation devices and techniques. Although Harrington attempted pedicular fixation, he had difficulty with screw/rod fixation and therefore abandoned the idea.<sup>44</sup> It is Roy-Camille who is credited with the advent of contemporary techniques to use the pedicle as a fixation point for spinal implants.<sup>77</sup> Rigid pedicle fixation into the vertebral body affords three-column spinal fixation.<sup>23</sup> Therefore, fewer spinal segments are required for incorporation within a spinal fusion construct to achieve stabilization. For these reasons, pedicle screw segmental fixation with a screw-rod construct affords significant advantages over much longer, non-segmental spinal stabilization techniques and instrumentation systems.

Although dorsal onlay posterolateral fusion of the lumbar spine gained popularity, fusion rates were suboptimal. With realization of the biomechanical principles of the human spine, rather than just its structural features, it became understood that the use of interbody bone grafting would lead to restoration of disc height, the removal of the disc as a potential pain generator, and that vertebral replacement could be accomplished with a noncompressible structural bone graft.<sup>6,7</sup> The first description of a posterior interbody fusion (PLIF) was published in 1953 in the *Journal of Neurosurgery*.<sup>18</sup> Since that time, PLIF techniques have gained widespread acceptance, and lumbar fusion success rates have improved compared with dorsal lumbar onlay fusion procedures. Many surgeons consider PLIF to be the procedure of choice for intervertebral bony stabilization of the lumbar spine. This procedure too has limitations, including the need for thecal sac and nerve root retraction, potential cerebrospinal fluid (CSF) leak, dysesthetic nerve root pain syndromes, and epidural fibrosis.<sup>63</sup>



**FIGURE 25.1** An example of a non-segmental fusion technique (Harrington Rod construct). These constructs were mainstays of early spinal instrumentation.

Anterior lumbar interbody fusion, first reported by Burns in 1933, was introduced as an effective spinal fusion alternative to onlay posterolateral fusion and PLIF.<sup>13</sup> The specific advantages of an anterior interbody approach include direct intervertebral access for bony reconstruction of the anterior spinal column, the ability to avoid dorsal paraspinous muscle dissection and trauma, and the ability to restore interbody height and therefore, indirectly decompress the spinal canal and the intervertebral foramina. This approach also has drawbacks. It may be complicated by the need for significant retraction of the iliac vessels (thereby increasing the risk of deep venous thrombosis), retrograde ejaculation, and postoperative muscular atony.<sup>63</sup> More recently, with the advent of new technology and biogenetic engineering, fusion rates of greater than 94% have been reported for patients with axial instability due to degenerative disc disease undergoing ALIF with titanium cages and/or polyethylene ketone (PEEK)-engineered cages filled with rhBMP.<sup>12</sup>

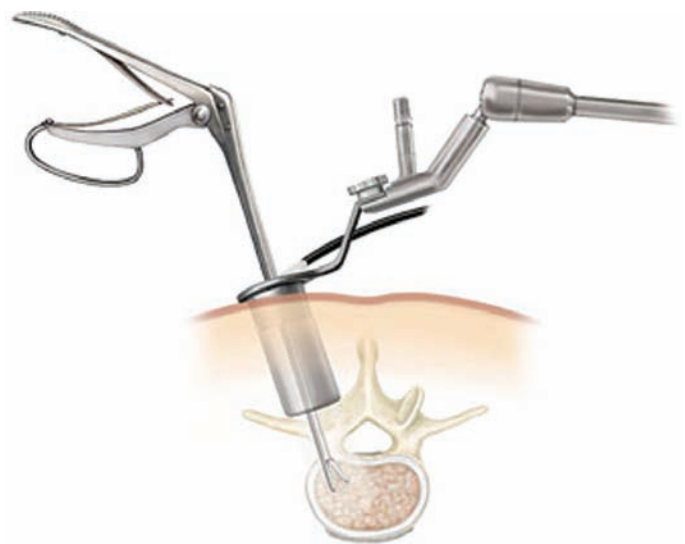
Recently, there have been modifications to the ALIF and PLIF procedures, incorporating the use of contemporary laparoscopy and percutaneous techniques. Transforaminal lumbar interbody fusion, and the “VLIF,” or versatile TLIF techniques have been introduced. TLIF avoids some of the potential complications of ALIF and PLIF by avoiding the need for a two-stage operative procedure, an abdominal approach (ALIF), and, importantly, bilateral nerve root retraction (PLIF). The VLIF has added to the surgeon’s abilities to tailor his/her operative approach using minimally invasive techniques depending on individual patient pathology (i.e., mini-open technique with the use of tube retractor systems

and/or the percutaneous placement of pedicle screws) (Fig. 25.2).<sup>63</sup>

With the advent of newer surgical exposure techniques, novel technology, and new materials for spinal fusion, we have seen an improvement in lumbar fusion success rates. This (potential) increase in fusion success, however, has been coupled with increasing technical difficulty. Finally, investigators have yet to translate improved fusion success rates with improved functional outcomes.<sup>72</sup> It is imperative, therefore, that we continue to search for a more simplistic, biomechanically advantageous, and perhaps more “natural” way to approach spinal stabilization and reconstruction.

As spinal fusion and reconstruction procedures have become widely recognized in the treatment of spinal disorders, the operative techniques and materials used to achieve successful fusion have evolved as well. Although these technical and material advancements have aided overall fusion rates, non-union rates as high as 35% are still being reported.<sup>24,83</sup> In addition, the increased technical difficulty of the newer procedures and techniques has resulted in a commensurate increase of operative complications and patient morbidity.<sup>71</sup> Are there other methods that might be employed to improve spinal fusion success rates without continuing to add to the technical difficulty and/or invasiveness of the procedures themselves?

As we have summarized, innovations in procedure, design, and instrumentation have been relentless and progressive over time. In the past 15 years, however, we have seen an explosion in the applications and advancements in the fields of molecular biology and gene therapy. Researchers



**FIGURE 25.2** Minimally invasive procedures using tube retractor systems are allowing surgeons to perform equally effective procedures, both for decompression and fusion, while causing less trauma to paraspinous muscle tissue.

and clinicians have begun to apply these tools to the treatment of spinal disorders. Many of these techniques have been adapted to enhance the potential for successful spinal fusion. Much of the focus in this area has focused on the use of osteoinductive materials to supplement and enhance the natural bone healing and fusion process. Osteoinductive materials work by enhancing bone-forming activity at the site of desired fusion. Currently, a variety of products are available for this purpose. They tend to fall into two main categories: osteobiologics and osteogenetics.<sup>73</sup> The first category includes the various types of demineralized bone matrix (DBM) or osteobiological materials. These products contain demineralized bone that has been processed in various ways to deliver high concentrations of viable bone growth factors and inducers to the site of potential fusion.<sup>15,58</sup> Grafton®, DBX®, and Osetofil® are examples of this type of fusion adjunct. These products are both osteoconductive and osteoinductive. Although all of these products consist of demineralized bone with viable BMP (initiators), the means by which the demineralized bone is processed has an effect on the activity of the BMP contained therein.<sup>69</sup> This helps to explain how different DBM products can have different biological osteoinductive activity. A recent comparative study, for example, revealed increased bone deposition with the use of Grafton® compared with other DBM products in an animal spinal fusion model. Although Grafton seems to offer increased biological activity compared with the other DBM products tested, the numbers treated in the study were small and the results did not reach statistical significance at all assessment intervals.<sup>69</sup> More work is required in this area. Nonetheless, the concept is clear: the use of “active” osteobiological bone fusion products, rather than simple inert osteoconductive agents (coral, hydroxyapatite, inactive DBMs), has important potential to enhance bone healing and potential fusion at the site of spinal reconstruction.

Osteogenetic materials are genetically engineered proteins and growth factors that are administered at the site of fusion.<sup>73</sup> Infuse® (Rh-BMP-2) and OP-1® (BMP-7) are two available and tested osteogenetic products currently available for limited clinical use. These products consist of pure genetically engineered bone growth factors (BMPs) and have proven efficacy in promoting bone fusion and healing in multiple human and animal spinal and long bone fusion models.<sup>2-5,12,16,35,46,54,65,66</sup> In addition, it has been shown that the osteoinductive effects of these purified BMPs is superior to the osteoinductive effects of demineralized bone matrix in any of its present formations.<sup>66</sup>

It is unclear what significance these findings bring to clinical practice. Although laboratory studies reveal slight differences in efficacy, in actual practice, all of these “active” osteobiological and osteogenetic materials seem to represent reasonable adjuncts to enhance bone fusion after spinal reconstruction. The osteogenetic products (Infuse and OP-1),

however, cost more than five times as much as the DBM products. It is doubtful that this increased expense is justified based on fusion success rates and, more specifically, on clinical outcomes.

As the quest for improved fusion rates has accelerated, so too has the search amplified for other viable adjuncts to bone healing. Electrical stimulation as an aid to bone healing dates to the 1840s when Hartshorne successfully treated a patient with a tibial nonunion with “shocks of electric fluid” for 6 weeks.<sup>45</sup> The use of electricity or an electrical field to promote bone fusion was abandoned for nearly a century after its discovery. It was repopularized in 1957 by Fukada and Yasuda,<sup>34</sup> who reported the formation of new bone in the vicinity of a cathode placed in a rabbit femur. The 1970s saw a surge of interest in electrical stimulation for its bone healing affects. In 1974, Dwyer and Wickham<sup>28</sup> reported the first clinical study on the efficacy of electrical stimulation following lumbar spinal fusion.

Currently, there are three main modalities used to deliver electrical stimulation to a spinal fusion mass: direct current electric stimulation (DCES), pulsed electromagnetic fields (PEMF), and capacitive coupled electrical stimulation.<sup>74</sup>

DCES, an implantable stimulator, has been demonstrated to augment both anterior and posterior spinal fusion in several large multicenter studies. Kane<sup>49</sup> reported a 91% fusion rate in patients with pseudarthrosis treated with DCES. Rogozinski reported a significant improvement in fusion success rates with stimulation used as an adjunct, compared to controls treated similarly but without electrical stimulation (96 versus 85%).<sup>75</sup>

The use of PEMF has been substantiated by several investigators over the past 20 years. In 1985, Simmons reported a 77% fusion rate among patients with anterior interbody pseudarthrosis after attempted posterior interbody fusion with the use of PEMF.<sup>81</sup> In 1990, Mooney<sup>62</sup> credited a fusion rate of 92.2% to postoperative PEMFs use after either ALIF or PLIF. Additionally, Linovitz et al.<sup>57</sup> presented their results of a randomized controlled study examining the effects of PEMF in patients treated with non-instrumented lumbar fusion. They found a fusion success rate of 64% with use of PEMF, compared with a 43% fusion success in control patients.

Capacitive coupling devices have also been used with success. Goodwin et al.<sup>36</sup> randomized patients to a trial of capacitive coupled electrical stimulation after lumbar fusion. Patients were treated with anterior interbody, posterior interbody, or posterolateral fusion with or without stimulation. The device was worn 24 hours a day for 9 months, or until bone healing occurred based on radiographic images. The authors reported favorable results for patients treated with electrical stimulation, (84.7% fusion rate) compared with control group patients (64.9% fusion rate).

Significant positive results have been reported with all three types of electrical stimulation after lumbar fusion procedures.<sup>74</sup> At present, electrical stimulation as an aid to bone fusion seems to be best utilized in patients at high risk for pseudarthrosis (smokers, diabetics, those with endocrine or metabolic disorders, advanced arthritis, other systemic illness), and among those undergoing reoperation for failed fusion. Questions remain as to the efficacy of electrical stimulation after routine cervical, thoracic, or lumbar fusion procedures among healthy patients at low risk for pseudarthrosis.

Another emerging trend in spinal surgery is the use of minimally invasive operative techniques and devices. The rationale behind these techniques is that less dissection and manipulation of paraspinal tissues and musculature typically leads to less postoperative pain and shorter hospital stays. Currently, experience with these techniques is expanding in spinal surgery for indications ranging from simple discectomy to the treatment of stenosis to multi-level fusion procedures, to the surgical treatment of traumatic spinal injuries and the resection of spinal tumors.<sup>25–29,31–33,39,40,76,84</sup>

Percutaneous vertebroplasty has been explored for years as an effective palliative treatment for painful spinal vertebral compression fractures.<sup>27,29</sup> More recently, this technique has been extended to more complex pathological processes, such as the treatment of traumatic burst fractures and pathological (malignant) vertebral fractures (*Fig. 25.3*)<sup>82,92</sup> Kyphoplasty is a related treatment that uses an inflatable balloon in an attempt to restore vertebral body height and contain the injected vertebral cement. Although advocates contend that kyphoplasty offers a biomechanical advantage over conventional vertebroplasty techniques, a prospective, randomized trial comparing the two techniques has not been performed.<sup>27</sup>

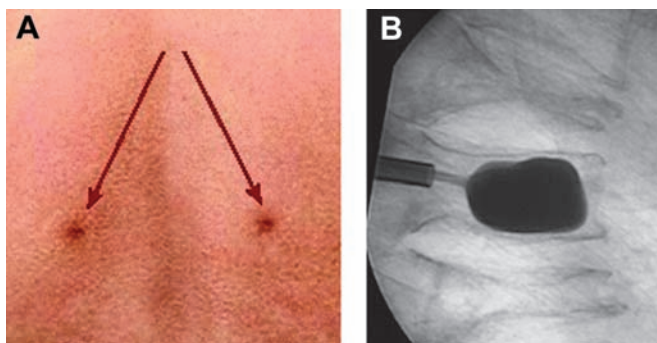
Dickman et al. have reported good results using thoracoscopic techniques to treat conditions such as thoracic disc herniation, neurogenic tumors, and traumatic thoracic frac-

ture injuries.<sup>25,26,39,40,48,76</sup> These less invasive endoscopic techniques represent a large departure from existing open (conventional) operative procedures used to treat thoracic spinal conditions in which thoracotomy or sternotomy are typically required.

More recently, minimally invasive techniques have been used in the treatment of cervical and lumbar spinal pathology. Cervical and lumbar discectomy (with and without foraminotomy) have been reported with the use of tube retractor systems and the operating microscope with good preliminary results.<sup>31–33,50,79</sup> Both anterior and posterior interbody fusion procedures (ALIF, PLIF, and TLIF), as well as posterolateral lumbar fusion procedures, have been performed using tube retractor systems. Internal fixation devices have been inserted percutaneously with image guidance systems. Although long-term clinical follow-up data is not yet available for large numbers of these procedures, preliminary results suggest that, with proper patient selection and strict adherence to specific techniques, outcomes are favorable compared with those achieved via open procedures. Truly minimally invasive procedures seem to offer both shorter hospital stays and less postoperative pain and morbidity.<sup>31–33,50</sup> That having been said, the technical aspects of these procedures is challenging and long segment fusion and internal fixation procedures are not currently feasible with existing devices and techniques.

Until recently, much of the attention on the treatment of spinal disorders has been focused on creating better ways to achieve rigid fixation of the injured or diseased human spinal column. Whether with the use of more rigid segmental internal fixation systems, the use of osteoinductive materials or electrical stimulation to achieve better fusion rates, or the use of less invasive methods to improve patient outcomes and satisfaction, spinal reconstruction, internal fixation, and fusion has been the mainstay of treatment for many spinal pathological conditions. It is important to note, however, that rigid internal fixation and fusion between two or more vertebral segments is not the ideal circumstance for the human spine. Paradoxically, the use of fusion in the treatment of spinal pathology is a departure from the natural state of healthy spinal biomechanics and kinetics. Multi-segmental spinal fixation and fusion can substantially limit patient motion and activity. Even short segment spinal fusion can contribute to additional, accelerated degeneration of the spine, often at adjacent levels.<sup>19,21,56</sup> This brings us to the discussion of one of the most contemporary and controversial arenas within spinal reconstructive surgery: motion preservation spinal reconstruction.

Historically, pain generation from a diseased joint (hip, knee, shoulder) has been linked to excessive mobility within the degenerative joint and the inability of the joint to provide structural and functional support (instability). It has become common practice that restricting motion of a diseased and unstable joint will suppress pain. Consequently, spinal fusion



**FIGURE 25.3** Balloon kyphoplasty (*B*) and vertebroplasty techniques allow the surgeon to percutaneously (*A*) stabilize fractures without extensive anterolateral approaches, which have been required in the past.



has been used to treat disc arthrosis and collapse, spondylolisthesis, and virtually any disorder of spinal segmental motion or instability which contribute to chronic pain. Unfortunately, successful arthrodesis of two or more spinal segments often translates into reduced mobility and restricted function of the entire spine in a majority of patients. Although radiographic fusion rates have improved over time and now exceed 90% for most fusion procedures, the clinical improvement patients experience is typically only moderate, between 60 and 80% for most procedures.<sup>95</sup>

The rationale behind spinal intervertebral disc replacement or arthroplasty is to remove a degenerative dysfunctional disc and replace it with a motion preserving engineered implant. This has the potential for pain relief (removal of the painful herniated and/or degenerative disc), the maintenance of mobility, and the restoration of function. Although perhaps conceptionally ideal, the clinical success with spinal arthroplasty, both cervical and lumbar, remains to be proven. Investigators face many unique challenges in the development of an ideal disc replacement device. These obstacles include, but are not limited to:

- an incomplete understanding of the degenerative disc as a pain generator,
- intervertebral disc function and mobility (including the ability to compress and absorb loads) are difficult to reproduce,
- intervertebral loads and strains differ significantly in the human spine and within different regions of the human spinal column and are different among humans,
- intervertebral implants are not similar to or as simple as other successful joint implants and devices (hips, knees), and
- the complex surgical anatomy of a functional human spinal segment.<sup>85</sup>

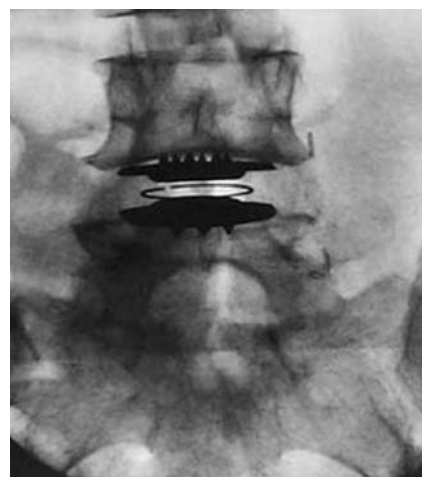Despite these obstacles, there have been sequential developments in the arena of intervertebral disc replacement over the past 50 years. Early implant iterations include those of Nachemson,<sup>64</sup> who injected self-hardening silicone rubber into cadaveric discs in an attempt to achieve relative restoration of functional disc properties. van Steenbrugge<sup>84</sup> devised an intervertebral implant consisting of two cushions. Substad<sup>89</sup> proposed several designs approximating the shape and structure of an intervertebral disc made of a reinforced elastic polymer.

Most of these early disc replacement strategies did not withstand the stresses and loads of the upright human spine. As spinal biomechanics and kinetics have become better understood, there has been an explosion of concepts and devices aimed at maintaining the viscoelastic and load sharing properties of the intervertebral disc, the preservation of interspace motion, and the maintenance of normal function. Prototypes have been developed for both the cervical and lumbar spinal segments. A

number of devices are currently being evaluated in investigational trials. Several deserve specific mention here.

The Charite intervertebral disc is the most widely used lumbar interbody implant currently available, with more than 7000 implants worldwide (*Fig. 25.4*).<sup>14,17</sup> It has a biconvex, ultrahigh molecular weight PE spacer that acts as a mobile core within endplates made of a cobalt-chromium alloy. Both Cinotti<sup>17</sup> and Lemaire<sup>55</sup> have implanted this device in large series of patients and have reported good to excellent results in 69 and 79%, respectively, of recipients at 4- and 5-year follow up evaluations. A prospective randomized trial has recently been completed comparing the Charite artificial disc to anterior lumbar interbody fusion with a BAK cage with promising results. Postoperative clinical outcomes were significantly improved in both surgical treatment groups compared with control group patients. Although there was no difference in functional outcome between artificial disc and ALIF patient groups, patient satisfaction ratings, the length of hospital stay and the rate of reoperation were significantly better among patients receiving the Charite device.<sup>9</sup>

The Pro-Disc intervertebral implant is a metal on plastic arthroplasty device with a high molecular weight PE spacer and cobalt-chromium articulating surfaces. It was originally conceived and implanted in the 1990s by Thierry Marnay. Eight to 10-year follow-up data has been reported with good to excellent outcomes in 93% of implanted patients.<sup>87</sup> The Pro-Disc II, a contemporary prototype, is currently being evaluated in a multi-institutional study investigating its safety and efficacy. It is a randomized trial comparing the implant to circumferential spinal fusion for one- and two-level degenerative disc disease of the lumbar spine.<sup>22</sup>



**FIGURE 25.4** Artificial lumbar discs, such as the Charite, offer treatment of discogenic back pain with motion preservation. It remains to be seen whether these techniques will prove more durable and effective than simple fusion in long-term follow-up.

The Maverick arthroplasty device is a metal-on-metal intervertebral prosthesis. It has a fixed posterior center of rotation to better approximate the axis and mechanics of the intervertebral motion segment. It has been designed to cover a larger surface area to maximize end plate coverage and improve stability. A Food and Drug Administration-approved trial initiated in May 2003 is presently in progress comparing single level Maverick arthroplasty to single-level lumbar fusion supplemented with rhBMP2.

The Flexicore arthroplasty device is a ball and socket, metal-on-metal prosthesis. Advantages of this device include that it is a single piece implant, it offers a rotational stop, its end plates are dome-shaped more akin to the natural contour of an intervertebral disc, and there is a tension bearing to prevent separation and potential dislocation of the superior from the inferior end plate. The Flexicore is presently being evaluated in a multi-center clinical trial designed to assess its efficacy in the treatment of single-level lumbar disc degeneration. Control group patients in this trial are treated with 360-degree fusion including posterior instrumentation. Treatment groups will be compared clinically and radiographically with a minimum 2-year follow-up period.<sup>30</sup>

The quest for an ideal intervertebral spinal implant has led to a multitude of innovations, each surpassing the previous technology. New artificial disc devices are being developed, seemingly by the week. This field, while exciting, is still in its infancy. While these devices seem to have promise, not one is without complications and failure. Not one has been proven to withstand the axial load and mechanics of the human spine over time. Not one has been demonstrated to restore normal spinal curvature, alignment, and sagittal balance. Not one has been proven to provide better results than a single-level interspace fusion procedure (cervical and lumbar). Our excitement for these innovative devices must be tempered by definitive science, not fanned by patient demands and uneducated expectations.

In addition to novel technologies for arthroplasty, there have been multiple other attempts at nonrigid, motion preserving spinal fixation. Historically, the concept of dynamic stabilization grew from the idea that intervertebral disc degeneration was a continuum, and if we could interrupt or forestall the degradation process, we might obviate the need for interbody fusion or disc replacement altogether. Therefore, systems of posterior dynamic stabilization have been introduced. Several have been designed either as an alternative to (XSTOP)<sup>96</sup> or as a supplement to lumbar decompression procedures (DIAM).<sup>80</sup> Preliminary reports suggest that their use in select patients results in improved clinical outcomes compared with similar patients managed non-operatively.<sup>78</sup>

More recently, the DYNESYS posterior stabilization system was introduced and is currently under evaluation in clinical trials. This system involves the use of pedicle fixation

with a nonrigid spacer and cord to allow for controlled mobility of the motion segment. Preliminary reports describe improved function and preserved mobility with its use. There may be a definitive patient population who may benefit from motion preserving devices like this one.<sup>78</sup> To date, the efficacy of the DYNESYS dynamic system and its long-term durability remain in question.

We've made great strides and advances in the treatment of human spinal disease over the past six decades. Novel instrumentation systems, innovative adjuncts for bone healing, molecular biology and medical genetics, minimally invasive and "sopic" technologies, and motion preservation spinal reconstruction devices and procedures have advanced our understanding of the multiple integrated complexities of the human spine including its anatomy, mobility and mechanics, load sharing and functional properties, and how they are altered with age, disease, and injury.

This knowledge these lessons provide must now be focused and brought to bear on "stabilization" of the degenerated, injured, or diseased human spine. Our future is not in immobilizing, instrumenting, and fusing the dynamic human spine, or in the creation of a rigid, immobile, locked-down dysfunctional patient. Our future is in the restoration of functional performance through mobility preservation. Spinal surgeons of the next two to three decades will offer a new definition of "functional neurosurgery. Functional neurosurgery will become the routine, rather than the exception, for practicing spinal surgeons. No, we won't be placing leads and stimulators to control tremor akin to our intracranial surgeon counterparts. We will operate to restore and maintain the functional skills of the spine and limbs and the locomotive abilities of our patients. Functional (spinal) neurosurgery is a field waiting to explode.

Disease-specific approaches to this new "functional neurosurgery" will allow us to predict and direct the future of spinal stabilization.

## Disc Disease and Injury

Minimal access surgery and molecular biology afford us the potential to provide surgical excision of disc herniation or injury and the delivery of trophic factors to the remaining viable disc or tissue-engineered intervertebral discs to the interspace. We don't see mechanical disc replacement in our ultimate future as functional neurosurgeons. Mechanical devices wear and fail. Failed devices require replacement. Replacement and revision strategies for contemporary spinal arthroplastic implants are fraught with complications and difficulties. The future, as we imagine it, is in restoring the existing disc, whether degenerative (aged, collapsed, desiccated) or injured (herniated).

Investigators are working in this area and their early results are promising. Walsh et al.<sup>93</sup> performed an in vivo study evaluating the effects of growth factor injections into

intervertebral discs in a mouse model of static compression disc degeneration. Disc height was increased after injection of growth differentiation factor-5 (GDF-5) compared with discs in animals injected with saline. Injections of TGF- $\beta$  into degenerative discs in this model was associated with an increase of fibrochondrocytes in the annulus. Using similar techniques, Masuda et al.<sup>61</sup> demonstrated restoration of disc height in a rabbit model of induced disc degeneration. These investigators have observed reversal of disc space narrowing after a single injection of rhBMP7 (OP-1®) into the nucleus pulposus.

Interbody carriers impregnated with growth factors are being considered that would be implanted within the remaining viable disc with the aim of remodeling into a newer, stronger, more viable intervertebral disc (Fig. 25.5). This may have specific merit in cases of disc herniation in which only a portion of the disc has been injured. Microinvasive technology, conceivably wedged to contemporary imaged-guided techniques, would allow precision disc herniation extraction followed by delivery of disc remodeling regenerative agents into the remaining viable disc at the same operative setting.

In vitro techniques are being developed to generate tissue-engineered intervertebral discs with the intention of implanting them on biodegradable scaffolds within a surgically prepared interspace to create a new biologic intervertebral disc. These ideas are being investigated in conjunction with the use of mesenchymal stem cells that have been genetically engineered to produce specific growth factors. These directed cells would then be implanted into desired sites in selected patients, inducing tissue differentiation of the desired type.

### Spinal Trauma and Neoplasia

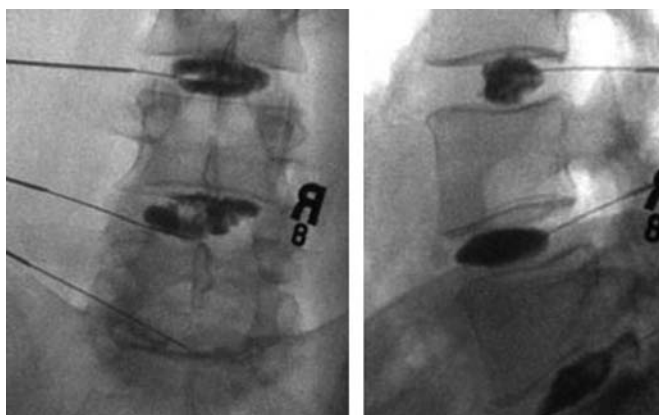
Spinal stabilization after trauma or due to destructive neoplastic processes also present interesting opportunities for

targeted management strategies. Currently, neural decompression and instrumented stabilization and fusion over multiple segments is the standard treatment for traumatic fracture injuries or destructive neoplastic lesions. The methods by which this is achieved in the future will be less invasive and will rely on continuing advancements in gene therapy and molecular biology, image guidance, and minimally invasive techniques. It has already been demonstrated that spinal fusion can be accomplished in animal models with the percutaneous injection of mesenchymal stem cells or inactivated viruses which produce BMPs.<sup>54</sup> Using these techniques in conjunction with endoscopic or laparoscopic decompression procedures followed by precise image-guided short segment fixation may dramatically reduce the need for large open decompression, stabilization, and fusion procedures. In both severely injured trauma patients and those debilitated from systemic cancer, this would translate into less morbidity, shorter operating time, less blood loss from treatment, and would likely allow quicker recovery, rehabilitation and return of function, and potentially, better quality of life. Functional spinal neurosurgeons might simultaneously inject or implant local chemotherapeutic agents or activated anti-tumoral viral agents into the tumor resection cavity in direct treatment of the spinal neoplasm.

### Deformity

Long segment deformity spinal surgery will be refined and reinvented as well. Functional spinal neurosurgeons will no longer perform complex, multi-level, multi-stage internal fixation and fusion procedures. Preoperative computerized three-dimensional animated tomographic analysis will define the specifics of each deformity and will describe the segmental corrections required to correct the deformity and restore sagittal balance. Functional surgeons will use endoscopic, thoracoscopic, and laparoscopic techniques to release and reconstruct. Osteobiological structural devices, with or without the use of osteogenetic materials, will be used as segmental (often unilateral) interbody fusion fixators to functionally rebuild sagittal, coronal, and axial plane deformities. Contemporary external immobilization devices will facilitate motion, preserving stabilization and fusion. Conventional thoracolumbar-sacral rod, screw and hook systems with long segment fusion will ultimately become obsolete.

In summary, the management of spinal diseases and the long held tenets of contemporary spinal stabilization are about to be revolutionized. Conventional procedures are being refined and instrumentation systems are being retooled. We are moving toward a paradigm shift. No longer will spinal reconstruction translate to long-segment, rigid internal fixation and fusion. The concepts of motion preservation stabilization and functional spinal neurosurgery are being advanced. These are exciting times. We must maintain our patient selection and management skills, continue to refine



**FIGURE 25.5** Experimental techniques, such as percutaneous injections of growth factors into a degenerated disc, offer promise for biological rather than mechanical disc replacement.



our surgical techniques, cautiously embrace technological advances based on scientific merit, and integrate multiple new techniques, biologically active materials, devices and technology into our care of patients with spinal disorders. A new era of spinal stabilization is upon us.

## REFERENCES

- Albee FH: Transplantation of a portion of the tibia into the spine for Pott's disease. **JAMA** 57:885–885, 1911.
- Alden TD, Varady P, Kallmes DF, Jane JA Jr, Helm GA: Bone morphogenetic protein gene therapy. **Spine** 27 [Suppl 1]:S87–S93, 2002.
- Alden TD, Beres EJ, Laurent JS, Engh JA, Das S, London SD, Jane JA Jr, Hudson SB, Helm GA: The use of bone morphogenetic protein gene therapy in craniofacial bone repair. **J Craniofac Surg** 11:24–30, 2000.
- Alden TD, Pittman DD, Beres EJ, Hankins GR, Kallmes DF, Wisotsky BM, Kerns KM, Helm GA: Percutaneous spinal fusion using bone morphogenetic protein-2 gene therapy. **J Neurosurg** 90 [Suppl 1]:109–114, 1999.
- Alden TD, Pittman DD, Hankins GR, Beres EJ, Engh JA, Das S, Hudson SB, Kerns KM, Kallmes DF, Helm GA: In vivo endochondral bone formation using bone morphogenetic protein-2 adenoviral vector. **Hum Gene Ther** 10:2245–2253, 1999.
- Benzel EC, Ball PA: History of spinal instrumentation, in Benzel EC (ed): *Spinal Instrumentation*. AANS Publications Committee, American Association of Neurological Surgeons, 1994, pp 3–10.
- Benzel EC: Short-segment fixation of the thoracic and lumbar spine, in Benzel EC (ed): *Spinal Instrumentation*. AANS Publications Committee, American Association of Neurological Surgeons, 1994, pp 111–124.
- Bertagnoli R, Zigler J, Karg A, Voigt S: Complications and strategies for revision surgery in total disc replacement. **Orthop Clin North Am** 36:389–395, 2005.
- Blumenthal S, McAfee PC, Guyer RD, Hochschuler SH, Geisler FH, Holt RT, Garcia R, Regan JJ, Ohnmeiss DD: A prospective, randomized, multicenter Food and Drug Administration investigational device exemptions study of lumbar total disc replacement with the Charite® artificial disc versus lumbar fusion. Part I: Evaluation of clinical outcomes. **Spine** 30:1565–1575, 2005.
- Boucher HH: A method of spinal fusion. **J Bone Joint Surg** 41B:248–259, 1959.
- Breasted JH: *The Edwin Smith surgical papyrus, Vol. 1*. Chicago, University of Chicago, 1930, pp 316–342.
- Burkus JK, Dorchak JD, Sanders DL: Radiographic assessment of interbody fusion using recombinant human bone morphogenetic protein type 2. **Spine** 28:372–377, 2003.
- Burns BH: An operation for spondylolisthesis. **Lancet** 1:1233, 1933.
- Butner-Janž K, Schellnack K, Zippel H: Biomechanics of the SB Charite® lumbar intervertebral disc endoprosthesis. **Int Orthop** 13:173–176, 1989.
- Cammissa FP Jr, Lowery G, Garfin SR, Geisler FH, Klara PM, McGuire RA, Sassard WR, Stubbs H, Block JE: Two-year fusion rate equivalency between Grafton® DBM gel and autograft in posterolateral spine fusion: A prospective controlled trial employing a side-by-side comparison in the same patient. **Spine** 29:660–666, 2004.
- Cheng SL, Lou J, Wright NM, Lai CF, Avioli LV, Riew KD: In vitro and in vivo induction of bone formation using a recombinant adenoviral vector carrying the human BMP-2 gene. **Calcif Tissue Int** 68:87–94, 2001.
- Cinotti G, David T, Postacchini F: Results of the disc prosthesis after a minimum follow-up period of two years. **Spine** 21:995–1000, 1996.
- Cloward RB: The treatment of ruptured lumbar intervertebral discs by vertebral body fusion. **J Neurosurg** 10:154–168, 1953.
- Cole TK, Burkhardt D, Ghosh P, Ryan M, Taylor T: Effects of spinal fusion on the proteoglycans of the canine intervertebral disk. **J Orthop Res** 3:227–291, 1985.
- Cotler JM: Historical events leading to spine surgery, in An HS, Cotler JM (eds.): *Spinal Instrumentation, Second Edition*. Lippincott, Williams and Wilkins, Philadelphia, 1999, ed 2, pp 3–8.
- Dekutoski MB, Schendel MJ, Ogilvie JW, Olsewski JM, Wallace LJ, Lewis JL: Comparison of in vivo and in vitro adjacent segment motion after lumbar fusion. **Spine** 19:1745–1751, 1994.
- Delamarter RB, Bae HW, Pardhan BB: Clinical results of ProDisc-II® lumbar total disc replacement: Report from the United States clinical trial. **Orthop Clin N Am** 36:301–313, 2005.
- Denis F: Spinal instability as defined by the three-column spine concept in acute spinal trauma. **Clin Orthop Relat Res** 189:65–76, 1984.
- DePalma AF, Rothman RH: The nature of pseudarthrosis. **Clin Orthop Relat Res** 59:113–118, 1968.
- Dickman CA, Detweiler PW, Porter RW: Endoscopic spine surgery. **Clin Neurosurg** 46:526–553, 2002.
- Dickman CA, Rosenthal D, Karahalios DG, Paramore CG, Mican CA, Apostolides PJ, Lorenz R, Sonntag VKH: Thoracic vertebrectomy and reconstruction using a microsurgical thoracoscopic approach. **Neurosurgery** 38:279–293, 1996.
- Dixon RG, Mathis JM: Vertebroplasty and kyphoplasty: Rapid pain relief for vertebral compression fractures. **Curr Osteoporos Rep** 2:111–115, 2004.
- Dwyer AF, Wickham CG: Direct current stimulation in spinal fusion. **Med J Aust** 1:73–73, 1974.
- Edelman M: Percutaneous vertebroplasty: A review for the primary care physician. **Copr Ther** 31:237–240, 2005.
- Errico TJ: Lumbar disc arthroplasty. **Clin Orthop Rel Res** 435:106–117, 2005.
- Foley KT, Holly LT, Schwender JD: Minimally invasive lumbar fusion. **Spine** 28 [Suppl]:S26–S35, 2003.
- Foley KT, Gupta SK: Percutaneous pedicle screw fixation of the lumbar spine: Preliminary clinical results. **J Neurosurg** 97 [Suppl 1]:7–12, 2002.
- Foley KT, Lefkowitz MA: Advances in minimally invasive spine surgery. **Clin Neurosurg** 49:499–517, 2002.
- Fukuda E, Yasuda I: On the piezoelectric effect of bone. **J Physiol Soc Jpn** 12:1158–1162, 1957.
- Geesink RGT, Hoefnagels NHM, Bulstra SK: Osteogenetic activity of OP-1 bone morphogenetic protein (BMP-7) in a human fibular defect. **J Bone Joint Surg Br** 81B:710–718, 1999.
- Goodwin CB, Brighton CT, Guyer RD, Johnson Jr, Light KI, Yuan HA: A double-blind study of capacitively coupled electrical stimulation as an adjunct to lumbar spinal fusions. **Spine** 24:1349–1357, 1999.
- Guiot BH, Fessler RG: Molecular biology of degenerative disc disease. **Neurosurgery** 47:1034–1040, 2000.
- Hadra BE: The classic: Wiring of the vertebra as a means of immobilization in fracture and Pott's disease. **Clin Orthop** 93:110–112, 1973.
- Han PP, Dickman CA: Thoracoscopic resection of thoracic neurogenic tumors. **J Neurosurg** 96 [Suppl 3]:304–308, 2002.
- Han PP, Kenny K, Dickman CA: Thoracoscopic approaches to the thoracic spine: Experience with 241 surgical procedures. **Neurosurgery** 51 [Suppl 5]:S88–S95, 2002.
- Harrington PR: The history and development of Harrington instrumentation. **Clin Orthop Relat Res** 227:3–5, 1988.
- Harrington PR: Spinal instrumentation in the treatment of severe progressive spondylolisthesis. **Clin Orthop** 117:157–165, 1976.
- Harrington PR, Tullos HS: Spondylolisthesis in children. **Clin Orthop** 79:75–84, 1971.
- Harrington PR, Tullos HS: Reduction of severe spondylolisthesis in children. **South Med J** 62:17, 1969.
- Hartshone E: On the causes and treatment of pseudarthrosis and especially that form of it sometimes called supernumerary joint. **Am J Med** 1:121–156, 1841.
- Helm GA, Alden TD, Sheehan JP, Kallmes D: Bone morphogenetic proteins and bone morphogenetic protein gene therapy in neurological surgery: A review. **Neurosurgery** 46:1213–1222, 2000.
- Hibbs RA: An operation for progressive spinal deformities. **NY Med J** 93:1013–1016, 1911.
- Horn EM, Henn JS, Lemole GM Jr, Hott JS, Dickman CA: Thoracoscopic placement of dual-rod instrumentation in thoracic spinal trauma. **Neurosurgery** 54:1150–1154, 2004.
- Kane WJ: Direct current electric bone growth stimulation for spinal fusion. **Spine** 13:363–365, 1988.



50. Kim DH, Jaikumar S, Kam AC: Minimally invasive spine instrumentation. **Neurosurgery** 51 [Suppl 5]:S15–S25, 2002.
51. King D: Internal fixation for lumbosacral fusion. **J Bone Joint Surg** 30A:560–565, 1948.
52. Kowalski RJ, Ferrera LA, et al.: Biomechanics of bone fusion. **Neurosurg Focus** 10:2, 2001.
53. Lange F: Support for the spondylitic spine by means of burred steel bars attached to the vertebra. **Am J Orthop** 8:544–561, 1910.
54. Laurent JJ, Webb KM, Beres EJ, McGee K, Li J, van Rietbergen B, Helm GA: The use of bone morphogenetic protein-6 gene therapy for percutaneous spinal fusion in rabbits. **J Neurosurg Spine** 1:90–94, 2004.
55. Lemaire JP, Skalli W, Lavaste F, Templier A, Mendes F, Diop A, Sauty V, Laloux E: Intervertebral disc prosthesis: Results and prospects for the year 2000. **Clin Orthop Relat Res** 337:64–76, 1997.
56. Lim TH, Pathwardham AG, Wong JH: Effect of instrumented fusion on the biomechanics of adjacent segments: An in vivo canine study. Presented at the 42nd Annual Meeting, Orthopaedic Research Society, Atlanta, February 19–22, 1996.
57. Linovitz RJ, Ryaby JT, Magee FP, Faden JS, Ponder R, Muenz LR: Combined magnetic fields accelerate primary spinal fusion: A double blind, randomized, placebo controlled study. Presented at the 67th Annual Meeting of the American Association of Orthopaedic Surgeons, Orlando, March 15–19, 2000.
58. Louis-Ugbo J, Marakami H, Kim HS, Minamide A, Boden SD: Evidence of osteoinduction by Grafton® demineralized bone matrix in nonhuman primate spinal fusion. **Spine** 29:360–366, 2004.
59. Luque ER: Interpeduncular segmental fixation. **Clin Orthop** 203:54–57, 1986.
60. Luque ER: The anatomic basis and development of segmental spinal instrumentation. **Spine** 7:256–259, 1982.
61. Masuda K, Oegema TR Jr, An HS: Growth factors and treatment of intervertebral disc degeneration. **Spine** 29:2757–2769, 2004.
62. Mooney V: A randomized, double blind, progressive study of the efficacy of pulsed electromagnetic fields for interbody lumbar fusions. **Spine** 15:708–712, 1990.
63. Mummaneni PV, Haid RW, Rodts GE: Lumbar interbody fusion: State-of-the-art technical advances. Invited submission from the Annual Meeting of the AANS/CNS Section on Disorders of the Spine and Peripheral Nerves. **J Neurosurg Spine** 1:24–30, 2004.
64. Nachemson A: Some mechanical properties of the lumbar intervertebral discs. **Bull Hospital Joint Dis** 23:130–143, 1962.
65. Noel D, Gazit D, Boquet C, Apparailly F, Bony C, Plence P, Millet V, Turgeman G, Perricaudet M, Sany J, Jorgensen C: Short-term BMP-2 expression is sufficient for in vivo osteochondral differentiation of mesenchymal stem cells. **Stem Cells** 22:74–85, 2004.
66. Oakes DA, Lee CC, Lieberman JR: An evaluation of human demineralized bone matrices in a rat femoral defect model. **Clin Orthop Relat Res** 413:281–290, 2003.
67. Oishi M, Onesti ST: Electrical bone graft stimulation for spinal fusion: A review. **Neurosurgery** 47:1041–1056, 2000.
68. Pelled GT, Aslan H, Gazit Z, Gazit D: Mesenchymal stem cells for bone gene therapy and tissue engineering. **Curr Pharm Des** 8:1917–1928, 2002.
69. Peterson B, Whang PG, Iglesias R, Wang JC, Lieberman JR: Osteoinductivity of commercially available demineralized bone matrix: Preparations in a spine fusion model. **J Bone Joint Surg Am** 86A:2243–2250, 2004.
70. Polly DW Jr, Ackerman SJ, Shaffrey CI, Ogilvie JW, Wang JC, Stralka SW, Mafilios MS, Heim SE, Sandhu HS: A cost analysis of bone morphogenetic protein versus autogenous iliac crest bone graft in single-level anterior lumbar fusion. **Orthopedics** 26:1027–1037, 2003.
71. Resnick DK, Choudheri TF, Dailey AT, Groff MW, Khoo L, Matz PG, Mummaneni P, Watters WC 3rd, Wang J, Walters BC, Hadley MN: Part 11: Interbody techniques for lumbar fusion. **J Neurosurg Spine** 2:692–699, 2005.
72. Resnick DK, Choudheri TF, Dailey AT, Groff MW, Khoo L, Matz PG, Mummaneni P, Watters WC 3rd, Wang J, Walters BC, Hadley MN: Part 2: Assessment of functional outcome. Guidelines for the Performance of Fusion Procedures for Degenerative Disease of the Lumbar Spine. **J Neurosurg Spine** 2:639–646, 2005.
73. Resnick DK, Choudheri TF, Dailey AT, Groff MW, Khoo L, Matz PG, Mummaneni P, Watters WC 3rd, Wang J, Walters BC, Hadley MN: Part 15: Electrophysiological monitoring and lumbar fusion. Guidelines for the Performance of Fusion Procedures for Degenerative Disease of the Lumbar Spine. **J Neurosurg Spine** 2:725–732, 2005.
74. Resnick DK, Choudheri TF, Dailey AT, Groff MW, Khoo L, Matz PG, Mummaneni P, Watters WC 3rd, Wang J, Walters BC, Hadley MN: Part 17: Bone growth stimulators and lumbar fusion. Guidelines for the Performance of Fusion Procedures for Degenerative Disease of the Lumbar Spine. **J Neurosurg Spine** 2:737–740, 2005.
75. Rogozinski A, Rogozinski C: Efficacy of implanted bone growth stimulation in instrumented lumbosacral spinal fusion. **Spine** 21:2479–2483, 1996.
76. Rosenthal D, Dickman CA: Thoracoscopic microsurgical excision of herniated thoracic discs. **J Neurosurg**, 89:224–235, 1998.
77. Roy-Camille R, Saillant G, Mazel C: Internal fixation of the lumbar spine with pedicle screw plating. **Clin Orthop Relat Res** 203:7–17, 1986.
78. Schwartzbach O, Berlemann U, Stoll TM, Dubois G: Posterior Dynamic Stabilization Systems: DYNESYS. **Orthop Clin N Am** 36:363–372, 2005.
79. Schwender JD, Holly LT, Rouben DP, Foley KT: Minimally invasive transforaminal lumbar interbody fusion (TLIF): Technical feasibility and initial results. **J Spinal Disord Tech** Feb [Suppl 18]:S1–S6, 2005.
80. Senegas J: Mechanical supplementation by nonrigid fixation in degenerative intervertebral lumbar segments: The Wallis system. **Eur Spine J** 11 [Suppl 2]:S186–S191, 2002.
81. Simmons JW: Treatment of failed posterior lumbar interbody fusions (PLIF) of the spine with pulsing electromagnetic fields. **Clin Orthop** 193:127–132, 1985.
82. Singh K, Heller JG, Samartzis D, Price JS, An HS, Yoon ST, Rhee J, Ledlie JT, Philips FM: Open vertebral cement augmentation combined with lumbar decompression for the operative management of thoracolumbar stenosis secondary to osteoporotic burst fractures. **J Spinal Disord Tech** 18:413–419, 2005.
83. Steinmann JC, Herkowitz HN: Pseudarthrosis of the spine. **Clin Orthop Relat Res** 284:80–90, 1992.
84. Substad JA, Urbabiak JR, Kahn P: Prosthesis for spinal repair, United States Patent 3867728, 25–02–1975, 1975.
85. Szpalski M, Gunzburg R, Mayer M: Spine Arthroplasty: A historical review. **Eur Spine J** 11 [Suppl 2]:S65–S84, 2002.
86. Thompson JP, Oegema TR Jr, Bradford DS: Stimulation of mature canine intervertebral disc by growth factors. **Spine** 16:253–260, 1991.
87. Tropiano P, Huang RC, Girardi FP, Cammisa FP Jr, Marnay T: Lumbar total disc replacement. Seven to eleven-year follow-up. **J Bone Joint Surg Am** 87:490–496, 2005.
88. Turgeman G, Aslan H, Gazit Z, Gazit D: Cell-mediated gene therapy for bone formation and regeneration. **Curr Opin Mol Ther** 4:390–394, 2002.
89. van Steenbrugge MH: Perfectionnements aux protheses articulaires, French Patent 1.122.634, 1956.
90. Verlaan JJ, Oner FC, Dhert WJ: Anterior spinal column augmentation with injectable bone cements. **Biomaterials** 27:290–301, 2006.
91. Verlaan JJ, van de Kraats EB, Oner FC, van Walsum T, Niessen WJ, Dhert WJ: The reduction of endplate fractures during balloon vertebroplasty: A detailed radiological analysis of the treatment of burst fractures using pedicle screws, balloon vertebroplasty, and calcium phosphate cement. **Spine** 30:1840–1845, 2005.
92. Verlaan JJ, van de Kraats EB, Oner FC, van Walsum T, Niessen WJ, Dhert WJ: Bone displacement and the role of longitudinal ligaments during balloon vertebroplasty in traumatic thoracolumbar fractures. **Spine** 30:1832–1839, 2005.
93. Walsh AJ, Bradford DS, Lotz JC: In vivo growth factor treatment of degenerated intervertebral discs. **Spine** 29:156–163, 2004.
94. Weiner BK, Walker M: Efficacy of autologous growth factors in lumbar intertransverse fusions. **Spine** 28:1968–1971, 2003.
95. West JL 3rd, Bradford DS, Ogilvie JW: Results of spinal arthrodesis with pedicle screw-plate fixation. **J Bone Joint Surg Am** 8:1179–1184, 1991.
96. Zucherman JF, Hsu KY, Hartjen CA, et al.: A prospective randomized multi-center study for the treatment of lumbar spinal stenosis with the XSTOP interspinous implant: 1 year results. **Eur Spine J** 13:22–31, 2004.