

Which Intracranial Lesions Would Be Suitable for 5-Aminolevulinic Acid–Induced Fluorescence-Guided Identification, Localization, or Resection? A Prospective Study of 114 Consecutive Intracranial Lesions

M. Sam Eljamel, M.D.

5-Aminolevulinic acid (ALA) is a naturally occurring compound in all living mammalian cells.¹³ ALA is formed within the mitochondria from glycine and metabolized along a pathway in the cytosol and mitochondria into protoporphyrin-IX (PpIX) before combining with ferrous to form heme.^{6,12,14,15} The transformation from PpIX to heme is a rate-limiting step in all tumor cells leading to accumulation of PpIX in the mitochondria of these cells.^{6,12,14,15} PpIX fluoresces under blue light, and its fluorescence can be observed leading to the application of fluorescence-guided resection (FGR) and fluorescence image-guided surgery (FIGS).^{6,14,15} Stummer et al.¹⁴ reported a prospective, uncontrolled series of high-grade gliomas in 2000 and concluded that ALA-induced FGR was very specific and highly sensitive and led to complete resection of enhanced tumor tissue in more than 60% of patients. The ALA study group reported a randomized, controlled trial (RCT) in which the study population had high-grade gliomas removed using ALA-induced FGR.¹⁵ Gross total resection was accomplished in 65% of the study group compared with 35% of the controls ($P < 0.001$), with a tumor-free survival gain of more than 6 weeks ($P < 0.001$).¹⁵ Eljamel et al.⁶ reported an RCT in which ALA+Photofrin-induced FIGS and repetitive photodynamic therapy (PDT) were used and demonstrated that complete surgical resection was achieved in 77% of the study group, with a tumor-free survival gain of 3.8 months.

This study prospectively explored the use of ALA-induced fluorescence in a wide range of intracranial tumors that may benefit from this technology in terms of intraoperative localization or gross total resection.

METHOD

This study was approved by the institutional committee on medical research ethics at The University of Dundee,

Centre for Neurosciences. Patients with a diagnosis of intracranial tumors that might benefit from FIGS were approached to participate in this study.

Patients were given ALA (20 mg/kg body weight) to drink 3 hours before anesthesia. The ALA was mixed in 30 mL of nonfizzy orange juice during this study. The patients underwent a magnetic resonance imaging (MRI) scan before surgery with skin fiducials for surgical planning using the StealthStation (Medtronic Sofamor Danek USA, Minneapolis, MN) linked to a surgical microscope with head-up display (Carl Zeiss, Oberkochen, Germany) or the PathFinder surgical robotic system (Prosurge, Bracknell, UK). The surgical approach used depended on the type and location of the tumor.

Surgery was performed according to the surgical plan using a straight scalp incision without shaving, and once the dura mater was opened, an optical biopsy system (OBS) was used to detect PpIX. PpIX detection was based on finding a spectrum peak at 632 nm (*Fig. 17.1*). The OBS consisted of a compact gallium nitride laser emitting a narrow band of blue light at 405 nm. The blue light was carried out via a beam splitter to a fiberoptic fiber/probe that can be inserted into the lesion. Fluorescence was transmitted back through the same fiberoptic fiber/probe into the beam splitter to a compact spectrometer. The spectrometer analyzed the fluorescence signal and displayed the results on a laptop screen (*Fig. 17.2*). Background light interference was removed at the beginning of the procedure by testing the OBS probe in complete darkness to create a baseline reference point (calibration).

Once the lesion was identified, the fluorescence detection endoscope (Olympus, Hamburg, Germany) or microscope photodiagnosis system (PDS) was used to guide the resection. All fluorescent material was removed, and the resected material was sent for histopathological examination. All the fluorescent tissue was examined very rigorously to determine whether the fluorescent material contained tumor. When no fluorescence was detected, the OBS was used systematically in the resection cavity looking for any residual

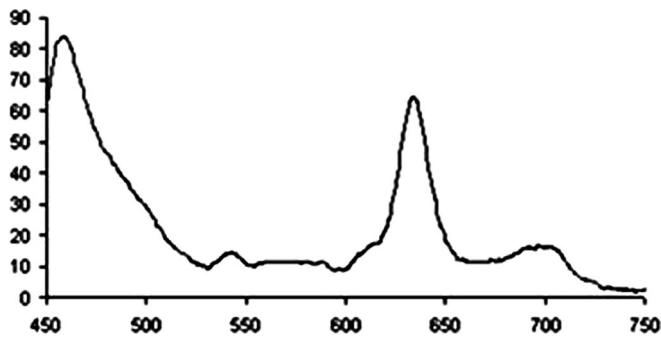


FIGURE 17.1. Protoporphyrin-IX (PpIX) fluorescence spectrum, the peak at 632 nm is PpIX.

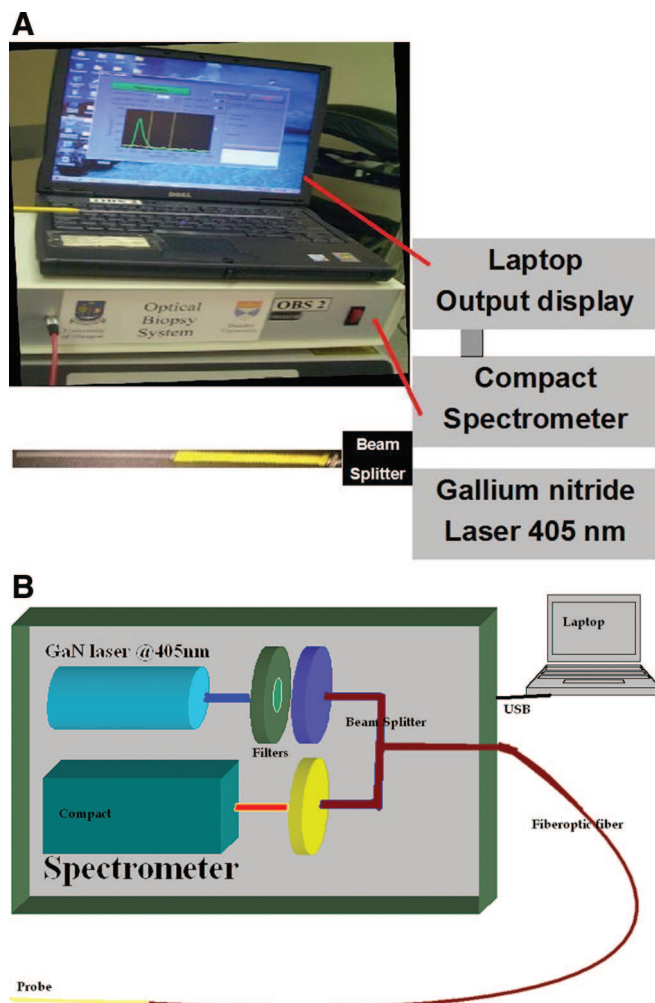


FIGURE 17.2. **A**, The optical biopsy system (OBS). **B**, Schematic drawing of the OBS. GaN, gallium nitride.

PpIX. When nonfluorescent material was resected inadvertently or as part of the resection specimen, the nonfluorescent material was also examined for the presence of tumor tissue and PpIX. The endoscope and microscope housed a light

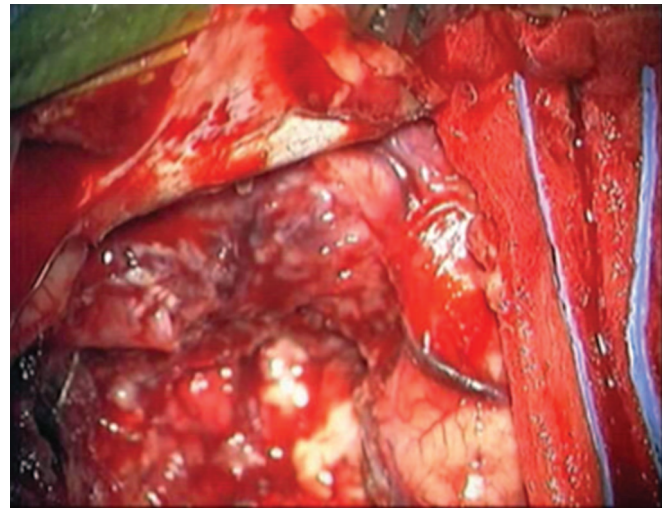


FIGURE 17.3. Photomicrograph of a glioblastoma multiforme under standard light.

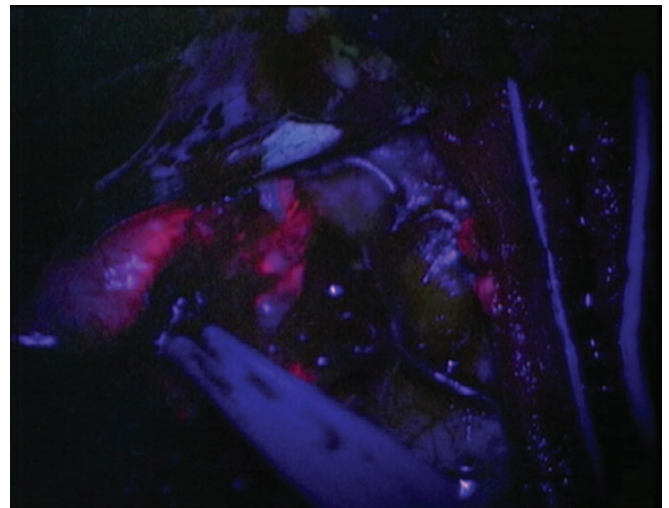


FIGURE 17.4. Photomicrograph of same glioblastoma multiforme shown in Figure 17.3 under blue light demonstrating the red fluorescence of tumor versus blue background of surrounding tissues.

source that can switch from standard white light to blue light at the flick of a button. The blue light source was designed to allow enough illumination for the surgeon to operate and recognize surrounding structures. The camera system was modified with a long-pass 440-nm filter to visualize the fluorescence in the red spectrum (Figs. 17.3 and 17.4). The pathological results were then correlated with the fluorescence findings. The OBS was used to detect the PpIX in the surrounding structures that did not fluoresce under the blue light and any normal nonfluorescent tissue that was resected inadvertently was subjected to rigorous histological analysis to find any evidence of tumor invasion. Patients were man-

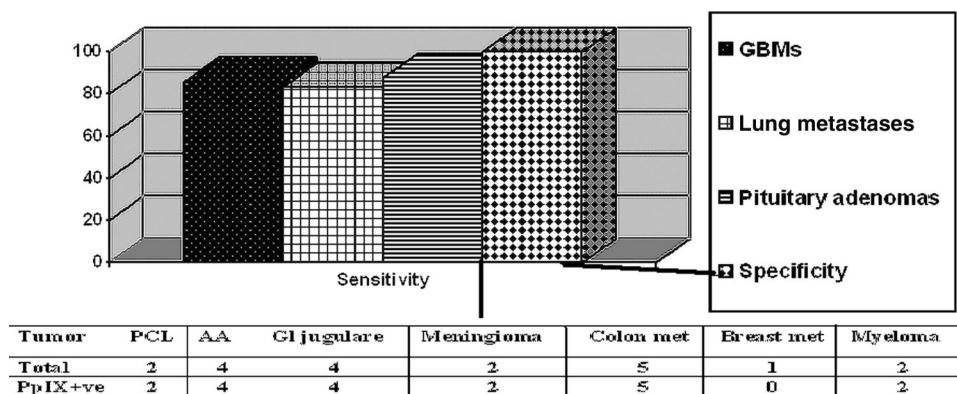


FIGURE 17.5. Graph of 5-aminolevulinic acid–induced fluorescence in 114 intracranial lesions. AA, anaplastic astrocytoma; GBM, glioblastoma multiforme; Gl, glioma; Met, metastases; PpIX+ve, protoporphyrin-IX positive; PCL, primary cerebral lymphoma.

aged postoperatively in the neurosurgical high-dependency unit, intensive care unit, or the general neurosurgical ward, as deemed necessary by surgeon and anesthetist. Protection from bright light was implemented by drawing the curtains and avoiding direct light exposure. During surgery, the pulse oximeter was used intermittently to monitor oxygen saturation to avoid prolonged exposure of one finger to the red light of the pulse oximeter.

RESULTS

A total of 114 patients were recruited; 83 had primary tumors, 22 had brain metastases, and nine had lesions that turned out to be nontumors. The primary tumors included 39 glioblastomas (glioblastoma multiforme [GBM]), four anaplastic astrocytomas, two ependymomas, two primary cerebral lymphomas, 27 pituitary adenomas, four glomus jugulare tumors, two meningiomas, one chordoma, and two myelomas. The metastases were from lung cancer in 12 patients, malignant melanoma in four, colon cancer in five, and breast cancer in one. We also examined the adjacent dura mater, surrounding normal brain tissue, adjacent vessels, and optic nerves for comparison whenever possible using the OBS and the endoscope/microscope.

Of 105 tumors, 94 were fluorescent under the blue light (89.5% sensitivity) and demonstrated the typical PpIX spectrum. All nontumors including adjacent brain, optic nerves, carotid arteries, veins, and dura mater showed no fluorescence under the blue light and no PpIX was detected by the OBS (100% specificity). All the resected fluorescent material contained tumor tissue, none of the inadvertently resected normal brain or dura demonstrated any fluorescence, and no PpIX was detected by the OBS. Fluorescence was observed in all anaplastic astrocytomas, primary cerebral lymphomas, colon cancer metastases, meningiomas, and multiple myelomas, but the numbers of tumors in these subgroups were relatively small. In tumors for which there were sufficient numbers, the sensitivity varied from 83.34% in pulmonary

metastases to 85.7% in GBMs to 87.5% in pituitary adenomas (PAs). Detailed analysis of sensitivity of the 114 intracranial lesions examined is shown in *Figure 17.5*.

Although the primary aim of this study was to evaluate the specificity and sensitivity of fluorescence in a wide range of brain tumors, routine postresection MRI was obtained in intrinsic gliomas and metastases. Complete resection was achieved in 77% of the tumors.

DISCUSSION

This study explored the use of ALA-induced fluorescence in a wide range of intracranial tumors that might benefit from fluorescence-guided identification, fluorescence-guided localization, or FGR. The outcome of preoperative MRI localization of PAs in Cushing’s disease, for example, can be as low as 69%,³ whereas nonsecreting PAs tend to present late and by the time they reveal themselves clinically, they often had already invaded the cavernous sinus and surrounding structures, making their eradication more difficult.^{9,12} Therefore, fluorescence would be potentially useful for intraoperative localization of PAs (microadenomas) that were not localized by preoperative MRI or for the eradication of invasive PAs. Surgery still is the best single therapy for PAs that present with acromegaly and Cushing’s disease, those that compress the optic chiasm, and those that present with hyperprolactinemia if medical therapy fails or the patients did not tolerate the treatment because of side effects. One of the reasons that pituitary surgery is not curative in every case of pituitary microadenomas is the difficulty in localizing the exact site of the microadenoma pre- and intraoperatively. One of the new and exciting applications of ALA-induced fluorescence is to pinpoint the exact location of the microadenoma. Our study demonstrated a sensitivity of 87.5%, which is quite good compared with other existing methods used for this purpose. Conversely, macroadenomas and giant PAs cannot be cured by surgery because of their invasion of the

cavernous sinus and other surrounding structures, leading to a failure rate as high as 73% in some series.^{1,2,8,9,12} A new and exciting application of ALA-induced fluorescence is to improve the completeness of resection in this group because of the high specificity and sensitivity. For years, neuroendocrine teams around the world did their best to improve preoperative microadenoma localization with very limited success. Dynamic MRI had improved preoperative microadenoma localization, and success rates as high as 64% were reported.⁷ Bilateral inferior petrosal sinus sampling had also improved the localization of corticotropic microadenoma. Bilateral inferior petrosal sinus sampling can only lateralize microadenoma to the location of the right or left half of the pituitary gland in Cushing's disease in as many as 81% of cases.¹¹ The intraoperative detection rate of 87.5% of ALA-induced fluorescence is outstanding compared with other techniques. The limitation of this technique in pituitary surgery is that the microadenomas are often not visible on the surface, and a system similar to the OBS would be required that can be inserted in the gland to look for PpIX. The fluorescence from PAs is not as bright as that observed in GBMs and the use of the correct long-pass filter and adjustment of the fluorescence detection system would be required to optimize visualization.

Conversely, GBM is locally malignant brain cancer that leads to inevitable death within 2 years of diagnosis in almost all but a very few patients.^{4,10} Its ability to invade the brain renders it beyond the reach of the surgical microscope. Although FIGS and FGR in high-grade glioma surgery are safe and commercially available, FGR on its own did not improve survival of those with GBM.² However, there were clear advantages of FGR over standard surgical resection: completeness of tumor resection was doubled using FGR ($P < 0.001$), tumor-free survival was also significantly improved by FGR ($P < 0.001$), and it increased surgeons' confidence during operations. The ability of the surgeon to distinguish what is and what is not tumor is very important during surgery. It makes tumor removal proceed quickly and smoothly. The main disadvantage of FGR is that blood in the surgical field can obscure the fluorescence, and it would be necessary to switch back to standard white light setting so that the bleeding can be stopped. In tumors located within the ventricle, clear cerebrospinal fluid does not hinder fluorescence. There was one tumor in this study that was inside the lateral ventricle; the tumor fluoresced and was easily seen, but the fluorescence was difficult to ascertain when the cerebrospinal fluid was contaminated with blood. This can be more difficult if the surgical field is deep and narrow because the amount of illumination is inversely related to the depth of field. The light intensity and the intensity of fluorescence exponentially decrease as the distance between the illuminated field and the microscope increases.⁵ This difficulty can be overcome by using a modified endoscope system that brings the blue light and endoscope nearer to the tumor.

Another limitation of FGR is the fact that light travels in straight lines, so it would be very easy to miss fluorescent tissue hidden behind the enfolding edges of the resection cavity. If the surgeon is working in a deep, narrow hole, an endoscope with fluorescence detection technology and at different viewing angles (0-, 30-, 70-degree endoscopes) would be useful. FGR was very specific in brain in which only tumor tissue fluoresced and adjacent structures such as blood vessels, blood, normal brain, olfactory tract, cavernous sinus, dura mater, and optic nerves did not fluoresce. Any normal tissue inadvertently removed during surgery did not demonstrate any PpIX when examined by the OBS, and no tumor invasion when rigorously examined histologically. However, FGR is not 100% sensitive because of photobleaching effects, as shown in this study. The sensitivity was only 85.7% in GBMs and 83.34% in metastatic lung cancer. Photo bleaching can be minimized by reducing the light intensity when operating under standard white light and shielding parts of the operating field from light by paddies during surgical inactivity. Darkening the operating room also minimizes photo bleaching and enhances visualization of fluorescence.¹⁶ However, none of the nontumors and adjacent normal structures exhibited any fluorescence with no false-positive results, giving this technology a very high specificity.

Although this study explored fluorescence and FGR in a wide range of tumors, the numbers in some of the tumor subgroups are very small (anaplastic astrocytomas, primary cerebral lymphomas, ependymomas, meningiomas, glomus jugulare, chordomas, and metastases from breast cancer, malignant melanoma, colon cancer) and the sensitivity and specificity could not be determined for certain. Further studies are required to enhance our understanding of FGR and improve its sensitivity for the benefit of our patients. Furthermore, FGR is not affected by brain shift and tissue removal and has the potential to enhance our ability to completely excise intrinsic brain lesions and minimize collateral brain damage. Another important issue is whether maximizing tumor resection leads to increased morbidity. In a previously published RCT of GBMs, Eljamel et al.⁶ demonstrated that patients who were operated on using fluorescence guidance had a better Karnofsky performance score postoperatively compared with the control group. This is again a reflection that the surgeons are more likely to restrict their resection to what is abnormal (fluorescent) with FGR without guessing where the tumor margins were.

CONCLUSION

ALA-induced fluorescence is tumor specific in the brain including gliomas, adenomas, and metastases and therefore can be used reliably to detect and localize these lesions intraoperatively, thus boosting the surgeons' confidence, and can be used to guide surgical resection to maximize tumor removal and minimize collateral damage.

Disclosure

The author has no personal financial or institutional interest in any of the drugs, materials, or devices described in this article.

REFERENCES

1. Amar AP, Hinton DR, Krieger MD, Weiss MH: Invasive pituitary adenomas: Significance of proliferation parameters. *Pituitary* 2:117–122, 1999.
2. Anson JA, Segal MN, Baldwin NG, Neal D: Resection of giant invasive pituitary tumors through a transfacial approach: Technical case report. *Neurosurgery* 37:545–546, 1995.
3. Bonelli FS, Huston J 3rd, Carpenter PC, Erickson D, Young WF Jr, Meyer FB: Adrenocorticotropic hormone-dependent Cushing's syndrome: Sensitivity and specificity of inferior petrosal sinus sampling. *AJNR Am J Neuroradiol* 21:690–696, 2000.
4. Devaux BC, O'Fallon JR, Kelly PJ: Resection, biopsy and survival in malignant glial neoplasms. A retrospective study of clinical parameters, therapy, and outcome. *J Neurosurg* 78:767–775, 1993.
5. Eljamel MS. Fluorescence image-guided surgery of brain tumors: Explained step-by-step. *Photodiagnosis Photodyn Ther* 5:260–263, 2008.
6. Eljamel MS, Goodman C, Moseley H. ALA and Photofrin fluorescence-guided resection and repetitive PDT in glioblastoma multiforme: A single centre Phase III randomised controlled trial. *Lasers Med Sci* 23:361–367, 2008.
7. Indrajit IK, Chidambaranathan Sundar NK, Ahmed I: Value of dynamic MRI imaging in pituitary adenomas. *Neuroradiology* 11:185–190, 2001.
8. Majós C, Coll S, Aguilera C, Acebes JJ, Pons LC: Imaging of giant pituitary adenomas. *Neuroradiology* 40:651–655, 1998.
9. Meij BP, Lopes MB, Ellegala DB, Alden TD, Laws ER Jr: The long-term significance of microscopic dural invasion in 354 patients with pituitary adenomas treated with transsphenoidal surgery. *J Neurosurg* 96:195–208, 2002.
10. Obwegeser A, Ortler M, Seiwald M, H. Ulme H, Kostron H: Therapy of Glioblastoma multiforme, a cumulative experience of 10 years. *Acta Neurochir (Wien)* 137:29–33, 1995.
11. Oldfield EH, Doppman JL, Nieman LK, Chrousos GP, Miller DL, Katz DA, Cutler GB Jr, Loriaux DL: Petrosal sinus sampling with and without corticotrophin-releasing hormone for the differential diagnosis of Cushing's syndrome. *N Engl J Med* 325:897–905, 1991.
12. Oruçkaptan HH, Senmevsim O, Ozcan OE, Ozgen T: Pituitary adenomas: Results of 684 surgically treated patients and review of the literature. *Surg Neurol* 53:211–219, 2000.
13. Peng Q, Warloe T, Berg K, Moan J, Kongshaug M, Giercksky KE, Nesland JM: 5-Aminolevulinic acid-based photodynamic therapy. Clinical research and future challenges. *Cancer* 79:2282–2308, 1997.
14. Stummer W, Novotny A, Stepp H, Goetz C, Bise K, Reulen HJ: Fluorescence-guided resection of glioblastoma multiforme by using 5-aminolevulinic acid-induced porphyrins: A prospective study in 52 consecutive patients. *J Neurosurg* 93:1003–1013, 2000.
15. Stummer W, Pichlmeier U, Meinel T, Wiestler OD, Zanella F, Reulen HJ; ALA-Glioma Study Group: Fluorescence-guided surgery with 5-aminolevulinic acid for resection of malignant glioma: A randomised controlled multicentre phase III trial. *Lancet Oncol* 7:392–401, 2006.
16. Tonn JC, Stummer W. Fluorescence-guided resection of malignant gliomas using 5-aminolevulinic acid: Practical use, risks, and pitfalls. *Clin Neurosurg* 55:20–26, 2008.