



For Your Information

- Food & drink may be carried anywhere in the building except the Coral Reef area.
- Smoking is only permitted in the Harbor View Room - Level 4.
- Photography is permitted.
- Restrooms are located on the Lobby Level & Level 4.
- The Rain Forest Exhibit is not open at night to allow the animals a normal day-night cycle.
- The Habitat Theater is in operation - Level 3.
- The Aquarium closes at 11 p.m.



Program

7:00 p.m.	Hors D'Oeuvres & Bar	Lobby Level
7:30 p.m.	Hors D'Oeuvres & Bar	Level 3
8:00 p.m.	Buffet & Bar	Level 4
9:30 p.m.	Dessert & Coffee	Lobby Level
9:30 p.m.	Diver Feeds The Fish - Coral Reef	Level 3
10:00 p.m.	Diver Feeds The Fish - Coral Reef	Level 3

Have A Great Evening

American Association of Neurological Surgeons
Congress of Neurological Surgeons



NEUROLOGICAL



SURGERY



Neurosurgery is the medical specialty that provides medical and surgical care to patients with disorders of the brain, spinal cord, and nerves. Neurosurgeons treat a diversity of conditions affecting the body since diseases of other organs can have their most serious consequences on the brain and other parts of the nervous system.

NEUROSURGICAL TREATMENT

The following pages describe some of the disorders of the central and peripheral nervous systems that are treated by neurosurgeons by either operative or non-operative methods or both. These are only examples, since neurological surgeons manage a much wider range of conditions than are described here.

Trauma

Accidents often result in injury to the skull, brain, spinal cord, bones of the spine, or nerves. Head and spine injuries are the most common cause of death in individuals under the age of 35, and more than 100,000 people suffer nonfatal *injury to the brain* each year. Neurosurgical care aims to

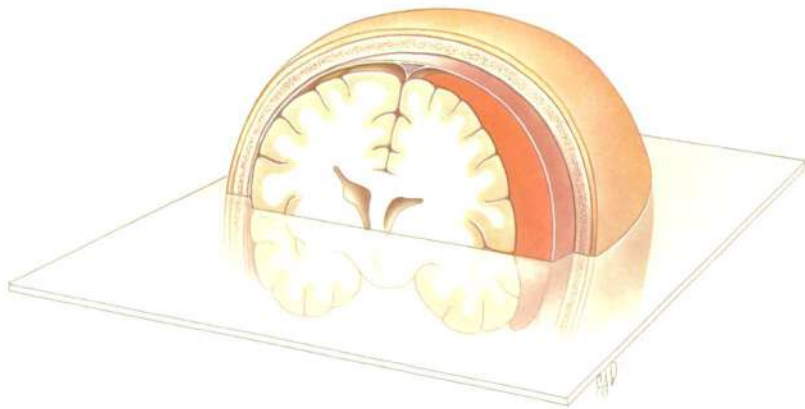


Figure 1A. Diagrammatic representation of a large blood clot compressing the brain. The transparent sheet represents the plane shown in the computed tomographic (CT) scan in Figure 1B.

decrease the extent of damage to the nervous system and speed the patient's rehabilitation. CT scans of the brain after injury may reveal blood clots, bone fragments or foreign matter that require immediate removal. The neurosurgeon can place a device to monitor brain swelling, and if swelling is extensive, prescribe effective measures to reverse the condition. Surgical operations on the brain generally are carried out soon after the injury, though sometimes delayed surgery is required, for example, to put in a plate to repair a defect in the skull.

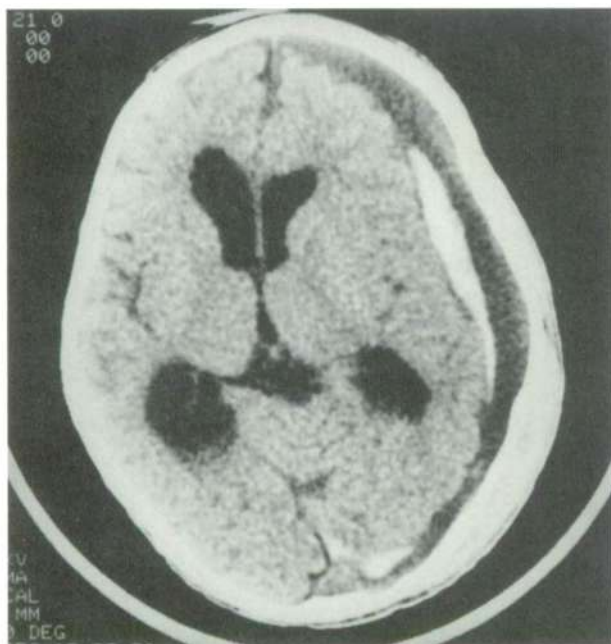


Figure 1B. Computed (CT) scan showing large chronic blood clot. The dark portion of the clot is older, partially liquefied blood. The white area within the clot is caused by fresh blood in this space.

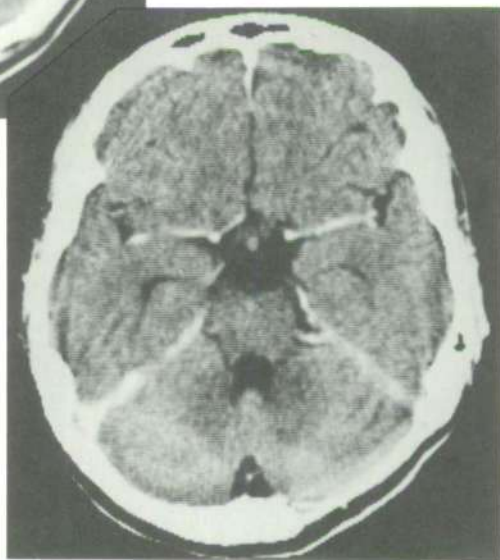
An emergency neurosurgical operation is often required after *spinal injury*. Certain spine fractures, especially in the neck, are unstable, and likely to slip, risking further spinal cord damage. Initial treatment may be with a neck collar or traction. If this is not adequate to stabilize the spine, an operation may be necessary.

Lacerations of the nerves can paralyze muscles and need to be repaired either immediately or after a delay of several weeks, depending upon the type of injury. Surgical techniques, using the operating microscope, can stitch cut nerves together, allowing the rejoined nerves to grow successfully. When a portion of a nerve is destroyed, neurosurgeons may graft a piece of nerve taken from elsewhere in the body to fill the gap.

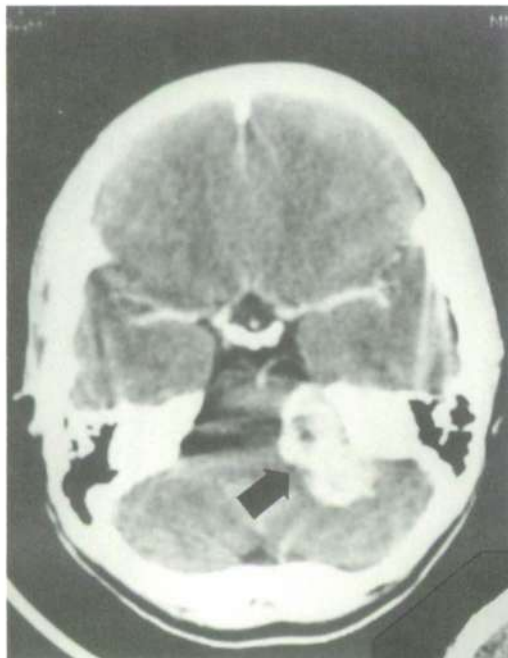

Figure 2A. C.T. scan showing a large tumor (acoustic neuroma) arising from the auditory nerve. This benign tumor had caused deafness in the right ear and was compressing vital structures at the base of the brain.

Figure 2B. Post-operative scan showing total removal of the tumor. Use of the operating microscope allowed safe separation of the tumor from the vital brain structures, while the ultrasonic aspirator permitted removal of the bulk of the tumor without moving delicate nerves.



Tumors

Tumors of the nervous system are treated by neurosurgeons. Common in adults, brain tumors are the second leading cause of cancer-related deaths in children. Fortunately, with recent technological advances, many tumors at all ages can be operated upon in a highly satisfactory manner and with the expectation of cure.

Certain tumors are quite distinct from the brain or spinal cord tissue, allowing their total removal. Many of these tumors are benign, and the patient is cured with excision of the mass. Formerly inaccessible or inoperable tumors may now be safely removed by employing the operating microscope, laser, and specialized techniques such as electrocoagulation and the ultrasonic dissector.

Some brain tumors have roots that spread widely through the tissues of the brain itself, and total removal may not be feasible. Some of these tumors enlarge slowly, whereas others are more rapidly growing. Many of these tumors are malignant and often grow back, even if only a little bit remains. Additional therapies such as radiation and chemotherapy are used to retard the growth of the tumor left behind after operation. New experimental therapies utilizing radiation isotope implants, immunotherapy, hyperthermia, interferon and new antitumor drugs are under investigation.

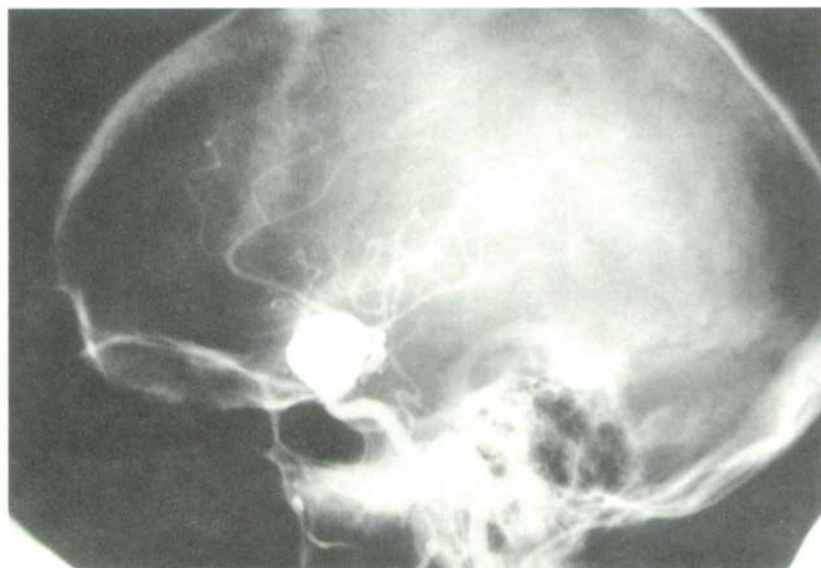

Figure 3 Arteriogram of the carotid artery supplying the brain. This artery has developed an aneurysm, a blister like weakness of the vessel wall. If this ruptures, it may cause seizures, paralysis, coma, or death.

Vascular Disease

Neurological surgeons may restore blood flow to the brain or spinal cord, remove blood clots, or repair weakened blood vessels. *Strokes* are the most common cause of prolonged disability in the United States and

the third leading cause of death. They may be caused by brain hemorrhage or by blockage of an artery that supplies blood to the brain. Many cases of brain hemorrhage are due to a weak point on a brain artery that a neurosurgeon can repair to prevent future hemorrhages. An artery blocked by arteriosclerosis in the neck can be cleaned out to restore blood to the brain, or in some cases a bypass around the block can improve blood flow.

Congenital Abnormalities

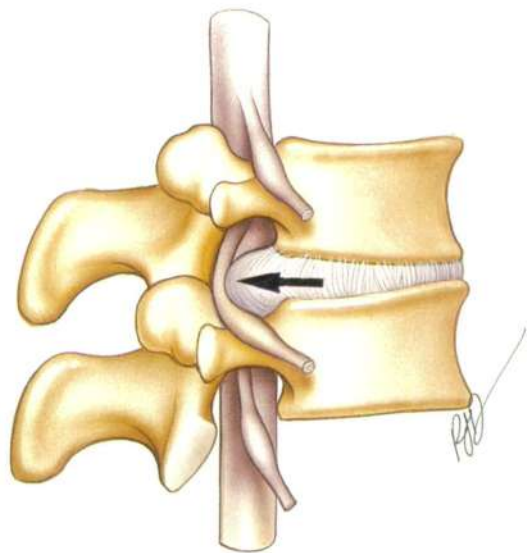
Many neurosurgical conditions affect infants and children. These include birth defects that result in paralysis of the legs, or in mental retardation. Many of these conditions may be successfully treated, allowing the child to lead a happy and productive life. Some disorders, present at birth, may not become known until later in life and require treatment at that time.

Spine and Peripheral Nerves

Nerves in the neck or low back may be pinched by either a ruptured disc or a bone spur. The result is pain and weakness in an arm or a leg. Neck and back trouble are the most common disorders treated by

Figure 4 Representation of the spine as seen from the side.

The disc (arrow) normally separated the vertebra of the spine. Here the disc is bulging backward, compressing the nerve root.



neurosurgeons. Treatment for these problems may include bed rest, traction or physical therapy. Surgery is reserved for those circumstances in which other therapies have failed and pain persists or serious paralysis develops. Nerves in the arms or legs may become scarred or trapped by surrounding ligaments or muscles. Release of these nerves surgically may relieve pain and restore function. Neurosurgical operations have steadily improved so that results are better and the period of postoperative disability lessened.

Epilepsy

Many persons have forms of epilepsy which cannot be adequately controlled through medication. Using new diagnostic tools, neurological surgeons can identify and remove the area of the brain which triggers the seizures.

Pain

Patients with persistent, unremitting pain often are sent to neurosurgeons for help. When the primary cause of pain cannot be detected, or is not itself a repairable condition, neurosurgical operations have been specifically designed to interrupt the pain signal as it comes into the brain or spinal cord, enabling the patient to resume his normal life. Neurological treatment may include severing the nerves of a portion of the spinal cord carrying pain messages, or inserting tubes to the spine or brain to allow the continuous administration of pain-relieving medicine. Perhaps the best known of these painful conditions is trigeminal neuralgia (*tic douloureux*). The treatment of cancer pain is also an important area of neurosurgical concern.

Infection

Infections may affect either the brain or spinal cord. Neurosurgical operations may be required to release abscesses that press on the brain, spinal cord, or peripheral nerves.

NEUROSURGICAL TRAINING

Neurosurgical training is long and rigorous due both to the great complexity of the nervous system and the increasing sophistication and technology of neurosurgical operations. After four years of college and five years of medical school and internship, the aspiring neurosurgeon enters a neurosurgical residency. Residency training generally lasts from five to seven years. The trainee must learn how the normal brain functions as well as become familiar with all the diseases that affect it. Modern diagnostic tests are numerous and complicated and require a great deal of study. The trainee needs to know which conditions can be treated medically and which require surgical intervention. A substantial portion of the period of training is devoted to learning how to operate. As training progresses, the trainee is exposed to operations of increasing complexity. Certain highly technical skills, such as the use of the operating microscope, the laser, and suturing of fine blood vessels within the cerebral circulation require extensive practice in the laboratory.

BOARD CERTIFICATION

The major responsibility for defining the training program of individuals in their residency lies with the American Board of Neurological Surgery. The Board administers a written examination that is usually taken in the latter part of residency training. The second part of the Board examination is taken after the candidate successfully completes the written examination and finishes his residency training. After two years of practice, the final test is an oral examination that leads to the neurosurgeon becoming certified by the Board.



Figure 5 *Harvey Cushing. His pioneering efforts dramatically lowered the mortality rate for brain operations, while his study of patients with pituitary tumors provided much of our understanding of the function of this gland.*

NEUROSURGICAL ORGANIZATIONS

Neurosurgeons gather together to exchange professional information and expand their medical education at the state, local and national levels.

Two large national organizations play a major role in the continuing medical education processes of their members: The American Association of Neurological Surgeons and the Congress of Neurological Surgeons. The American Association of Neurological Surgeons requires board certification for active membership, and has been designated as the official spokesman for neurological surgery at the national level. The Congress of Neurological Surgeons has focused on younger neurosurgeons, not requiring board certification for membership and limiting the age of its officers at the time of election to no greater than 45 years of age. Both organizations hold Annual Meetings to disseminate new clinical and scientific information and to review a broad spectrum of neurosurgical issues. Each organization publishes a major neurosurgical journal (*JOURNAL OF NEUROSURGERY* and *NEUROSURGERY*). Besides the large national meetings, many smaller meetings addressing a single neurosurgical topic are held around the country throughout the year.

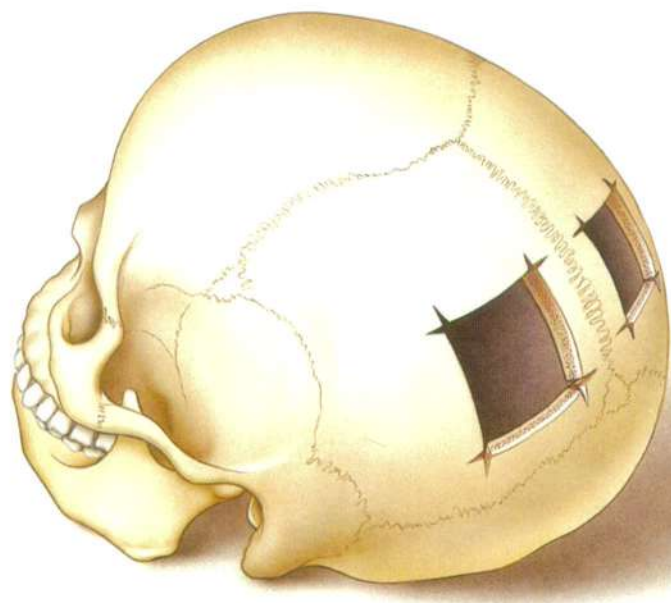


Figure 6 Skull found in Peru said to have been operated by a pre-Inca surgeon. These square holes were apparently made by scraping with a sharpened stone. This ancient doctor carefully avoided the exact center of the head, where a large vein stuck to the undersurface of the skull would have bled profusely.

HISTORY OF NEUROSURGERY

While the development of neurosurgery as a surgical specialty has taken place almost entirely within the twentieth century, it is perhaps the oldest documented surgical art, with evidence of crude neurosurgical procedures as early as 7,000 B.C. No fundamental advances were made in neurological surgery until the late nineteenth century, when electrical stimulation of the brain led to greater knowledge of the functions of the nervous system and the availability of reliable anesthesia made brain operations possible. Improved diagnostic techniques and the development of methods to control bleeding and infection in the early twentieth century led to the spread of the specialty throughout North America and Europe.

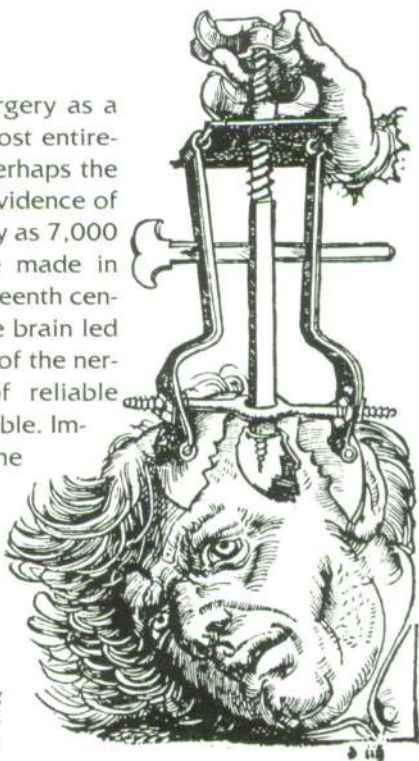


Figure 7 Fifteenth-century device for removing bone fragments following skull fracture. This cork-screw gadget would release bone pieces driven into the brain.

RECENT DEVELOPMENTS IN NEUROLOGICAL SURGERY

One of the major problems neurosurgeons face is that of brain swelling as a reaction to injury, stroke or tumor. In the early 1960's the use of drugs related to cortisone was introduced. These compounds have the remarkable ability to reduce brain swelling, particularly swelling related to brain tumor or to surgery itself. This beneficial effect has greatly extended the neurosurgeon's ability to intervene for the patient's benefit.

An enormous stride was made in the early 1960's with the introduction into the specialty of the operating microscope to allow magnifications ranging from 2 to 40 times the size of the structure being operated upon. It also afforded high intensity illumination. Since many neurosurgical procedures are performed within very narrow confines and on very delicate

structures, the use of magnification greatly facilitated many operative procedures. Tentatively used at first, and only in highly specialized cases, microsurgery has become an everyday event at hospitals throughout the country. The microscope is used for surgery on blood vessels within the brain, the removal of tumors, and surgery of the nerves including nerve grafts.

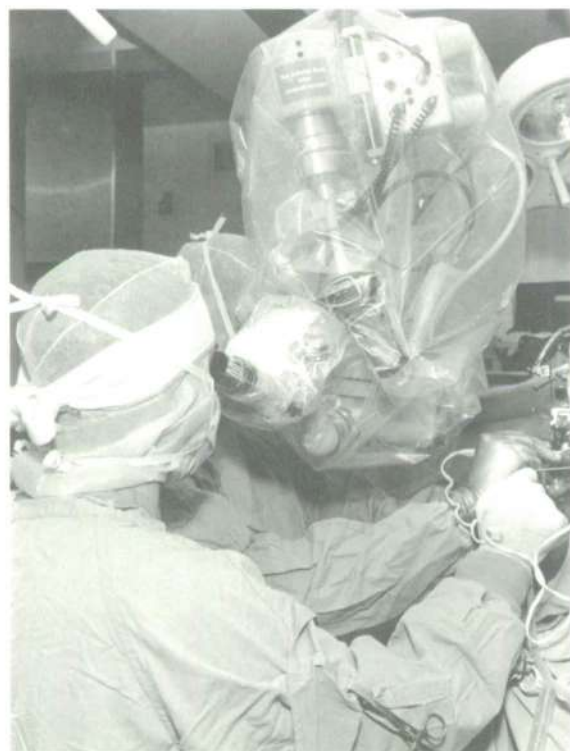

Figure 8 *Operating microscope in use, with a side-arm which allows both the surgeon and an assistant to have magnification. The plastic drape is sterile, permitting the surgeon to move it during the operation.*

Another new technological application combined with the use of the microscope has been that of the laser. The laser beam can be accurately aimed at abnormal tissue through the microscope, and this tissue can be cut or vaporized with extreme precision. New lasers are being introduced which will permit the joining of blood vessels and nerves by a process similar to spot welding of metals.

Another way to remove tough and fibrous tumors that cannot easily be cut or coagulated is the ultrasonic aspirator, a device initially introduced into medical practice for the extraction of cataracts. Because neither the laser or ultrasonic aspirator manipulates the surrounding brain, they allow much safer removal of difficult tumors.

There have been major strides in neurodiagnostic techniques by x-ray as well. For many years, accurate demonstration of tumors within the head relied on the taking of ordinary x-rays after the injecting of air into the fluid spaces of the brain or of dye into the brain arteries. These methods carried considerable pain and risk as well as being difficult to interpret. In the short time since its introduction in 1973, computed tomography (CT) has become an indispensable tool in the diagnosis of disorders of the nervous system. The CT scan provides an x-ray picture of the soft tissues and bones of the skull or spine as seen in cross section. This is done by scanning the head at many different angles with a single x-ray beam and reconstructing an image by means of a computer. The computer shows the x-ray density of thousands of individual points within the cross-sectional area of the head or spine. This allows for ready identification of all the structures of the head, both normal and abnormal. This scanning technique is more accurate and carries an extremely low risk for the patient.

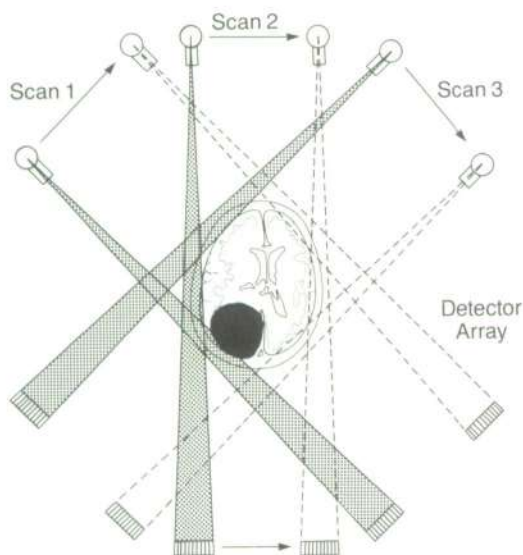


Figure 9 Schematic diagram of a CT scanner. A beam of x-ray is directed across the head, and the amount of energy absorbed by brain-structures measured by detectors. The beam rotates around the head, and a grid of crossing beams is created. The density of each of these cross-points is calculated by computer, and an image is reconstructed from this data.

A diagnostic innovation called magnetic resonance imaging (MRI) has recently been introduced. This form of scanning does not rely on x-ray, but on the principle that atomic nuclei tend to become aligned in response to a strong magnetic pulse. When the magnetic field is removed, the nuclei return to their original orientation and emit a signal which can be used to construct an image by computer. This new imaging modality reveals subtle abnormalities in the brain to an even greater degree than CT scanning. Moreover, it does not expose the patient to potential hazards of diagnostic radiation.

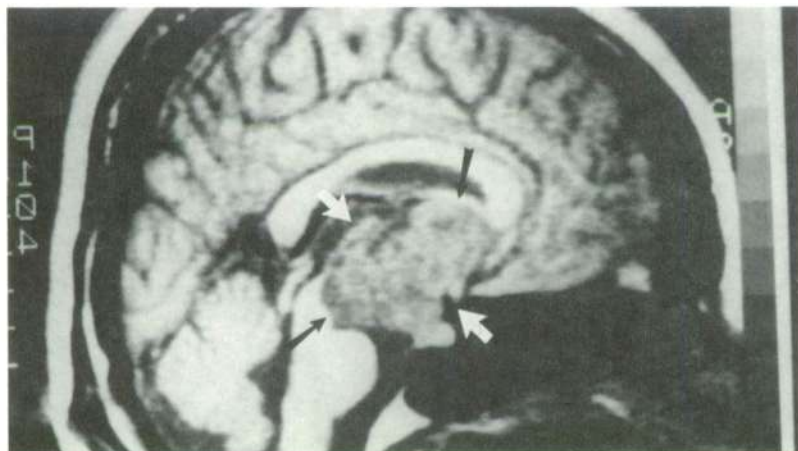


Figure 10 Magnetic resonant image (MRI scan) of the head as seen from the side. A large tumor (arrow) is seen occupying the space above the pituitary gland at the base of the brain.

The diagnostic and operative advances described are part of a dramatic and ongoing process. Neurosurgeons and neuroscientists in laboratories throughout the country are continuing the search for better understanding of the nervous system. The basic mechanisms controlling the brain and spinal cord and of the disorders that afflict them are rapidly coming to light. This new information is quickly translated into improved methods of treatment for neurosurgical patients.

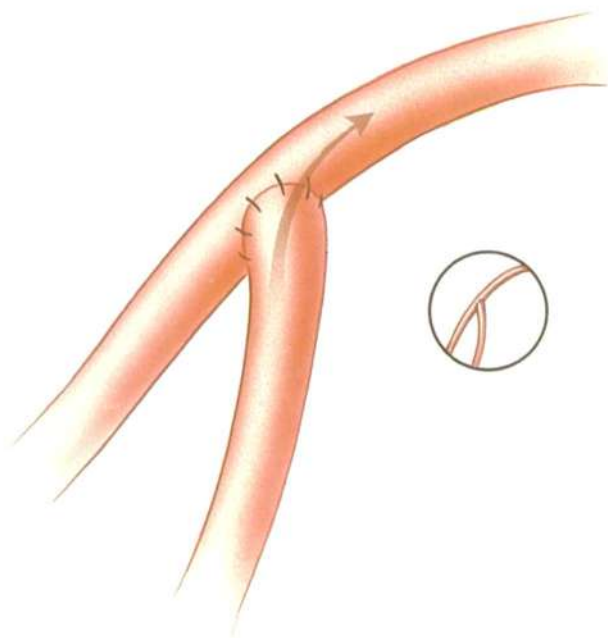


Figure 11 The operating microscope has permitted joining of arteries together to improve the flow of blood to specific brain regions. The small circle shows the vessels at approximately their normal size.

American Association of Neurological Surgeons
and
Congress of Neurological Surgeons
22 South Washington Street
Park Ridge, Illinois 60068
312/692-9500

Copyright © 1987