

# Mapping the Horizon: Techniques to Optimize Tumor Resection Before and During Surgery

*Nader Sanai, M.D., and Mitchel S. Berger, M.D.*

**A**lthough a primary tenet of neurosurgical oncology is that survival can improve with greater tumor resection, this principle must be tempered by the potential for functional loss after radical removal. Current neurosurgical innovations aim to improve our anatomical, physiological, and functional understanding of the surgical region of interest to prevent potential neurological morbidity during resection. We review current and future imaging modalities as well as state-of-the-art intraoperative techniques that can facilitate extent of resection while minimizing the associated morbidity profile.

## Physiological Imaging

Physiological imaging has emerged as one of the most important adjuncts available in neurosurgery. By transitioning from a purely anatomy-based discipline to one that incorporates functional, hemodynamic, metabolic, cellular, and cytoarchitectural alterations, the current state of neuroimaging has evolved into a comprehensive diagnostic tool that allows characterization of morphological as well as biological alterations to diagnose and grade brain tumors and to monitor and assess treatment response and patient prognosis. Among physiological imaging technologies, magnetic resonance spectroscopy (MRS) is now considered by many to be the gold standard<sup>7</sup> (*Fig. 2.1*). It is a powerful noninvasive imaging technique that offers unique metabolic information on brain tumor biology not available from anatomic imaging.

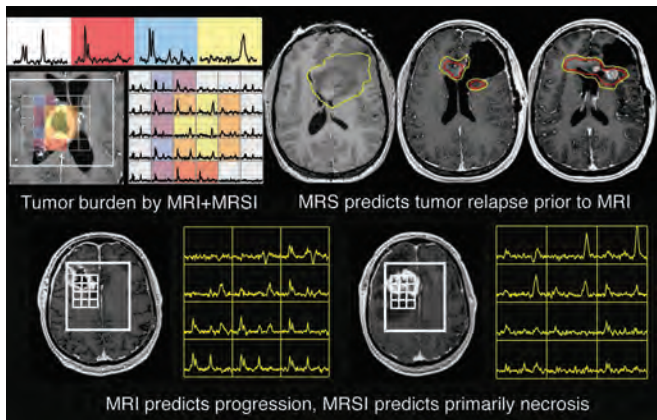
Beyond its diagnostic capabilities, MRS is becoming increasingly useful in the operating room, where imported MRS images can be integrated into the neuronavigational workstation to define the lesion not just anatomically, but in terms of the disease around it.<sup>10,26</sup> Although incorporating this technology into the surgical strategy can influence a planned extent of resection, it can also guide stereotactic biopsies for higher diagnostic yields.<sup>12</sup> The usefulness of having this information available during a brain tumor resection is clear, and there is also increasing evidence that

radiosurgical planning also benefits from physiology imaging such as MRS.<sup>8,9</sup>

Assessment of extent of resection is one of several important avenues through which MRS can potentially impact the quality of brain tumor resections. Analysis of postoperative MRS imaging demonstrates that, even when gross total resection is anticipated, neurosurgeons leave a significant amount of metabolically active tumor behind, which can be volumetrically quantified using physiological imaging. Comparisons of magnetic resonance versus MRS on postoperative imaging have demonstrated that the location and volume of residual disease varies significantly based on the choice of imaging modality. Although most of the metabolically detectable disease is contained within the T2 hyperintensity, extension of physiological imaging signal beyond the T2 hyperintense region is seen in 60 and 65% of patients without and with contrast enhancement, respectively.<sup>19</sup> This supports the concept of combining anatomical imaging with spectroscopic imaging for surgical target planning during the course of brain tumor resection.

The prognostic value of MRS imaging is becoming increasingly becoming evident as imaging findings are correlated with outcome. In several retrospective analyses, spectroscopic data appear to be powerful predictors of poor outcome.<sup>1,8,18</sup> For example, high lactate and lipid levels, indicating hypoxia and necrosis, respectively, are negative prognostic factors, as is a high choline level in addition to a large contrast-enhancing volume.<sup>24</sup> Furthermore, significantly shorter median survival times are observed for patients with a large volume of the choline-to-N-acetylaspartate index than for patients with a small index volume before tumor irradiation. Based on these investigations, both the initial tumor burden and the treated volume of the metabolic abnormality play an important role in predicting survival for patients with high-grade gliomas.

Taken together, these applications of MRS technology lead us to develop a new, more comprehensive surgical strategy for brain tumor resection. Specifically, tumors of the same histology can now be stratified based on their magnetic



**FIGURE 2.1.** MRS is the physiological imaging gold standard, correlating with tumor burden and tumor progression as well as with the extent of tumor necrosis.

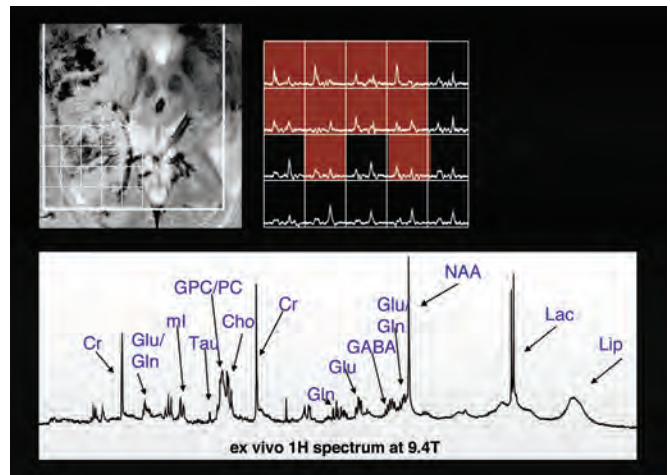
spectroscopy features. Prospectively, this approach can direct the neurosurgeon’s resection of abnormal spectroscopic areas such as regions of high lactate or lipid. Not only will this facilitate a greater anatomical extent of resection, but it will also minimize the residual of spectroscopically abnormal tissue. Using this approach, we now need to study its overall effect on patient survival and other outcome parameters.

As magnetic resonance technology evolves, the capabilities of MRS will likely expand. Current studies using 3-Tesla field strength technology are promising and suggest a level of resolution that was previously unattainable.<sup>13,25,28</sup> However, with the advent of 7-Tesla magnetic resonance imaging scanners (*Fig. 2.2*), this gain may be further enhanced. Although current applications of this technology are limited to ex vivo experimentation, these data clearly demonstrate a new capability to discern an additional level of metabolic complexity. As this approach matures, a whole set of new imaging biomarkers will likely emerge, allowing neurosurgeons to identify novel, high-value surgical targets that we may currently be neglecting.

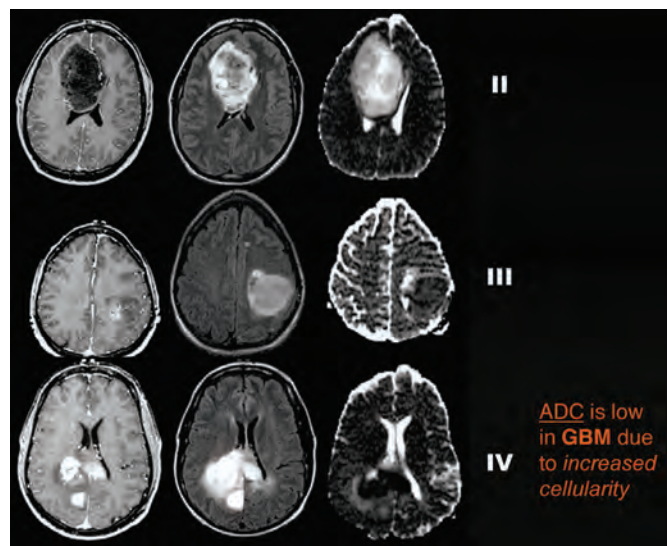
## Emerging Neuroimaging Technologies

### Apparent Diffusion Coefficient Maps

Beyond MRS technology, a number of other new physiological imaging techniques are emerging on the horizon and will be directly applicable to the operating room. This includes diffusion-weighted imaging that correlates the apparent diffusion coefficient (ADC) with brain tumors. ADC is a diffusion-weighted imaging parameter that is inversely related to cellularity and tumor infiltration (*Fig. 2.3*) such that the ADC decreases as the histologic grade increases. Histopathological evaluations show that meningiomas and brain metastases tend to be more cellular compared with gliomas because of the compact sheets of tumor cells.<sup>14</sup>



**FIGURE 2.2.** Seven-Tesla MRS can reveal an entirely new spectrum of metabolic tumor markers.



**FIGURE 2.3.** ADC maps may be predictive of relative tumor histopathological grading.

### Quantitative T2 Imaging

Quantitative T2 imaging can also provide insight into tumor cellularity and characterize tumor-related edema in ways that are not readily discernible on conventional magnetic resonance images (*Fig. 2.4*).<sup>23</sup> Studies have demonstrated that T2 relaxation times are significantly longer in the peritumoral edema regions than in the tumor for patients with meningiomas or metastases.<sup>23</sup> Long T2 relaxation times may indicate that the increased water content in the extracellular space in those regions is a result of reactive changes of the normal brain in response to the tumor. The extent of longer T2 relaxation times for vasogenic edema may be related to size of the contrast-enhancing tumor. In gliomas, the peritu-

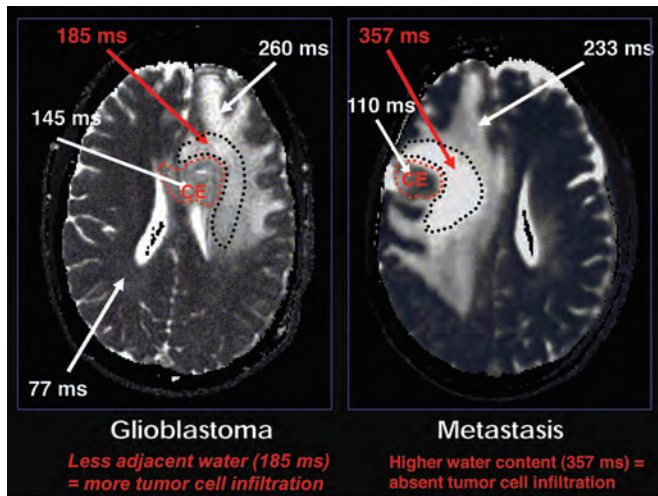


FIGURE 2.4. Quantitative T2 imaging may provide an imaging surrogate for tumor infiltration.

moral edema is known to contain both vasogenic edema and infiltrating tumor. The longer T2 relaxation times that were observed in the endemic regions for the patients with meningiomas or metastases as compared with those for patients with gliomas suggest that it may be possible to distinguish pure vasogenic edema from infiltrative tumor with use of quantitative T2 values. As we compare these quantitative T2 imaging characteristics with stereotactic biopsy histology, this modality may also prove to be a highly sensitive indicator of tumor infiltration.

**Functional Magnetic Resonance Imaging**

Functional magnetic resonance imaging (fMRI) is based on the increase in blood flow to local vasculature that accompanies neural activity in the brain. This results in a corresponding local reduction in deoxyhemoglobin, because the increase in blood flow occurs in the absence of a comparable increase in oxygen extraction. Thus, deoxyhemoglobin is used as an endogenous contrast-enhancing agent and serves as the source of the signal during functional MRI. Functional MRI results can be consistent with electrophysiology, positron emission tomography, cortical stimulation, and magneto-encephalography and is commonly used to provide pre-operative functional and structural information for neurosurgery. Cortical stimulation, which remains the gold standard, is based on local circuit disruption and best identifies areas that are essential to language processing. In contrast, functional MRI is an activation-based method that identifies all regions of the brain demonstrating activity related to a particular task regardless of whether those areas are essential or supplementary. Consequently, areas that appear negative for language when cortical stimulation is used may still demonstrate functional MRI activation, producing false-positive results. Decreased specificity may also be expected because

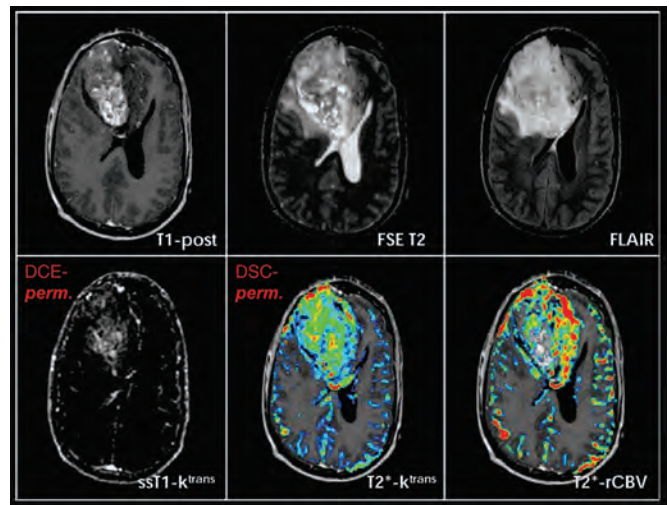


FIGURE 2.5. Magnetic resonance perfusion imaging can reveal regions of abnormal permeability and blood flow beyond the enhancing margin of the tumor.

functional MRI is a perfusion-based method and does not directly detect neuronal activity.

**Magnetic Resonance Perfusion and Cerebral Blood Volume**

Magnetic resonance techniques have also been developed for assessment of cerebral blood volume (CBV) (Fig. 2.5). A 2- to 3-minute dynamic acquisition of T2-weighted images during intravenous injection of a bolus of gadolinium-DTPA allows estimations of CBV. A voxel-by-voxel CBV map can be created by integrating the area under the dynamic contrast uptake curve and provides a relative measure of CBV with a spatial resolution of approximately  $1 \times 2 \times 5 \text{ mm}^3$  or better.

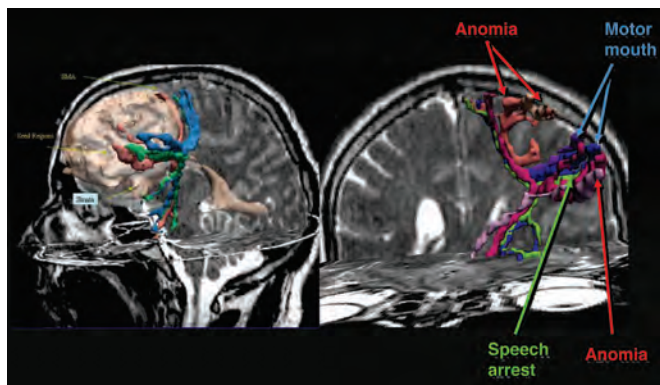
Because the vasculature plays a pivotal role in tumor growth and infiltration, particularly for gliomas, and also affects drug delivery and radiotherapy effectiveness, in vivo assessment of vascular properties in brain tumors is critical. Tumor cells often infiltrate along vascular channels and spread across midline along the commissural white matter tracts. Malignant gliomas are able to recruit and synthesize vascular networks for additional growth and proliferation. Thus, visualizing the degree of vascular proliferation is important in determining the biological aggressiveness and histopathological grading of tumors such as gliomas. Tissue oxygen content, determined by the balance between oxygen delivery and consumption, directly influences the efficacy of radiotherapy. Therefore, it is of potential value to characterize the vascularity of gliomas as well as changes in vascularity associated with therapy. In examining the permeability and blood volume profiles of many tumors, it is now possible to localize tumor extension beyond the enhancing margin of the

tumor. To date, magnetic resonance perfusion imaging and CBV have been evaluated for assessment of tumor aggressiveness, selection of biopsy location, evaluation of treatment response, and differentiation of treatment effects versus recurrent tumor.<sup>5,6</sup>

### Diffusion Tensor Imaging

Emerging neuroimaging modalities such as diffusion tensor imaging (DTI) also allow examination of specific neural components such as the integrity of white matter tracts. This technique is based on the paradigm of fractional anisotropy, which is related to diffusion-weighted imaging.<sup>2</sup> It allows, among other things, the identification of subcortical white matter tracts and a preoperative determination of their course relative to the surgical target. Although the role of DTI in preoperative planning is currently being defined, much of the published experience in this area has been limited to case reports and demonstrations in small numbers of patients.<sup>17,20–22,29,31</sup> Typically, some form of tensor directional mapping, either with or without fiber tracking, is used to depict the dislocation of a fiber tract by tumor. Some investigators have integrated DTI-based tractography with cortical mapping using functional MRI or intraoperative electrocortical stimulation using the results of cortical mapping to provide seed locations to the tractography algorithm.<sup>30</sup>

DTI-based fiber tract maps can provide confirmation that a tract in question remains intact and inform the surgeon as to the tract's location with respect to the tumor, possibly facilitating the tract's preservation at surgery.<sup>16</sup> Although intraoperative stimulation remains the gold standard for functional localization, DTI fiber tracking is now a valuable complement to invasive subcortical stimulation (*Fig. 2.6*). Using subcortical stimulation mapping to measure the accuracy of DTI fiber tracts in deep white matter, studies have confirmed that DTI fiber tracks can be used to define a safety margin around the motor tract for use in surgical planning.<sup>3</sup>



**FIGURE 2.6.** Subcortical motor tractography can play an integral role in devising surgical strategies that avoid compromising critical white matter pathways.

Currently, these data from this imaging modality can be imported into neuronavigational workstations to preoperatively identify language pathways such as the arcuate fasciculus and determine connectivity between these regions.

### Magnetoencephalography

Magnetoencephalography (MEG) has also been increasingly used for preoperative functional mapping. Compared with functional MRI and positron emission tomography, MEG has the advantage of higher temporal resolution by directly measuring neuronal activation rather than indirect hemodynamic change. Previous studies have also suggested that MEG is more accurate than functional MRI in identifying functional cortices that have been distorted by a nearby tumor.<sup>15</sup> Overall, MEG is a robust and reliable functional imaging modality that is now used to identify the cortical location of motor and sensory pathways. Integrating MEG data with DTI information into a neuronavigational workstation directs the neurosurgeon toward potential functional sites that can be intraoperatively confirmed using stimulation mapping.

Although many of the aforementioned modalities generally provide static images of neural function and physiology, future neuroimaging will focus on functional connectivity. In this respect, MEG is now evolving to measure connectivity based on the principle of imaginary coherence, which is a mathematical modeling paradigm that allows connections between cortical regions to be elucidated based on the neuro-oscillations within that cortex.<sup>11</sup> Consequently, this technology provides critical information regarding the integrity of functional connection and can prospectively identify patients with neurological deficit related to functional disconnections.

### Intraoperative Stimulation Mapping

Stimulation mapping is another very useful technique that allows for the reliable identification of both cortical and subcortical function at the time of resection. Although functional neuroimaging continues to steadily improve, cortical and subcortical stimulation mapping remains the gold standard for avoidance of motor and language pathways during any brain tumor resection. Consequently, reported morbidity profiles are very favorable when intraoperative mapping is used appropriately. For language pathways, in particular, preservation of function is of critical importance to patient quality of life. At the University of California–San Francisco, our experience with 250 consecutive patients with brain tumor who underwent intraoperative language mapping demonstrated a less than 2% likelihood of permanent language morbidity (*Fig. 2.7*). Importantly, this profile could be achieved using a “negative language mapping” paradigm, in which tailored cortical exposures without positive language site identification still allowed for aggressive resections and ultralow postoperative language morbidity.<sup>27</sup>

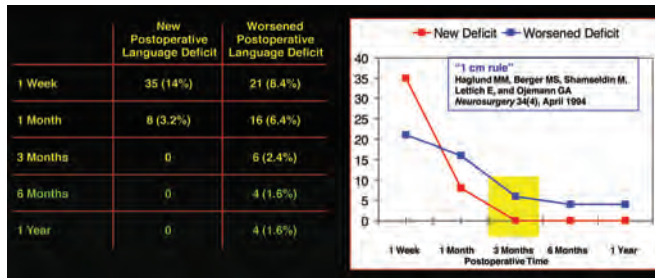


FIGURE 2.7. Negative language mapping allows tailored cortical exposures and minimal language morbidity without the need to detect positive language sites.

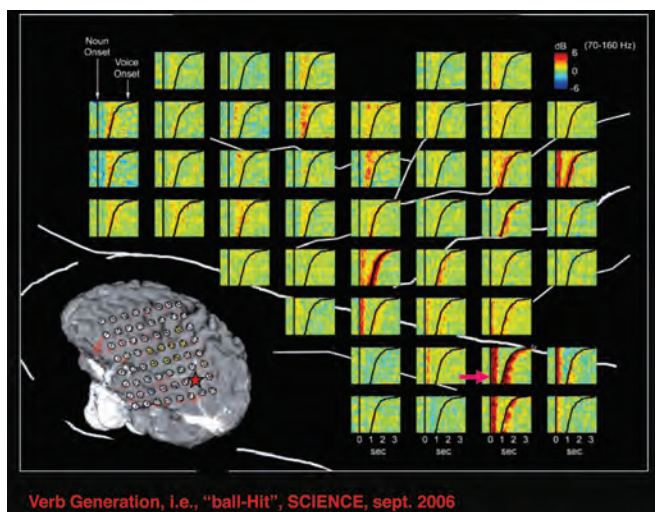


FIGURE 2.8. Verb generation tasks lead to signature high gamma activity along the involved cortex.

### Future Horizons in Detecting Neural Network Activity

The future of brain tumor surgery lies with the development of techniques that go beyond neuroimaging and cortical stimulation mapping. This will include measuring and mapping neural network activity related to particular functional paradigms and using these data to safely guide resections. For example, recent work has identified high gamma activity in the human brain during awake craniotomies as a mechanism of neural circuitry involved in verb generation (Fig. 2.8).<sup>4</sup> This technology provides a real-time, in vivo analysis of neuronal pool circuitry as well as how cortical regions relay information to one another in the setting of a specific task. Actual data such as this will likely represent the basis of future efforts to improve brain tumor surgery and minimize patient morbidity.

### CONCLUSION

Current and future state-of-the-art imaging modalities will, with increasing efficiency, delineate functional

neural networks involved in neoplastic processes and that are critical for preservation. Intraoperative integration of this data, along with advanced cortical stimulation and recording techniques, will allow the neurosurgeon to maximize tumor extent of resection while preserving patient function and quality of life. Taken together, these technical advances will form the basis of future neurosurgical strategies for brain tumor resection.

### Disclosure

The authors did not receive financial support in conjunction with the generation of this article. The authors have no personal or institutional financial interest in drugs, materials, or devices described in this article.

### REFERENCES

- Alexander A, Murtha A, Abdulkarim B, Mehta V, Wheatley M, Murray B, Riauka T, Hanson J, Fulton D, McEwan A, Roa W: Prognostic significance of serial magnetic resonance spectroscopies over the course of radiation therapy for patients with malignant glioma. *Clin Invest Med* 29:301–311, 2006.
- Alexander AL, Lee JE, Lazar M, Field AS: Diffusion tensor imaging of the brain. *Neurotherapeutics* 4:316–329, 2007.
- Berman JI, Berger MS, Chung SW, Nagarajan SS, Henry RG: Accuracy of diffusion tensor magnetic resonance imaging tractography assessed using intraoperative subcortical stimulation mapping and magnetic source imaging. *J Neurosurg* 107:488–494, 2007.
- Canolty RT, Edwards E, Dalal SS, Soltani M, Nagarajan SS, Kirsch HE, Berger MS, Barbaro NM, Knight RT: High gamma power is phase-locked to theta oscillations in human neocortex. *Science* 313:1626–1628, 2006.
- Cha S: Perfusion MR imaging: basic principles and clinical applications. *Magn Reson Imaging Clin N Am* 11:403–413, 2003.
- Cha S: Update on brain tumor imaging. *Curr Neurol Neurosci Rep* 5:169–177, 2005.
- Cha S: Update on brain tumor imaging: From anatomy to physiology. *AJNR Am J Neuroradiol* 27:475–487, 2006.
- Chan AA, Lau A, Pirzkall A, Chang SM, Verhey LJ, Larson D, McDermott MW, Dillon WP, Nelson SJ: Proton magnetic resonance spectroscopy imaging in the evaluation of patients undergoing gamma knife surgery for Grade IV glioma. *J Neurosurg* 101:467–475, 2004.
- Chuang CF, Chan AA, Larson D, Verhey LJ, McDermott M, Nelson SJ, Pirzkall A: Potential value of MR spectroscopic imaging for the radio-surgical management of patients with recurrent high-grade gliomas. *Technology in Cancer Research & Treatment* 6:375–382, 2007.
- Dowling C, Bollen AW, Noworolski SM, McDermott MW, Barbaro NM, Day MR, Henry RG, Chang SM, Dillon WP, Nelson SJ, Vigneron DB: Preoperative proton MR spectroscopic imaging of brain tumors: Correlation with histopathologic analysis of resection specimens. *AJNR Am J Neuroradiol* 22:604–612, 2001.
- Guggisberg AG, Honma SM, Findlay AM, Dalal SS, Kirsch HE, Berger MS, Nagarajan SS: Mapping functional connectivity in patients with brain lesions. *Ann Neurol* 63:193–203, 2008.
- Hall WA, Truwit CL: 1.5 T: Spectroscopy-supported brain biopsy. *Neurosurg Clin North Am* 16:165–172, vii, 2005.
- Jeun SS, Kim MC, Kim BS, Lee JM, Chung ST, Oh CH, Lee SY, Choe BY: Assessment of malignancy in gliomas by 3T 1H MR spectroscopy. *Clin Imaging* 29:10–15, 2005.
- Kono K, Inoue Y, Nakayama K, Shakudo M, Morino M, Ohata K, Wakasa K, Yamada R: The role of diffusion-weighted imaging in patients with brain tumors. *AJNR Am J Neuroradiol* 22:1081–1088, 2001.
- Korvenoja A, Kirveskari E, Aronen HJ, Avikainen S, Brander A, Huttunen J, Ilmoniemi RJ, Jaaskelainen JE, Kovala T, Makela JP, Salli E, Seppa M: Sensorimotor cortex localization: Comparison of magne-

- toencephalography, functional MR imaging, and intraoperative cortical mapping. **Radiology** 241:213–222, 2006.
16. Lazar M, Alexander AL, Thottakara PJ, Badie B, Field AS: White matter reorganization after surgical resection of brain tumors and vascular malformations. **AJNR Am J Neuroradiol** 27:1258–1271, 2006.
  17. Lo CY, Chao YP, Chou KH, Guo WY, Su JL, Lin CP: DTI-based virtual reality system for neurosurgery. **Conf Proc IEEE Eng Med Biol Soc** 2007:1326–1329, 2007.
  18. Marcus KJ, Astrakas LG, Zurakowski D, Zarifi MK, Mintzopoulos D, Poussaint TY, Anthony DC, De Girolami U, Black PM, Tarbell NJ, Tzika AA: Predicting survival of children with CNS tumors using proton magnetic resonance spectroscopic imaging biomarkers. **Int J Oncol** 30:651–657, 2007.
  19. McKnight TR, Noworolski SM, Vigneron DB, Nelson SJ: An automated technique for the quantitative assessment of 3D-MRSI data from patients with glioma. **J Magn Reson Imaging** 13:167–177, 2001.
  20. Niizuma K, Fujimura M, Kumabe T, Higano S, Tominaga T: Surgical treatment of paraventricular cavernous angioma: Fibre tracking for visualizing the corticospinal tract and determining surgical approach. **J Clin Neurosci** 13:1028–1032, 2006.
  21. Nimsky C, Ganslandt O, Hastreiter P, Wang R, Benner T, Sorensen AG, Fahlbusch R: Intraoperative diffusion-tensor MR imaging: shifting of white matter tracts during neurosurgical procedures—Initial experience. **Radiology** 234:218–225, 2005.
  22. Nimsky C, Grummich P, Sorensen AG, Fahlbusch R, Ganslandt O: Visualization of the pyramidal tract in glioma surgery by integrating diffusion tensor imaging in functional neuronavigation. **Zentralbl Neurochir** 66:133–141, 2005.
  23. Oh J, Cha S, Aiken AH, Han ET, Crane JC, Stainsby JA, Wright GA, Dillon WP, Nelson SJ: Quantitative apparent diffusion coefficients and T2 relaxation times in characterizing contrast enhancing brain tumors and regions of peritumoral edema. **J Magn Reson Imaging** 21:701–708, 2005.
  24. Oh J, Henry RG, Pirzkall A, Lu Y, Li X, Catalaa I, Chang S, Dillon WP, Nelson SJ: Survival analysis in patients with glioblastoma multiforme: Predictive value of choline-to-N-acetylaspartate index, apparent diffusion coefficient, and relative cerebral blood volume. **J Magn Reson Imaging** 19:546–554, 2004.
  25. Ozturk E, Banerjee S, Majumdar S, Nelson SJ: Partially parallel MR spectroscopic imaging of gliomas at 3T. **Conf Proc IEEE Eng Med Biol Soc** 1:493–496, 2006.
  26. Pirzkall A, Li X, Oh J, Chang S, Berger MS, Larson DA, Verhey LJ, Dillon WP, Nelson SJ: 3D MRSI for resected high-grade gliomas before RT: Tumor extent according to metabolic activity in relation to MRI. **Int J Radiat Oncol Biol Phys** 59:126–137, 2004.
  27. Sanai N, Mirzadeh Z, Berger MS: Functional outcome after language mapping for glioma resection. **N Engl J Med** 358:18–27, 2008.
  28. Sjobakk TE, Johansen R, Bathen TF, Sonnewald U, Kvistad KA, Lundgren S, Gribbestad IS: Metabolic profiling of human brain metastases using in vivo proton MR spectroscopy at 3T. **BMC Cancer** 7:141, 2007.
  29. Tummala RP, Chu RM, Liu H, Truwit CL, Hall WA: Application of diffusion tensor imaging to magnetic-resonance-guided brain tumor resection. **Pediatr Neurosurg** 39:39–43, 2003.
  30. Wu JS, Zhou LF, Tang WJ, Mao Y, Hu J, Song YY, Hong XN, Du GH: Clinical evaluation and follow-up outcome of diffusion tensor imaging-based functional neuronavigation: A prospective, controlled study in patients with gliomas involving pyramidal tracts. **Neurosurgery** 61: 935–949, 2007.
  31. Yu CS, Li KC, Xuan Y, Ji XM, Qin W: Diffusion tensor tractography in patients with cerebral tumors: A helpful technique for neurosurgical planning and postoperative assessment. **Eur J Radiol** 56:197–204, 2005.