



Posterior Cavernous Anterior Transpetrosal Posteromedial Rhomboid (Dolenc-Kawase Rhomboid)

Approach to Posterior Cavernous and Petroclival Lesions

Ashish Suri; Manjul Tripathi; Rama C. Deo; Vinkle Srivastav; Britty Baby; Tara S. Roy; Sanjeev Lalwani; Subodh Kumar;

Prem Kalra; Subhashish Banerji; Sanjiva Prasad

Dept. of Neurosurgery, All India Institute of Medical Sciences, New Delhi, India and Dept. of Computer Science Engineering, Indian Institute of Technology, Delhi, India

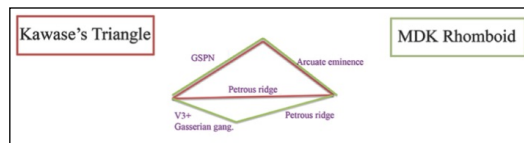


Introduction

- Traditional Kawase's approach provides a fenestration of 10x5 mm at anterior petrous apex in between V n. and IAC.
- This fenestration proves a key but conical and crowded access that does not allow proper exposure to V n. exiting from tentorium, VI n. in Dorello's canal and posterior clinoid process.
- Modified technique of interdural transcavernous dissection with extradural anterior petrosectomy facilitates medial mobilization of V n. with larger fenestration called Modified Dolenc- Kawase rhomboid approach.

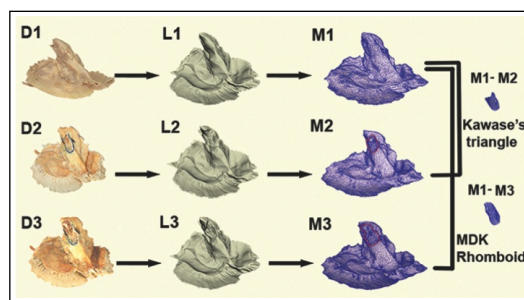
Methods

- Interdural dissection of posterior cavernous sinus wall over the V1, V2, V3 and Gasserian Ganglion (GG) permits access to MDK-rhomboid (AE-posterior, GSPN-lateral, PR-medial and V3+GG-anterior).
- Ligation and division of superior petrosal sinus at posterior clinoid process and elevation + mobilization of Vnv. permits enlarged view of previous inaccessible areas.
- Volumetric analysis with 3D laser scanning of temporal bones for respective triangles and rhomboid areas; comparing difference of exposure with modified approaches on cadaver dissection were analyzed for evaluation of area exposed, surgical freedom and angulation of approach.



Results

- MDK rhomboid approach provides 1.5X larger area and 2.0X greater volume of bone at anterior petrous apex in comparison to Kawase's triangle approach.
- Cadaver dissection objectified technical feasibility of MDK approach providing nearly 1.5 to 2 times larger fenestration with improved view and angulation to posterior cranial fossa.
- MDK rhomboid approach was used in the treatment of petroclival meningiomas (35), giant dumbbell trigeminal schwannoma (11), clival chordoma (6), clival chondrosarcoma (4), trochlear schwannoma (1), giant posterior fossa craniopharyngioma(6), middle+posterior fossa epidermoid (4), hypothalamic hamartoma (1), giant low basilar bifurcation aneurysm (2), petroclival hemangiopericytoma (1) and histiocytosis (Rosai Dorfman disease).



Learning Objectives

- Posterior cavernous anterior transpetrosal posteromedial Modified Dolenc-Kawase(MDK)-rhomboid approach is technically demanding and requires thorough knowledge of anatomy and pathology.
- MDK Rhomboid approach provides safe corridor during the microsurgical treatment of spectrum of skull base lesions.
- The larger fenestration at petrous apex provides greater surgical freedom at Dorello's canal, Gasserian ganglion and prepontine area and better anteroposterior angulation in comparison to traditional Kawase's approach.

