



**Congress of
Neurological
Surgeons**

GUIDELINES

CONGRESS OF NEUROLOGICAL SURGEONS SYSTEMATIC REVIEW AND EVIDENCE-BASED GUIDELINE ON PRIMARY MANAGEMENT OF PATIENTS WITH NONFUNCTIONING PITUITARY ADENOMAS

Sponsored by

Congress of Neurological Surgeons (CNS) and the AANS/CNS Tumor Section

Endorsed by

Joint Guidelines Committee of the American Association of Neurological Surgeons (AANS) and the Congress of Neurological Surgeons (CNS)

Joshua William Lucas, MD¹, Mary E. Bodach, MLIS², Luis M. Tumialan, MD³, Nelson M. Oyesiku, MD, PhD⁴, Chirag G. Patil, MD⁵, Zachary Litvack, MD⁶, Manish K. Aghi, MD, PhD^{7*}, Gabriel Zada, MD^{1*}

¹ Department of Neurosurgery, University of Southern California, Los Angeles, California, USA

² Guidelines Department, Congress of Neurological Surgeons, Schaumburg, Illinois, USA

³ Barrow Neurological Institute, Phoenix, Arizona, USA

⁴ Department of Neurosurgery, Emory University, Atlanta, Georgia, USA

⁵ Department of Neurosurgery, Cedars-Sinai Medical Center, Los Angeles, California, USA

⁶ Department of Neurosurgery, George Washington University, Washington, DC, USA

⁷ Department of Neurosurgery, University of California, San Francisco, California, USA

* These authors contributed equally to this work.

Correspondence:

Gabriel Zada, MD
Department of Neurosurgery
University of Southern California
1200 N State St, Suite 3300
Los Angeles, CA 90033
E-mail: gzada@usc.edu

ABSTRACT

Background: Nonfunctioning pituitary adenomas (NFPAs) are among the most common pituitary lesions and may present clinically with vision loss and hypopituitarism.

Objective: To characterize the existing literature as it pertains to the initial management of NFPAs.

Methods: A systematic literature review was conducted to identify and screen articles assessing primary treatment options (surgical, medical, radiation based, or observation) for NFPAs. Outcomes assessed included vision-, endocrine-, and headache-related symptoms, as well as tumor response to therapy. Twenty-six studies met inclusion criteria for analysis.

Results: A considerable amount of Class II evidence (14 studies) was identified supporting primary surgical intervention in patients with symptomatic NFPA macroadenomas, resulting in immediate tumor volume reduction in nearly all patients and a residual tumor rate of 10% to 36%. One prospective, observational cohort study and multiple retrospective studies showed improved visual function in 75% to 91% of surgically treated patients and improved hypopituitarism in 35% to 50% of patients. Limited Class II evidence showed inconsistent benefits for observation alone (1 study), primary radiation-based treatment (3 studies), or primary medical treatment (8 studies) for improving vision, headaches, hypopituitarism, or tumor volume. One retrospective study implementing observation alone showed tumor progression in 50% of patients and a requirement for surgery in 21% of patients. Eight studies assessing primary medical therapy for NFPAs showed inconsistent tumor response rates using somatostatin analogues (12-40% response rate), dopamine agonist therapy (0-61% response rate), or combination therapy (60% response rate). Three studies reporting primary radiosurgery for NFPAs showed decreased tumor size in 38% to 60% of patients.

Conclusion: Multiple retrospective and some prospective studies have demonstrated consistent effectiveness of primary surgical resection of symptomatic NFPAs with acceptable morbidity rates. Limited and inconsistent reports are available for alternative treatment strategies, including radiation, medical treatment, and observation alone; these modalities may, however, play a valid role in patients who are not surgical candidates. Based on the available evidence, the authors recommend surgical resection as the preferred primary intervention for symptomatic NFPAs.

RECOMMENDATION

Question

What is the consensus within the scientific literature for the primary treatment strategy for patients with symptomatic nonfunctioning pituitary adenomas?

Recommendation

Level III: Surgical resection is recommended as the primary treatment of symptomatic patients with NFPAs.

Question

What is the consensus within the scientific literature for the primary treatment strategy for patients with asymptomatic nonfunctioning pituitary adenomas?

Recommendation

There is insufficient evidence to make a recommendation for treatment versus observation of asymptomatic NFPAs.

INTRODUCTION

Rationale

The management of nonfunctioning pituitary adenomas (NFPAs) includes surgical resection, radiation therapy, medical management, or observation. Since the development and refinement of surgical approaches to the sella turcica, surgical intervention has been the preferred method of treatment in symptomatic patients. More recent developments in radiation therapy, including non-fractionated gamma knife radiosurgery, have led to alternative treatment options for NFPAs. Several studies have also investigated the role of medical management of NFPAs using various hormonal analogs. This chapter focuses on the preferred method of primary management of NFPAs based on evidence from the literature.

METHODOLOGY

Process Overview

The evidence-based clinical practice guideline task force members and the Tumor Section of the American Association of Neurological Surgeons (AANS) and the Congress of Neurological Surgeons (CNS) conducted a systematic review of the literature relevant to the management of NFPAs. Additional details of the systematic review are provided below and within the introduction and methodology chapter of the guideline.

Disclaimer of Liability

This clinical systematic review and evidence-based guideline was developed by a physician volunteer task force as an educational tool that reflects the current state of knowledge at the time of completion. The presentations are designed to provide an accurate review of the subject matter covered. This guideline is disseminated with the understanding that the recommendations by the authors and consultants who have collaborated in its development are not meant to replace the individualized care and treatment advice from a patient's physician(s). If medical advice or assistance is required, the services of a physician should be sought. The recommendations contained in this guideline may not be suitable for use in all circumstances. The choice to implement any particular recommendation contained in this guideline must be made by a managing physician in light of the situation in each particular patient and on the basis of existing resources.

Potential Conflicts of Interest

All NFPA Guideline Task Force members were required to disclose all potential COIs prior to beginning work on the guideline, using the COI disclosure form of the AANS/CNS Joint Guidelines Committee. The CNS Guidelines Committee and Guideline Task Force Chair reviewed the disclosures and either approved or disapproved the nomination and participation on the task force. The CNS Guidelines Committee and Guideline Task Force Chair may approve nominations of task force members with possible conflicts and restrict the writing, reviewing, and/or voting privileges of that person to topics that are unrelated to the possible COIs.

Literature Search

The task force collaborated with a medical librarian to search for articles published from January 1, 1966, to October 1, 2014. Authors searched 2 electronic databases, PubMed and the Cochrane Central Register of Controlled Trials. Strategies for searching electronic databases were constructed by the evidence-based clinical practice guideline taskforce members and the medical librarian using previously published search strategies to identify relevant studies (Appendix A).¹⁻⁸

RESULTS

Twenty-six studies met inclusion criteria for analysis, of which all were Class III observational studies (Table 1). A flow chart summarizing study selection can be found in Figure 1. No Class I evidence comparing any treatment modality was available. A considerable amount of Class III evidence (14 studies) was identified supporting primary surgical intervention in symptomatic patients with symptomatic NFPA macroadenomas. Limited Class III evidence was identified for NFPA patients treated with observation (2 studies), primary radiation-based treatment (3 studies), or medical treatment (8 studies). One prospective/retrospective study compared NFPA patients treated surgically with those treated with dopamine agonist therapy.

Observation of Asymptomatic NFPAs

Natural history studies implementing only observation of NFPAs alone have rarely been reported in the literature. Dekkers et al (2007), in a retrospective analysis of 28 asymptomatic patients diagnosed with NFPAs who received no treatment following diagnosis, showed that radiologic evidence of tumor growth was observed in 14 of 28 patients (50%) (Table 1). Spontaneous reduction in tumor volume was seen in 8 patients (29%). Six patients (21%) required surgical intervention due to onset of visual field deficits.⁹ Arita et al (2006) reported observation alone in the management of “incidentalomas” in 42 patients. Over the course of 4 years, 17 patients (40%) showed increase in size of the NFPA on repeat imaging. Ten patients (24%) became symptomatic and 4 patients (9.5%) developed pituitary apoplexy. Of these 42 patients, 12 (28.6%) underwent surgical intervention during the period of follow-up due to new symptoms or increasing tumor size.¹⁰ Due to the paucity of available studies, there is insufficient evidence to make a recommendation regarding the primary treatment modality for asymptomatic lesions.

Surgical Treatment

A considerable amount of Class III evidence (14 studies) was identified reporting outcomes following primary surgical intervention in symptomatic patients with symptomatic NFPA macroadenomas (Table 1). Overall, surgical resection resulted in immediate tumor volume reduction in nearly all patients and a residual tumor rate of 10%-36%. One prospective observational cohort study and multiple retrospective studies showed improved visual function in 75%-91% of surgically treated patients and improved hypopituitarism in 35%-50% of patients.¹⁰⁻²⁰

Chen et al analyzed surgical outcomes in a prospective study of 385 patients with NFPAs that underwent surgical resection. Of these patients, 242 presented with visual symptoms, and 215 (87.6%) noted improvement in visual symptoms postoperatively. Residual tumor was identified on postoperative MRI at 4 months in 79 patients (20.8%), and 8 patients (2.1%) required lifetime pituitary hormone replacement postoperatively.¹¹

Multiple retrospective analyses have reported clinical and imaging outcomes following surgical intervention for NFPAs (Table 1). Berkmann et al, in a series of 114 patients with NFPAs treated with surgical intervention at a single institution, showed that 42 of 83 patients (50.6%) presenting with preoperative hypopituitarism recovered significant pituitary function postoperatively. Additionally, of 79 patients presenting with preoperative visual field deficits, 78 (89%) demonstrated significant recovery of vision postoperatively.¹² Comtois et al described the normalization or improvement of vision in 71 of 94 patients (75%) treated with surgical intervention for NFPAs who had initially presented with visual field deficits. Permanent pituitary dysfunction was seen in 7 of 126 total patients (5%), and the recurrence rate in their series was 21% (mean follow-up time of 6.4 years).¹³ Dallapiazza et al (2014) reported a gross total resection rate of 71% in 80 patients who underwent transsphenoidal resection of NFPAs. These patients were followed for at least 5 years, with tumor recurrence seen in 7 patients (12%).¹⁴ Dekkers et al (2006) showed that in 97 patients who underwent transsphenoidal resection of NFPAs without subsequent therapeutic interventions, 10 patients (10.3%) had evidence of tumor regrowth or recurrence on follow-up MR imaging (mean follow-up time of 6 years). The authors concluded that surgical intervention alone controlled tumor in 90% of all patients with NFPAs.¹⁵

In a separate study, Dekkers et al (2007) showed that visual acuity improved significantly within 3 months of transsphenoidal surgery; however, further improvement was seen 1 year postoperatively, indicating that the beneficial effects of tumor decompression can be seen in a delayed progressive fashion.¹⁶ Fleseriu et al demonstrated the efficacy of surgical resection of NFPAs on headaches. Of 15 patients with NFPAs that initially presented with headaches, 8 of 15 (53.3%) noted complete resolution of headaches postoperatively, and 4 of 15 (26.6%) reported improvement in headaches. Only 3 of 15 patients (20%) reported no change in headaches following surgical resection.¹⁷ Kurosaki et al showed improvement of visual field deficits in 19 of 23 patients (82.6%) treated with transsphenoidal resection of NFPAs.¹⁸ Mortini et al published a series of 378 patients with NFPAs treated with surgery in which 234 (64.8%) had gross total resection of tumor. In this series, 117 (40.5%) of the 289 patients with visual defects had normalization of vision, and another 148 patients (51.2%) showed improvement in vision postoperatively.¹⁹ Petruson et al published an early series of 48 patients with NFPAs treated with surgical resection. CT scans performed at an average of 4 years postoperatively in 44 patients revealed no signs of recurrent tumor in any patient. New hypopituitarism was evident in 6 of 48 patients (12%) postoperatively.²⁰ Webb et al attempted to characterize the effects of surgical intervention for NFPAs on the postoperative endocrine status of patients. A retrospective analysis of 56 patients with NFPAs showed 24 (42.8%) with complete hormonal axis function postoperatively. Of the 56 patients, 3 (5%) developed new postoperative pituitary axis dysfunction. Some element of pituitary dysfunction was present preoperatively in 29 patients, and 19 of 29 (65%) had no change in function postoperatively, whereas 10 of 29 (35%) gained some function after surgery.²¹ This is contrasted by a report for Wichers-Rother et al, which retrospectively analyzed 155 patients with NFPAs treated with operative intervention and determined that anterior pituitary function did not significantly improve postoperatively.²²

Ocular motility problems are commonly seen with patients presenting with pituitary apoplexy but less commonly in the absence of a bleed.²³ Studies of pituitary patients who have suffered apoplexy have produced contradictory advice as to the role of surgical decompression, with 2 Class III studies favoring surgery,²⁴ while another Class III study suggested observation may be as effective.²³

The complication rate of surgical intervention has been demonstrated to be low. Halvorsen et al, in a retrospective analysis of 446 transsphenoidal procedures for NFPAs, describes a total complication rate of 7.1%. The most common complications included CSF leak (4.7%), meningitis (2.0%), and visual deterioration (2.0%).²⁵

Radiation Therapy and Radiosurgery

Radiation therapy and radiosurgery has been firmly established as a secondary treatment modality in patients with recurrent or residual tumor. Assessment of the efficacy of radiation therapy in the primary treatment of NFPAs is sparse. In a retrospective analysis of 100 patients with NFPAs treated with Gamma Knife radiosurgery (GKS), 8 patients were treated with GKS as primary treatment. Of these 8 patients, 3 patients (38%) demonstrated decrease in tumor size on follow-up imaging, whereas 5 patients (62%) showed stable tumor size.²⁶ Park et al published a retrospective analysis of 15 patients treated with GKS as a primary treatment. Of these patients, 9 (60%) demonstrated tumor size reduction on follow-up imaging and 4 (26.7%) showed no change. Two patients (13.3%) showed progression in tumor size.²⁷ Lee et al published a series of 41 patients in which radiosurgery was performed as primary treatment due to high surgical risk.

The tumor control rates at 5 and 10 years were 94% and 85%, respectively. Three patients required surgical intervention after initial treatment with radiation despite high-risk status. New onset cranial nerve deficit was noted in 1 patient.²⁸

Medical Therapy

Evidence supporting consistent effective treatment of NFPAs with medical therapy alone is also sparse and inconsistent. Despite their inherent lack of hormonal functionality, the primary medical agents that have been assessed in NFPAs are dopamine agonist and somatostatin analogue agents. In a prospective observational study by Nobels et al, 8 patients with NFPAs were treated with quinagolide, a dopamine receptor agonist, and followed for more than 48 months. Of those 8 patients, 2 (25%) showed tumor shrinkage, whereas 6 (75%) showed an increase in tumor size of greater than 10%.²⁹ Chakera et al attempted single-agent bromocriptine therapy in 5 patients with NFPAs, with no patients demonstrating any reduction in tumor size on serial CT scans.³⁰ Van Schaardenburg et al reported the results of a prospective cohort study of 43 patients with NFPAs to assess efficacy of medical treatment with bromocriptine. Fifteen patients without prior history of surgery or radiation were treated with bromocriptine therapy, while 18 patients were treated with surgery alone. In the bromocriptine group, 3 patients of 15 (20%) showed tumor growth while 12 of 15 (80%) showed no changes on serial CT imaging. Visual field deficits worsened in 1 of the patients who had no change on CT imaging.³¹ Verde et al treated 20 patients with NFPAs using bromocriptine and serially assessed them via serial CT imaging and ophthalmologic examinations. One patient of 20 (5%) demonstrated a marked reduction in tumor size and improvement in visual fields. The remaining 19 patients (95%) showed no changes on imaging during treatment, and 4 of these patients required neurosurgical intervention for worsening visual deficits.³²

Attempts have also been made to characterize the receptors for certain molecules present on NFPAs and differentiating the response to different medical therapies targeting these receptors. De Herder et al attempted to show differential response of NFPAs to dopamine agonist therapy based on uptake of ¹²³I-epidepride, a D2 receptor agonist. NFPA stabilization or shrinkage with dopamine agonist therapy showed no significant difference between those NFPAs graded as 0, 1, or 2 on the scale of dopamine uptake on their grading scale.³³

With regard to somatostatin-analogue therapy for NFPAs, Gasperi et al assessed the effect of single-agent octreotide therapy in patients with NFPAs. After 6 months of therapy, no significant change in visual fields or tumor size was seen in 7 of 8 patients (88%), whereas 1 patient (12%) demonstrated improvement in visual fields and decreased tumor size.³⁴ Warnet et al followed 24 patients with NFPAs and visual changes treated with octreotide. Visual improvement was noted in 9 of 22 patients (40.9%) at 2 months; however, octreotide was stopped in 13 of 22 patients (59.1%) due to inefficacy.³⁵

Combination medical therapy represents yet another avenue for treating NFPAs that is also lacking a strong evidence basis. In a prospective observational trial of 10 patients with NFPAs given a combination of octreotide and somatostatin for 6 months of therapy, Anderson et al found that 40% of patients showed stable or increased size of tumor, whereas 60% showed decrease in size. Those with decrease in tumor volume had tumors that demonstrated in vivo secretory potential.³⁶

DISCUSSION

The treatment of NFPAs with surgical intervention has long been considered the primary treatment modality in symptomatic patients able to undergo surgery. The development of transsphenoidal and transcranial approaches to the sellar region has allowed for direct tumor decompression and rapid symptomatic relief with low complication rates in most series. The historical tendency to perform surgical resection first in these patients inherently limits the amount of Class I evidence available, as surgical resection has not been directly compared to either medical intervention, observation, or radiation-based therapy as primary intervention techniques in randomized controlled trials.

A large amount of Class III evidence supporting the use of surgical intervention as the primary treatment method for NFPAs exists in the literature. Most studies have been retrospective observational analyses of large series of surgical patients with a few prospective observational studies identified for surgical, medical, and observation treatment strategies alone.

Based on the available evidence, surgical management is the preferred method of primary treatment of symptomatic NFPAs with symptoms of visual field deficit or visual loss, ophthalmoplegia, compression of the optic apparatus on MRI, endocrinologic dysfunction including hypopituitarism or stalk effect causing hyperprolactinemia, pituitary apoplexy, refractory headaches not attributable to other headache syndromes, or other neurologic deficits related to compression from the tumor. A decision to treat asymptomatic, incidentally discovered NFPAs is a separate question for which there was insufficient evidence to make a recommendation. Numerous retrospective analyses highlight the efficacy of surgical resection in the improvement of vision and pituitary endocrine function in symptomatic NFPAs. No studies were found that directly compare primary treatment of NFPAs with surgical resection vs radiation therapy or medical therapy in a randomized, controlled fashion, likely because surgical intervention has been the mainstay of treatment for several decades.

Studies of radiation therapy as a primary treatment method have not shown superiority or equivalence to surgical resection of NFPAs. Radiation therapy has been shown to be an effective adjunct to surgical resection in the case of postoperative residual tumor or recurrence. Radiation therapy may also have a role in primary management of patients that are unfit for surgical intervention based on severe medical comorbidities or preoperative functional status. Primary radiation-based treatment in patients with NFPAs has not been adequately assessed in published series in which patients have clinical equipoise between surgical and nonsurgical treatments. Although there remains a possibility that radiosurgery may play a valid role in the primary treatment of NFPAs, there is limited and inconsistent data available to currently support this treatment strategy, and the risk of tumor progression and radiation-induced hypopituitarism are major disincentives.

Similarly, medical therapy has not been proven effective in the primary management of NFPAs. Neither the use of dopamine agonists nor somatostatin analogs, whether alone or in combination, have been shown to have a significant and consistent therapeutic effect on these tumors. A strategy of observation alone showed tumor progression in over half of patients, with over 20% requiring surgery as a result of progressive clinical symptoms.

Limitations and Future Research

The current study is limited by its systematic review methodology, which is inherently susceptible to various sources of bias, including publication, selection, and information bias. Similarly, the recommendations made are based on Class III evidence, without any prospective, randomized, controlled trial data available to truly compare efficacy of the treatment modalities in question (Table 1). Nevertheless, the results of this review highlight the existing evidence available, showing a dearth of observational data supporting the primary role of surgical resection in the treatment of symptomatic NFPAs. Future research may be directed toward primary treatment of NFPAs in patients who are unable to undergo surgical intervention based on medical comorbidities, a subset of patients in which the current literature is limited.

Conclusion

Based on the available evidence, surgical management is the preferred method of primary treatment of symptomatic NFPAs in patients with symptoms of visual field deficit or visual loss, ophthalmoplegia, compression of the optic apparatus on MRI, endocrine dysfunction, including hypopituitarism or stalk effect causing hyperprolactinemia, pituitary apoplexy, refractory headaches not attributable to other headache syndromes, or other neurologic deficits related to compression from the tumor, when compared to radiation, medical therapies, or observation alone as primary treatment strategies. Limited and inconsistent reports are available for alternative treatment strategies, including radiation, medical treatment, or observation alone; these modalities may, however, play a valid role in patients who are not surgical candidates.

Disclosure of Funding

These evidence-based clinical practice guidelines were funded exclusively by the CNS and the Tumor Section of the CNS and the AANS, which received no funding from outside commercial sources to support the development of this document.

Acknowledgments

The authors acknowledge the CNS Guidelines Committee for their contributions throughout the development of the guideline, the AANS/CNS Joint Guidelines Committee for their review, comments, and suggestions throughout peer review, and Pamela Shaw, MSLIS, MS, for assistance with the literature searches. Also, the authors acknowledge the following individual peer reviewers for their contributions: Sepideh Amin-Hanjani, MD, Kathryn Holloway, MD, Odette Harris, MD, Brad Zacharia, MD, Daniel Hoh, MD, Isabelle Germano, MD, Martina Stippler, MD, Kimon Bekelis, MD, Christopher Winfree, MD and William Mack, MD. Lastly, and most significantly, the authors would like to acknowledge Edward Laws, MD, for serving as an advisor on this nonfunctioning adenoma guidelines project and providing comprehensive critical appraisal.

Disclosures

The authors have no personal, financial, or institutional interest in any of the drugs, materials, or devices described in this article.

REFERENCES

1. Kastner M, Wilczynski NL, Walker-Dilks C, McKibbin KA, Haynes B. Age-specific search strategies for Medline. *J. Med. Internet Res.* 2006;8(4):e25.
2. Haynes RB, McKibbin KA, Wilczynski NL, Walter SD, Werre SR, Hedges T. Optimal search strategies for retrieving scientifically strong studies of treatment from Medline: analytical survey. *BMJ.* 2005;330(7501):1179.
3. Montori VM, Wilczynski NL, Morgan D, Haynes RB, Hedges T. Optimal search strategies for retrieving systematic reviews from Medline: analytical survey. *BMJ.* 2005;330(7482):68.
4. Wong SS, Wilczynski NL, Haynes RB. Comparison of top-performing search strategies for detecting clinically sound treatment studies and systematic reviews in MEDLINE and EMBASE. *Journal of the Medical Library Association : JMLA.* 2006;94(4):451-455.
5. Zhang L, Ajiferuke I, Sampson M. Optimizing search strategies to identify randomized controlled trials in MEDLINE. *BMC Med. Res. Methodol.* 2006;6:23.
6. Topfer LA, Parada A, Menon D, Noorani H, Perras C, Serra-Prat M. Comparison of literature searches on quality and costs for health technology assessment using the MEDLINE and EMBASE databases. *Int. J. Technol. Assess. Health Care.* 1999;15(2):297-303.
7. Wilczynski NL, Haynes RB. Developing optimal search strategies for detecting clinically sound prognostic studies in MEDLINE: an analytic survey. *BMC Med.* 2004;2:23.
8. Wilczynski NL, Haynes RB, Hedges T. EMBASE search strategies achieved high sensitivity and specificity for retrieving methodologically sound systematic reviews. *J. Clin. Epidemiol.* 2007;60(1):29-33.
9. Dekkers OM, Hammer S, de Keizer RJ, et al. The natural course of non-functioning pituitary macroadenomas. *Eur. J. Endocrinol.* 2007;156(2):217-224.
10. Arita K, Tominaga A, Sugiyama K, et al. Natural course of incidentally found nonfunctioning pituitary adenoma, with special reference to pituitary apoplexy during follow-up examination. *J. Neurosurg.* 2006;104(6):884-891.
11. Chen L, White WL, Spetzler RF, Xu B. A prospective study of nonfunctioning pituitary adenomas: presentation, management, and clinical outcome. *J. Neurooncol.* 2011;102(1):129-138.
12. Berkmann S, Fandino J, Muller B, Kothbauer KF, Henzen C, Landolt H. Pituitary surgery: experience from a large network in Central Switzerland. *Swiss Med. Wkly.* 2012;142:w13680.
13. Comtois R, Beauregard H, Somma M, Serri O, Aris-Jilwan N, Hardy J. The clinical and endocrine outcome to trans-sphenoidal microsurgery of nonsecreting pituitary adenomas. *Cancer.* 1991;68(4):860-866.

14. Dallapiazza RF, Grober Y, Starke RM, Laws ER, Jr., Jane JA, Jr. Long-term Results of Endonasal Endoscopic Transsphenoidal Resection of Nonfunctioning Pituitary Macroadenomas. *Neurosurgery*. 2015;76(1):42-52; discussion 52-3.
15. Dekkers OM, Pereira AM, Roelfsema F, et al. Observation alone after transsphenoidal surgery for nonfunctioning pituitary macroadenoma. *J. Clin. Endocrinol. Metab.* 2006;91(5):1796-1801.
16. Dekkers OM, de Keizer RJ, Roelfsema F, et al. Progressive improvement of impaired visual acuity during the first year after transsphenoidal surgery for non-functioning pituitary macroadenoma. *Pituitary*. 2007;10(1):61-65.
17. Fleseriu M, Yedinak C, Campbell C, Delashaw JB. Significant headache improvement after transsphenoidal surgery in patients with small sellar lesions. *J. Neurosurg.* 2009;110(2):354-358.
18. Kurosaki M, Ludecke DK, Flitsch J, Saeger W. Surgical treatment of clinically nonsecreting pituitary adenomas in elderly patients. *Neurosurgery*. 2000;47(4):843-848; discussion 848-849.
19. Mortini P, Losa M, Barzagli R, Boari N, Giovanelli M. Results of transsphenoidal surgery in a large series of patients with pituitary adenoma. *Neurosurgery*. 2005;56(6):1222-1233; discussion 1233.
20. Petruson B, Jakobsson KE, Elfverson J, Bengtsson BA. Five-year follow-up of nonsecreting pituitary adenomas. *Arch. Otolaryngol. Head Neck Surg.* 1995;121(3):317-322.
21. Webb SM, Rigla M, Wagner A, Oliver B, Bartumeus F. Recovery of hypopituitarism after neurosurgical treatment of pituitary adenomas. *J. Clin. Endocrinol. Metab.* 1999;84(10):3696-3700.
22. Wichers-Rother M, Hoven S, Kristof RA, Bliesener N, Stoffel-Wagner B. Non-functioning pituitary adenomas: endocrinological and clinical outcome after transsphenoidal and transcranial surgery. *Exp. Clin. Endocrinol. Diabetes.* 2004;112(6):323-327.
23. Lubina A, Olchovsky D, Berezin M, Ram Z, Hadani M, Shimon I. Management of pituitary apoplexy: clinical experience with 40 patients. *Acta Neurochir. (Wien.)*. 2005;147(2):151-157; discussion 157.
24. Vargas G, Gonzalez B, Guinto G, et al. Pituitary Apoplexy in Non-Functioning Pituitary Macroadenomas: A Case-Control Study. *Endocrine practice : official journal of the American College of Endocrinology and the American Association of Clinical Endocrinologists*. 2014:1-19.
25. Halvorsen H, Ramm-Pettersen J, Josefsen R, et al. Surgical complications after transsphenoidal microscopic and endoscopic surgery for pituitary adenoma: a consecutive series of 506 procedures. *Acta Neurochir. (Wien.)*. 2014;156(3):441-449.
26. Mingione V, Yen CP, Vance ML, et al. Gamma surgery in the treatment of nonsecretory pituitary macroadenoma. *J. Neurosurg.* 2006;104(6):876-883.

27. Park KJ, Kano H, Parry PV, et al. Long-term outcomes after gamma knife stereotactic radiosurgery for nonfunctional pituitary adenomas. *Neurosurgery*. 2011;69(6):1188-1199.
28. Lee CC, Kano H, Yang HC, et al. Initial Gamma Knife radiosurgery for nonfunctioning pituitary adenomas. *J. Neurosurg*. 2014;120(3):647-654.
29. Nobels FR, de Herder WW, van den Brink WM, et al. Long-term treatment with the dopamine agonist quinagolide of patients with clinically non-functioning pituitary adenoma. *Eur. J. Endocrinol*. 2000;143(5):615-621.
30. Chakera TM, Khangure MS, Pullen P. Assessment by computed tomography of the response of pituitary macroadenomas to bromocriptine. *Clin. Radiol*. 1985;36(3):223-226.
31. van Schaardenburg D, Roelfsema F, van Seters AP, Vielvoye GJ. Bromocriptine therapy for non-functioning pituitary adenoma. *Clin. Endocrinol. (Oxf)*. 1989;30(5):475-484.
32. Verde G, Oppizzi G, Chiodini PG, Dallabonzana D, Luccarelli G, Liuzzi A. Effect of chronic bromocriptine administration on tumor size in patients with "nonsecreting" pituitary adenomas. *J. Endocrinol. Invest*. 1985;8(2):113-115.
33. de Herder WW, Reijs AE, Feelders RA, et al. Dopamine agonist therapy of clinically non-functioning pituitary macroadenomas. Is there a role for 123I-epidepride dopamine D2 receptor imaging? *Eur. J. Endocrinol*. 2006;155(5):717-723.
34. Gasperi M, Petrini L, Pilosu R, et al. Octreotide treatment does not affect the size of most non-functioning pituitary adenomas. *J. Endocrinol. Invest*. 1993;16(7):541-543.
35. Warnet A, Harris AG, Renard E, Martin D, James-Deidier A, Chaumet-Riffaud P. A prospective multicenter trial of octreotide in 24 patients with visual defects caused by nonfunctioning and gonadotropin-secreting pituitary adenomas. French Multicenter Octreotide Study Group. *Neurosurgery*. 1997;41(4):786-795; discussion 796-787.
36. Andersen M, Bjerre P, Schroder HD, et al. In vivo secretory potential and the effect of combination therapy with octreotide and cabergoline in patients with clinically non-functioning pituitary adenomas. *Clin. Endocrinol. (Oxf)*. 2001;54(1):23-30.

FIGURES

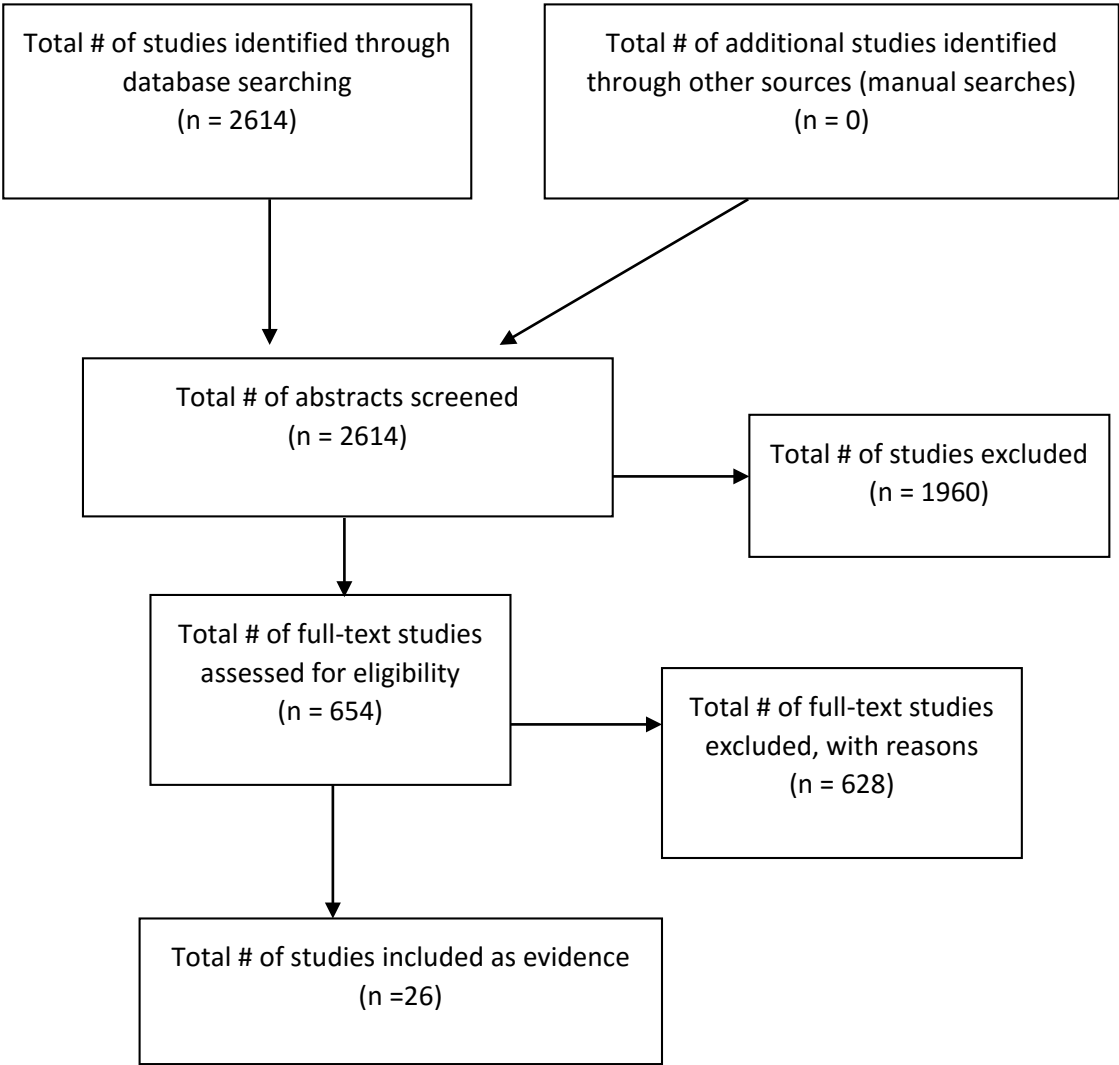


Figure 1: Article Flow Chart

TABLES

Table 1

Author (Year)	Description of Study	Classification Process / Data Class	Conclusions
Andersen et al (2001) ³⁶	Prospective observational study of 10 patients with NFPAs. Patients were analyzed with in vivo secretory capacity testing. They were then given the combination of a somatostatin analog, octreotide, and a D2 agonist for 6 months of therapy.	Therapeutic / III	Three of 10 patients (30%) demonstrated no change in tumor size, 1 of 10 (10%) demonstrated increased size, and 6 of 10 (60%) demonstrated reduced size. A reduction in tumor volume (mean 30%) was recorded only in patients with in vivo secretory potential.
Arita et al (2006) ¹⁰	A prospective observational trial at a single institution of 42 patients with asymptomatic NFPAs that were observed without any other intervention.	Therapeutic / III	Over 4 years of follow-up, incidentally found tumors increased in size in 40% of patients. Symptoms were noted in 10 patients (20%) during follow-up, 4 (9.5%) of whom developed pituitary apoplexy. Twelve patients underwent surgical intervention either due to symptoms or increasing tumor size.
Berkmann et al (2012) ¹²	A retrospective observational study at a single institution in Switzerland. A total of 182 patients who underwent surgical intervention for pituitary lesions were included. One hundred fourteen of 182 patients (63%) had NFPAs. Postoperative recovery of pituitary function and vision were assessed.	Therapeutic / III	Of 114 patients with NFPAs, 83 presented with preoperative hypopituitarism. Forty-two of these 83 patients (50.6%) recovered significant pituitary function postoperatively. Additionally, 88 patients presented with preoperative visual field deficits. Of these 88 patients, 78 (89%) demonstrated significant recovery of vision postoperatively.

Author (Year)	Description of Study	Classification Process / Data Class	Conclusions
Chakera et al (1985) ³⁰	Prospective observational study of 11 patients with macroadenomas. Five of these patients had NFPAs. All patients were given a course of bromocriptine therapy.	Therapeutic / III	Zero of 5 patients with NFPAs treated with bromocriptine showed any change in tumor size on follow-up CT scans.
Chen et al (2011) ¹¹	A prospective observational study of 385 patients with NFPAs who underwent surgical intervention for resection of tumor. Resolution of visual complaints and symptoms of hypopituitarism were analyzed.	Therapeutic / III	Of 385 patients who underwent endoscope-assisted transsphenoidal resection of tumor, 242 had complained of visual symptoms preoperatively. Of these patients, 215 (87.6%) noted improvement in visual symptoms postoperatively. Eight patients (2.1%) required lifetime hormone replacement therapy postoperatively. Residual tumors were found in 79 patients (20.8%) on 4-month postoperative MRI.
Comtois et al (1991) ¹³	Retrospective analysis of 126 patients with NFPAs who underwent transsphenoidal resection at a single institution.	Therapeutic / III	After surgery, vision was normalized or improved in 71 of 94 patients (75%) who had presented with visual field deficits. Permanent diabetes insipidus occurred in 5% (7 of 126). The recurrence rate (mean follow up time of 6.4 +/- 4.2 years) was 21%.

Author (Year)	Description of Study	Classification Process / Data Class	Conclusions
Dallapiazza, Grober et al (2014) ¹⁴	Retrospective analysis of 80 patients who underwent endoscopic resection of NFPA's who had more than 5 years of follow-up.	Therapeutic / III	Gross total resection was achieved in 71% of patients. There were 7 (12%) recurrences within the group, occurring at a mean time of 53 months postoperatively. Rates of endoscopic resection were comparable compared to published rates via microsurgical techniques.
de Herder et al (2006) ³³	Prospective cohort study of patients with NFPA's and response to dopamine. Pituitary uptake of 123I-epidepride was classified on scale of 0 to 3 (high uptake). Patients were then given DA agonist therapy and response classified according to follow-up imaging.	Therapeutic / III	NFPA stabilization or shrinkage with DA agonist therapy showed no significant difference between grade 0, 1, and 2 tumors. There is limited clinical utility of dopamine D2 receptor imaging for predicting efficacy of DA agonist therapy. Eleven of 18 patients (61%) showed shrinkage of tumor >20%.
Dekkers et al (2006) ¹⁵	Retrospective study of 109 consecutive patients with NFPA's who underwent transsphenoidal surgery between 1992 and 2004. Ninety-seven patients received surgery as the only therapeutic intervention. Mean follow-up period of 6.0 ± 3.7 years.	Therapeutic / III	Of 97 patients who underwent transsphenoidal resection without subsequent therapeutic interventions, 9 patients had evidence of tumor regrowth, and recurrence was noted in 1 patient. Mean follow-up time was 6.0 ± 3.7 years. The mean time to tumor regrowth/recurrence was 6.9 years. Authors concluded that transsphenoidal surgery without subsequent radiation therapy controlled tumor in 90% of all patients.

Author (Year)	Description of Study	Classification Process / Data Class	Conclusions
Dekkers, de Keizer et al (2007) ¹⁶	Retrospective follow-up study of 43 consecutive patients treated with transsphenoidal resection of NFPAs. Analysis was primarily to assess for continuing improvement in visual acuity following surgical intervention.	Therapeutic / III	Visual acuity improved significantly within 3 months after transsphenoidal surgery, from 0.65 ± 0.37 to 0.75 ± 0.36 ($P < .01$) (right eye), and from 0.60 ± 0.32 to 0.82 ± 0.30 ($P < .01$) (left eye). Further improvement was seen at 1 year following surgical intervention, as the mean visual acuity increased from 0.75 ± 0.36 to 0.82 ± 0.34 ($P < 0.05$) (right eye) and from 0.82 ± 0.30 to 0.88 ± 0.27 ($P < 0.05$) (left eye).
Dekkers, Hammer et al (2007) ⁹	Retrospective analysis of 28 patients diagnosed with NFPAs who had no treatment following diagnosis. Mean duration of follow-up was 118 months.	Therapeutic / III	Radiologic evidence of tumor growth was observed in 14 of 28 patients (50%). Six patients (21%) required operation due to onset of visual field deficits. Spontaneous reduction in tumor volume was observed in 8 patients (29%).
Fleseriu et al (2009) ¹⁷	Retrospective analysis of 41 patients who underwent surgical intervention for pituitary adenoma. All patients presented with complaint of headache. Analysis was focused on effects of surgical intervention on resolution of headache.	Therapeutic / III	Of 41 patients with pituitary adenoma in this study, 15 (36.6%) had documented NFPAs. No patient was on hormone replacement. Eight of 15 patients (53.3%) reported complete resolution of headaches postoperatively, 4 of 15 (26.6%) reported improvement in headaches, and 3 of 15 (20%) reported no change in headaches.
Gasperi et al (1993) ³⁴	Prospective observational study of 8 patients with NFPAs treated for 6 months with octreotide therapy. Tumor size assessed at follow-up with CT scan.	Therapeutic / III	No significant change in visual field or tumor size occurred after octreotide therapy in 7 of 8 patients (88%), whereas 1 patient (12%) demonstrated improvement in visual fields and decreased tumor size.

Author (Year)	Description of Study	Classification Process / Data Class	Conclusions
Halvorsen et al (2014) ²⁵	Retrospective study of all (506) transsphenoidal procedures performed on 446 patients in a defined population, analyzing complication rates specifically.	Therapeutic / III	The overall complication rate was 7.1%, with the most common complications being CSF leak (4.7%), meningitis (2%), and visual deterioration (2%). No difference was observed between endoscopic and microsurgical resection.
Kurosaki et al (2000) ¹⁸	Retrospective analysis of 32 cases of NFPAs in patients greater than 70 years of age identified in a review of 982 patients with pituitary adenomas treated at a single institution.	Therapeutic / III	All 32 patients underwent transsphenoidal resection of the tumor. Complete microscopic resection was achieved in 24 patients, and subtotal resection in 8 cases. No severe complications were encountered. Hormonal deficiencies persisted in all patients with preoperative insufficiencies. Visual disturbances were improved for 19 of 23 patients (82.6%).
Lee et al (2014) ²⁸	Retrospective analysis of 41 patients in which NFPAs were initially treated with gamma knife radiosurgery because of high surgical risk.	Therapeutic / III	Forty-one patients underwent gamma knife radiosurgery as primary treatment for their NFPA. The tumor control rates were 94% and 85% at 5 and 10 years after treatment, respectively. Three patients underwent surgical resection post-procedurally. New onset cranial nerve palsy was noted in 1 patient.

Author (Year)	Description of Study	Classification Process / Data Class	Conclusions
Mingione et al (2006) ²⁶	Retrospective analysis of 100 consecutive patients who underwent gamma knife radiosurgery for NFPAs. Eight patients were treated with GKS as primary treatment. Mean follow-up time of 49 months.	Therapeutic / III	Of 8 patients with NFPAs treated with gamma knife radiosurgery as primary treatment, 3 (38%) demonstrated decrease in size of tumor on follow-up imaging, while 5 (62%) showed stable tumor size.
Mortini et al (2005) ¹⁹	Retrospective analysis of 1140 patients undergoing transphenoidal resection of pituitary adenoma at a single institution.	Therapeutic / III	NFPAs accounted for 378 patients (33.2% of total patients). No residual adenoma was present in 234 patients (64.8%). Normalization of visual defects occurred in 117 (40.5%) of the 289 patients with visual disturbances and improved in another 148 patients (51.2%).
Nobels et al (2000) ²⁹	Prospective observational study of 10 patients with NFPAs treated with quinagolide. Median treatment duration was 57 months. Imaging was done at regular intervals of follow-up.	Therapeutic / III	Of 8 patients with follow-up greater than 48 months, tumor shrinkage was seen in 2 (25%). Six of 8 patients (75%) showed an increase in tumor size of >10%.

Author (Year)	Description of Study	Classification Process / Data Class	Conclusions
Park et al (2011) ²⁷	Retrospective study of 125 patients with NFPAs treated with GKS over 22 years at a single institution. Fifteen of 125 patients had GKS as the primary treatment. Radiologic progression-free survival was used as primary analysis. Patients must have had >2 years of follow-up.	Therapeutic / III	Of 15 patients treated with primary GKS, 9 (60%) showed size reduction on follow-up imaging and 4 (26.7%) showed no change. Two patients demonstrated tumor progression, 1 at 14 months and 1 at 30 months postoperatively. Tumor control rate in this group was therefore 86.7%. Total tumor control rate for all patients combined (primary treatment, residual, and recurrent) was 89.6%.
Peterson et al (1995) ²⁰	Retrospective analysis of 48 patients with NFPAs treated with transsphenoidal resection at a single institution. Follow-up was done at the 5-year postoperative interval.	Therapeutic / III	CT scans were performed in 44 patients after an average of 4 years and revealed no signs of recurrent tumor in any patient. New pituitary hormonal insufficiencies developed in 6 of 48 (12%). Improvement in vision was seen in 38 patients (79%).
Van Schaardenburg et al (1989) ³¹	Prospective cohort study of 43 patients with NFPAs. Twenty-five patients were treated with bromocriptine therapy, while 18 patients were treated with surgery alone. The medically treated group was analyzed retrospectively. Fifteen of the 25 patients treated with bromocriptine had no history of surgery or radiation.	Therapeutic / III	In the 15 patients treated primarily with bromocriptine, 3 (20%) showed tumor growth while 12 (80%) showed no changes on follow-up CT scan. Visual fields worsened in one of these patients, who demonstrated no change on CT.

Author (Year)	Description of Study	Classification Process / Data Class	Conclusions
Verde et al (1985) ³²	Prospective observational analysis of 20 patients with NFPAAs treated with bromocriptine. Patients were followed with CT scans and ophthalmologic evaluations.	Therapeutic / III	One patient of 20 (5%) demonstrated a marked reduction in tumor size and improvement in visual fields. The remaining 19 patients (95%) showed no changes on imaging during treatment. Four of these patients had worsening visual fields and were referred for neurosurgery.
Warnet et al (1997) ³⁵	Twenty-four patients with visual changes caused by histologically confirmed NFPAAs were given octreotide. Visual symptoms were assessed at 4 days, 1 month, and 2 months. Patients who did not experience changes in visual symptoms were able to discontinue use of octreotide. Tumor size was also assessed at 2 months in individuals who did not discontinue octreotide due to inefficacy.	Therapeutic / III	Visual improvement was noted in 9 of 22 patients (40.9%) at 2 months. Octreotide was stopped in 13 of 22 patients (59.1%) due to inefficacy. Of those who continued taking octreotide, 3 patients demonstrated reduction in tumor size, 3 showed stable tumor size, and 1 had tumor growth.

Author (Year)	Description of Study	Classification Process / Data Class	Conclusions
Webb et al (1999) ²¹	Retrospective analysis of 234 patients with pituitary adenomas treated with transsphenoidal resection. Preoperative and postoperative (within 6 months) anterior pituitary function was evaluated for recovery or development of new deficits.	Therapeutic / III	Of 56 patients with NFPAs, 24 had complete hormonal axis function preoperatively. Three of 56 patients (5%) developed new postoperative pituitary axis dysfunction. Twenty-four of 56 patients (43%) had normal function preoperatively, and 30 of 56 (54%) had completely normal function postoperatively. Twenty-nine patients had some element of dysfunction preoperatively. Nineteen of 29 (65%) had no change in function postoperatively, whereas 10 of 29 (35%) gained some function.
Wichers-Rother et al (2004) ²²	Retrospective analysis of 155 patients with NFPA to evaluate improvement of anterior pituitary function after transsphenoidal and/or transcranial surgery. Patients were evaluated preoperatively and 3 months, 1 year, and 2 years postoperatively.	Therapeutic / III	Anterior pituitary function in patients with NFPAs did not improve significantly postoperatively. Most clinical symptoms, including visual deficits, headache, and fatigue did show improvement.

APPENDIX A

Search Strategies

Pubmed

Surgical Resection

1. (("Pituitary Neoplasms/surgery"[Majr] AND "Adenoma"[Mesh]) OR "Sella Turcica/surgery"[Majr] OR "Adenoma, Chromophobe/surgery"[Majr])
2. (microadenoma* OR adenoma* OR macroadenoma* OR incidentaloma* OR chromophobe*[Title/Abstract]) AND (pituitary OR hypophyse* OR sellar[Title/Abstract])
3. (1 or 2) AND ((asymptomatic* OR nonfunction* OR non-function* OR nonsecret* OR non-secret* OR inactive OR null OR inert OR silent)
4. NOT Comment[pt] NOT Letter[pt]
5. Limits: English and Humans, publication date to 10/01/2014

Medical Therapy

1. (("Pituitary Neoplasms"[Majr] AND Adenoma[Mesh]) OR ("Adenoma, Chromophobe"[Majr] OR "Sella Turcica"[Majr]))
2. (microadenoma* OR adenoma* OR macroadenoma* OR incidentaloma* OR chromophobe*[Title/Abstract]) AND (pituitary OR hypophyse* OR sellar[Title/Abstract])
3. (1 or 2) AND (asymptomatic* OR nonfunction* OR non-function* OR nonsecret* OR non-secret* OR inactive OR null OR inert OR silent)
4. 3 AND (("Bromocriptine/administration and dosage"[Mesh] OR "Bromocriptine/pharmacology"[Mesh] OR "Bromocriptine/therapeutic use"[Mesh]) OR ("Dopamine Agonists/administration and dosage"[Mesh] OR "Dopamine Agonists/pharmacology"[Mesh] OR "Dopamine Agonists/therapeutic use"[Mesh]) OR ("Adrenal Cortex Hormones/administration and dosage"[Mesh] OR "Adrenal Cortex Hormones/pharmacology"[Mesh] OR "Adrenal Cortex Hormones/therapeutic use"[Mesh]) OR ("Octreotide/administration and dosage"[Mesh] OR "Octreotide/pharmacology"[Mesh] OR "Octreotide/therapeutic use"[Mesh]) OR ("Dexamethasone/administration and dosage"[Mesh] OR "Dexamethasone/pharmacology"[Mesh] OR "Dexamethasone/therapeutic use"[Mesh]))
5. NOT Comment[pt] NOT Letter[pt]
6. Limit to English, Humans, publication date to 10/01/2014

Radiation Therapy

1. (("Pituitary Neoplasms/radiotherapy"[Majr] AND Adenoma[Mesh]) OR "Adenoma, Chromophobe/radiotherapy"[Majr] OR "Sella Turcica"[Majr])
2. (microadenoma* OR adenoma* OR macroadenoma* OR incidentaloma* OR chromophobe*[Title/Abstract]) AND (pituitary OR hypophyse* OR sellar[Title/Abstract])
3. (1 or 2) AND (asymptomatic* OR nonfunction* OR non-function* OR nonsecret* OR non-secret* OR inactive OR null OR inert OR silent)
4. 3 AND (radiosurgery[mesh] OR radiotherapy[mesh] OR "gamma knife" OR cyberknife OR "brainlab" OR "brain lab" OR "proton beam")
5. NOT Comment[pt] NOT Letter[pt]

Limit to English, Humans, publication date to 10/01/2014

Cochrane

1. MeSH descriptor Pituitary Neoplasms
2. MeSH descriptor Adenoma
3. 1 and 2
4. ((pituitary OR hypophyse* OR sellar) NEAR/4 (microadenoma* OR adenoma* OR macroadenoma* OR incidentaloma* or chromophobe*)):ti,ab,kw
5. 3 or 4 and (asymptomatic* OR nonfunction* OR non-function* OR nonsecret* OR non-secret* OR inactive OR null OR inert OR silent)