

# Immediate Flow Disruption as a Prognostic Factor after Flow Diverter Treatment: Introduction of a Novel Scoring System Based on Long-term Experiences with the Pipeline Embolization Device

Philippe Dodier MD; Josa Maria Frischer MD, PhD; Wei-te Wang MD; Engelbert Knosp MD; Gerhard BAVINZSKI  
 Department of Neurosurgery, Medical University Vienna, Austria

## Introduction

The flow-diverting Pipeline Embolization Device is still a young but promising device. Only few studies have addressed the challenging intra-operative decision-making process to determine the necessary per-aneurysm number of devices. The authors report long-term results after PED implantation, comprehensively characterize complex and standard aneurysms and introduce a modified flow disruption score.

## Methods

The authors reviewed a consecutive series of 40 patients treated with 54 successfully deployed PEDs. Aneurysm complexity was assessed using our proposed classification. Immediate angiographic results were analyzed using previously published grading scales and our novel flow disruption score. Longterm follow-up was available for 36 patients with a mean follow-up time of 18 months.

## Results

Forty-six aneurysms were classified as complex according to our new definition. The majority of interventions were performed in paraophthalmic and cavernous ICA segments. Excellent neurological outcome (mRS 0 and 1) was observed in 94% of patients. Our data demonstrate low permanent procedure-related mortality (0%) and morbidity rates (3%). The long-term angiographic follow-up showed complete occlusion in 81% and near total obliteration in further 14%. All standard aneurysms with one-year-follow-up, achieved complete obliteration after deployment of a single PED.

The new BD score significantly demonstrated a predictive value among complex aneurysms: All aneurysms with a high BD score showed complete occlusion at follow-up irrespective of PED number. Among complex cases treated with a single device, a third of patients, all of them diagnosed with a low BD score, failed to show complete occlusion at follow-up.

## Conclusions

Our data suggest that treatment with the Pipeline Embolization Device should be recognized as a primary management strategy for a highly selected cohort of predominantly complex intracranial aneurysms. We further show that a priori assessment of aneurysm complexity and our new post-interventional angiographic flow disruption score predict the occlusion probability and may help to determine the adequate number of per-aneurysm devices.

## References

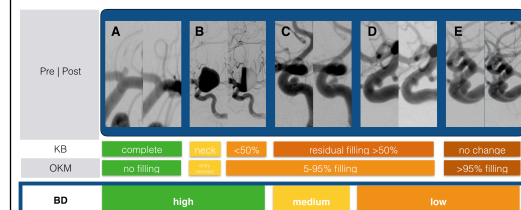
1. Kamran M, Yarnold J, Grunwald IQ, Byrne JV. Assessment of angiographic outcomes after flow diversion treatment of intracranial aneurysms: a new grading schema. *Neuroradiology*. Springer-Verlag; 2010 Sep 14;53(7):501–8.
2. O'Kelly CJ, Krings T, Fiorella D, Marotta TR. A novel grading scale for the angiographic assessment of intracranial aneurysms treated using flow diverting stents. *Interv Neuroradiol*. 2010 Jun;16(2):133–7.
3. Hanel RA, Spetzler RF. Surgical treatment of complex intracranial aneurysms. *Neurosurgery*. 2008 Jun;62(6 Suppl 3):1289–97–discussion1297–9.
4. Andaluz N, Zuccarello M. Treatment Strategies for Complex Intracranial Aneurysms: Review of a 12-Year Experience at the University of Cincinnati. *Skull Base*. 2011 Jun 21;21(04):233–42.

### Adapted Classification of Aneurysm Complexity

	Standard	Complex
<b>Size</b>	Small Large if neck-to-dome >1.6	Giant (>25mm) <sup>A</sup> Large if neck-to-dome <1.6 <sup>C</sup>
<b>Neck</b>	Small necked	Broad necked <sup>B</sup>
<b>Configuration</b>	Saccular Unilobular	Fusiform, dysmorphic <sup>C</sup> Multilobular <sup>C</sup> Parent artery or branches incorporated <sup>B</sup>
<b>Wall structure</b>	-	Intraluminal thrombus <sup>A</sup> Calcification of aneurysmal wall <sup>A</sup>
<b>Multiplicity</b>	Single aneurysm	Multiple Aneurysms in same or adjacent segment <sup>C</sup>
<b>Previous treatment(s)</b>	None	Previous <sup>A</sup> or failed <sup>C</sup> treatments of target aneurysm
<b>Example</b>		

This table combines commonly recognized features of aneurysm complexity according to Hanel et al. (A), Andaluz et al. (B) with our proposed criteria for complex aneurysms (C)

### Flow Disruption Scores



Pre- and postoperative working projections of 5 exemplary PED implantations demonstrating different degrees of the device's immediate impact on flow disruption (A: Carotid T left, B-E: paraophthalmic ICA). Below 3 corresponding grading scores of post-interventional flow-diversion are shown. The Kamran–Byrne (KB) scale, the O'Kelley-Krings-Marotta scale (OKM) are depicted as previously published. We introduce our new Bavinzski-Dodier flow disruption score (BD score) which has been inspired by and modified from previously published scores.