

Radiosurgery for Cavernous Malformations: Theory and Practice

Bruce E. Pollock, M.D.

Stereotactic radiosurgery is the precise delivery of a therapeutically effective radiation dose to an imaging-defined target. Over the past 5 decades, stereotactic radiosurgery has undergone significant advances that have improved patient outcomes and made it a critical part of modern neurosurgical practice and training. A review of the history of radiosurgery clearly shows a parallel between the development of new imaging technologies and indications for this technique. The first patients treated with radiosurgery had their dose planning based on cerebral angiography or skull radiographs, so the majority of patients in this first phase had arteriovenous malformations (AVMs), tumors adjacent to cranial base landmarks such as the sella, or trigeminal neuralgia with the gasserian ganglion being the target.¹⁷ With the advent of computed tomography and magnetic resonance imaging (MRI), the potential use of radiosurgery for both intra- and extra-axial tumors expanded greatly since they could be stereotactically defined.

Cavernous malformations (CMs) are vascular lesions that comprise the majority of angiographically occult vascular malformations diagnosed in the modern neuroimaging era. Although seen on cerebral angiography, CMs have a typical appearance on MRI that has permitted a better understanding of their incidence and natural history. Cavernous malformations may present with bleeding, seizures, or as incidental findings. Surgical resection of CMs is the preferred management for patients with symptomatic lesions.^{23,27} Resection of CMs allows clot removal, improvement in seizures, and protection against future intracranial hemorrhage (ICH).

Radiosurgery has been performed as an option for a select group of patients with CMs.^{1,3,6,8,9,12–15,21} The traditional indication for CM radiosurgery is a patient with a history of multiple ICHs from a surgically inaccessible lesion (*Fig. 11.1*). Despite its clinical use for more than 2 decades, CM radiosurgery remains controversial.

Rationale for Cavernous Malformation Radiosurgery

Radiosurgery is well established as a management option for patients with small- to moderate-sized AVMs. After

a latency interval of 1 to 5 years, the majority of patients having AVM radiosurgery go on to complete angiographic obliteration and a near-complete elimination of future ICH risk. Sequential histopathological changes after AVM radiosurgery include early damage to the endothelial cells followed by progressive thickening of the intimal layer secondary to proliferation of smooth muscle cells, which produce an extracellular matrix, then cellular degeneration, and hyaline transformation.²⁵ Studies have documented that the chance of obliteration relates primarily to the radiation dose delivered.^{4,11} Although some early papers suggested that radiosurgery increased the risk of bleeding during the latency interval, more detailed analyses of this question have confirmed that the risk of bleeding is either unchanged²⁰ or decreased^{10,18} after AVM radiosurgery.

The goal of performing CM radiosurgery is the same as AVM radiosurgery: to protect the patient from the future risk of ICH. Undoubtedly, the positive results noted after AVM radiosurgery lead to the radiosurgical treatment of a small number of patients with CMs. As discussed earlier, patients having CM radiosurgery typically had deeply located malformations and a documented history of multiple bleeds. The effect that radiosurgery has on the endothelial lined channels is poorly understood as a result of the small number of analyzed lesions. Gewirtz et al. examined 11 occult vascular malformations that were resected 1 to 10 years after either radiation therapy or radiosurgery and compared them histopathologically with a group of nonirradiated control subjects.⁵ Fibrinoid necrosis was the only pathological finding unique to the irradiated lesions; all the irradiated lesions had patent vascular channels. Importantly, 10 of these patients had recurrent bleeding after radiosurgery and were considered failures, so they may not be representative of the “successful” patients with CM after radiosurgery. Karlsson et al. presented a patient having CM radiosurgery and the lesion was unchanged on MRI 5 years later.⁹ Histological study revealed that more than 75% of the lesion was obliterated. More recently, Nyáry et al. analyzed a CM from a patient who had undergone fractionated radiation therapy (40 Gy) 1 year earlier.¹⁹ This CM exhibited endothelial cell destruction, marked fibrosis with hyaline degeneration, and scar tissue

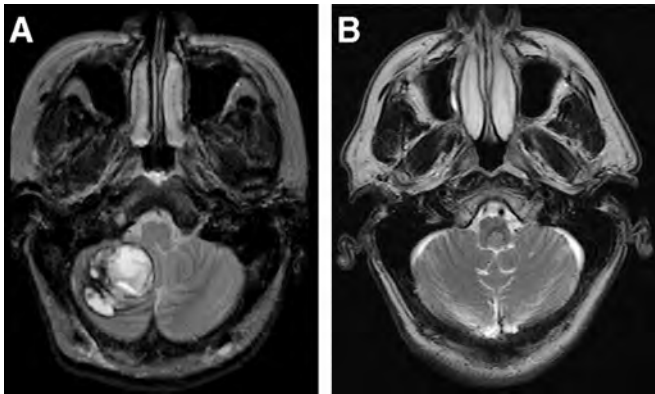


FIGURE 11.1. Axial T2-weighted MRIs of two patients referred for radiosurgery that were not acceptable candidates. *A*, A 29-year-old woman with acute onset of headache and ataxia. MRI shows a right cerebellar hemorrhage from a cavernous malformation. The patient was symptomatic from this surgically accessible lesion and resection was performed without incident. *B*, A 72-year-old man with dizziness. MRI shows cavernous malformation on the floor of the fourth ventricle. Without a history of hemorrhage, observation was recommended.

formation. Many vessels were obliterated; however, there was a large number of newly formed thin-walled channels. Overall, it appears that radiosurgery induces a similar response in CMs that has been observed in subtotally obliterated AVMs, although the number of specimens examined to date remains small.

Results of Cavernous Malformation Radiosurgery

A number of studies have outlined the effect of CM radiosurgery on hemorrhage rates and the risk of radiation-related complications.^{1,3,6,8,9,12–15,21} Hasegawa et al. from the University of Pittsburgh reported 82 patients having CM radiosurgery from 1987 to 2000.⁶ The mean follow-up after radiosurgery was 5 years. The annual hemorrhage rate was 12.3% for the first 2 years after radiosurgery and then 0.8% thereafter. Kida and Hasegawa reported outcomes for 152 patients undergoing CM radiosurgery.¹² Bleeding after radiosurgery occurred in 20 patients (13%). The hemorrhage rate was 8% the first year after radiosurgery, 5% the second year, reducing to 0% by Year 7. Other smaller series have documented annual hemorrhage rates from 4.5 to 9.4% for the first several years after radiosurgery, then lower bleeding rates in later years of follow-up.

An important issue associated with CM radiosurgery is the risk of radiation-related complications (*Fig. 11.2*). The reported rate of permanent radiation-related complications after CM radiosurgery ranges from 0 to 41%.^{1,3,6,8,9,12–15,21} Karlsson et al. reported 22 patients having radiosurgery for CMs.⁹ Overall, six patients (27%) developed radiation-rela-

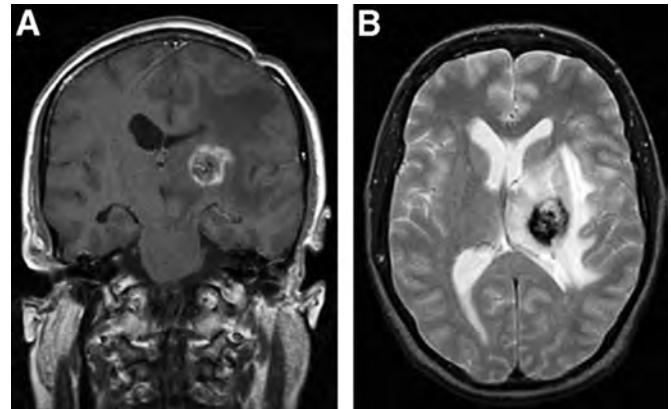


FIGURE 11.2. MRI was performed 11 months after radiosurgery of a left thalamic cavernous malformation (margin dose, 18 Gy; maximum dose, 30 Gy; volume 1.0 cc). *A*, Coronal postgadolinium study showing area of enhancement larger than the irradiated volume. *B*, Axial T2-weighted MRI showing extensive edema and mass effect.

tion complications; in five patients, the neurologic deficits were permanent. The marginal radiation dose and central location were predictors of radiation-related problems. The number of complications was greater than predicted for a similar group of patients with AVM. Amin-Hanjabi et al. found a 16% incidence of permanent radiation complications in 98 patients undergoing proton beam therapy between 1977 and 1993.¹ Radiation-induced damage was the cause of death for three patients (3%). In our series of 17 patients, 10 patients (59%) had delayed radiation-related complications; seven patients (41%) sustained a permanent neurologic deficit.²¹ Notably, 12 of 17 patients received a marginal radiation dose below the recommendations of Kondziolka et al.¹⁴ Patients in our small series were more likely to have a radiation-related complications compared with a cohort of patients with AVM managed with radiosurgery over the same time interval. Factors felt to be related to the increased complication rate observed after CM radiosurgery include use of imaging techniques other than MRI for dose planning, targeting the hemosiderin-stained brain rather than the nidus itself, and a radiation-sensitizing effect of iron.

Assessing Cavernous Malformation Radiosurgery

Hemorrhage Protection

It is difficult to accurately assess the efficacy of CM radiosurgery on the subsequent risk of ICH for two primary reasons. First, unlike AVM radiosurgery in which obliteration can be confirmed with angiography, CMs often do not change appearance on MRI after radiosurgery and it is the clinical course of the patient that is followed to determine whether radiosurgery has reduced either their risk of bleeding or new neurological events. Second, the natural history of these

lesions remains poorly understood.^{2,16,22} The most typical statistical method used to determine the effect that radiosurgery has had on bleeding risk is to compare the hemorrhage rate for patients in the period leading up to radiosurgery with the hemorrhage rate observed after radiosurgery. However, because patients tend to be treated shortly after they have bled, this methodology may artificially inflate the annual risk of bleeding. Moreover, observations that untreated CMs tend to bleed in “clusters” followed by more quiescent periods creates doubt that radiosurgery has any effect on hemorrhage risk for these patients.² As stated by Karlsson et al.,⁹ “The 32 percent incidence of hemorrhage before radiosurgery reported in another paper is more a reflection of the timing of the treatment than the natural course of the disease.” To reconcile this issue, a prospective, randomized trial comparing radiosurgery against conservative therapy for patients with hemorrhagic, surgically high-risk CMs is needed to accurately determine the true effect that CM radiosurgery has on hemorrhage risk for these patients. Such a study was once proposed but was not completed as a result of methodological considerations.

Seizure Protection

One of the early observations made on CM radiosurgery was that treated patients appeared to have fewer seizures after the procedure. Régis et al. retrospectively reviewed the experience of five centers to evaluate the efficacy of CM radiosurgery on epilepsy control.²⁴ A total of 49 patients were identified with long-lasting (mean duration of seizures before radiosurgery, 7.5 yr) drug-resistant epilepsy. The mean CM margin dose was 19.2 Gy. At a mean follow-up of 24 months, 26 patients (53%) were seizure-free. The medial temporal region was associated with the greatest risk of failure. They concluded that seizure control can be achieved when there is a clear electroclinical correlation between the CM location and the epileptogenic zone. Two studies have compared seizure control for patients with CM having radiosurgery or surgical excision. Shih and Pan compared 46 patients with solitary supratentorial CMs having craniotomy and excision ($n = 16$) with patients having radiosurgery ($n = 30$).²⁶ Seventy-nine percent (11 of 14 patients) of the craniotomy group remained seizure-free compared with 25% (four of 16 patients) in the radiosurgery group ($P < 0.01$). Likewise, Hsu et al. found that 13 of 15 patients (87%) were seizure-free after CM resection compared with nine of 14 patients (64%) treated with linear accelerator-based radiosurgery.⁷ Consequently, whenever technically possible, surgical resection should be considered the first option for patients with CM having epilepsy associated with their lesion.

CONCLUSION

Our limited knowledge on the natural history of untreated CMs combined with the relative high risk associated

with CM radiosurgery precludes one from recommending its use except for very highly selected patients. Surgical resection of CMs should continue to be the primary management strategy whenever this can be accomplished with acceptable morbidity.

Disclosure

The authors did not receive financial support in conjunction with the generation of this article. The authors have no personal or institutional financial interest in drugs, materials, or devices described in this article.

REFERENCES

1. Amin-Hanjabi S, Ogilvy CS, Candia GJ, Lyons S, Chapman PH: Stereotactic radiosurgery for cavernous malformations: Kjellberg's experience with proton beam therapy in 98 cases at the Harvard cyclotron. *Neurosurgery* 42:1229–1238, 1998.
2. Barker FG II, Amin-Hanjabi S, Butler WE, Lyons S, Ojemann RG, Chapman PH, Ogilvy CS: Temporal clustering of hemorrhages from untreated cavernous malformations of the central nervous system. *Neurosurgery* 49:15–25, 2001.
3. Chang SD, Levy RP, Adler JR Jr, Martin DP, Krakovitz PR, Steinberg GK: Stereotactic radiosurgery of angiographically occult vascular malformations: 14-year experience. *Neurosurgery* 43:213–221, 1998.
4. Flickinger JC, Pollock BE, Kondziolka D, Lunsford LD: A dose-response analysis of arteriovenous malformation obliteration by radiosurgery. *Int J Radiat Oncol Biol Phys* 36:873–879, 1996.
5. Gewirtz RJ, Steinberg GK, Crowley R, Levy RP: Pathological changes in surgically resected angiographically occult vascular malformations after radiation. *Neurosurgery* 42:738–743, 1998.
6. Hasegawa T, McInerney J, Kondziolka D, Lee JY, Flickinger JC, Lunsford LD: Long-term results after stereotactic radiosurgery for patients with cavernous malformations. *Neurosurgery* 50:1190–1197, 2002.
7. Hsu P, Chang C, Tseng C, Wei K, Wang C, Chuang C, Huang Y: Treatment of epileptic cavernomas: Surgery versus radiosurgery. *Cerebrovasc Dis* 24:116–120, 2007.
8. Huang Y, Tseng C, Chang C, Wei K, Liao C, Hsu P: LINAC radiosurgery for intracranial cavernous malformation: 10-year experience. *Clin Neurol Neurosurg* 108:750–756, 2006.
9. Karlsson B, Kihlström L, Lindquist C, Ericson K, Steiner L: Radiosurgery for cavernous malformations. *J Neurosurg* 88:293–297, 1998.
10. Karlsson B, Lax I, Söderman M: Risk of hemorrhage during the 2-year latency period following gamma knife radiosurgery for arteriovenous malformations. *Int J Radiat Oncol Biol Phys* 49:1045–1051, 2001.
11. Karlsson B, Lindquist C, Steiner L: Prediction of obliteration after gamma knife surgery for cerebral arteriovenous malformations. *Neurosurgery* 40:425–431, 1997.
12. Kida Y, Hasegawa T: Radiosurgery for cavernous malformations: Results of long-term follow-up, in Kondziolka D (ed): *Radiosurgery*. Basel, Karger, 2004, pp 153–160.
13. Kim DG, Choe WJ, Paek SH, Chung HT, Kim IH, Han DH: Radiosurgery of intracranial cavernous malformations. *Acta Neurochir* 144: 869–878, 2002.
14. Kondziolka D, Lunsford D, Coffey R, Bissonette DJ, Flickinger JC: Stereotactic radiosurgery of angiographically occult vascular malformations: Indications and preliminary experience. *Neurosurgery* 27:892–900, 1990.
15. Kondziolka D, Lunsford D, Flickinger J, Kestle J: Reduction of hemorrhage risk after stereotactic radiosurgery for cavernous malformations. *J Neurosurg* 83:825–831, 1995.
16. Kondziolka D, Lunsford D, Kestle J: The prospective natural history of cerebral cavernous malformations. *J Neurosurg* 83:820–824, 1995.
17. Leksell L: Stereotactic radiosurgery. *J Neurol Neurosurg Psychiatry* 46:797–803, 1983.

18. Maruyama K, Kawahara N, Shin M, Tago M, Kishimoto J, Kurita H, Kawamoto S, Morita A, Kirino T: The risk of hemorrhage after radiosurgery for cerebral arteriovenous malformations. *N Engl J Med* 352:146–153, 2005.
19. Nyáry I, Major O, Hanzély Z, Szeifert G: Pathological considerations to irradiation of cavernous malformations, in Szeifert G, Kondziolka D, Levivier M, Lunsford LD (eds): *Radiosurgery and Pathological Fundamentals: Prog Neurol Surg*. Basel, Karger, vol 20, pp 231–234.
20. Pollock BE, Flickinger JC, Lunsford LD, Bissonette DJ, Kondziolka D: Hemorrhage risk after stereotactic radiosurgery of cerebral arteriovenous malformations. *Neurosurgery* 38:652–661, 1996.
21. Pollock BE, Garces YI, Stafford SL, Foote RL, Schomberg PJ, Link ML: Stereotactic radiosurgery of cavernous malformations. *J Neurosurg* 93:987–991, 2000.
22. Porter PJ, Willinsky RA, Harper W, Wallace MC: Cerebral cavernous malformations: Natural history and prognosis after clinical deterioration with or without hemorrhage. *J Neurosurg* 87:190–197, 1997.
23. Porter RW, Detwiler PW, Spetzler RF, Lawton MT, Baskin JJ, Derksen PT, Zabramski JM: Cavernous malformations of the brainstem: Experience with 100 patients. *J Neurosurg* 90:50–58, 1999.
24. Regis J, Bartolomei F, Kida Y, Kobayashi T, Vladyka V, Liscak R, Forster D, Kemeny A, Schrottner O, Pendl G: Radiosurgery for epilepsy associated with cavernous malformation: Retrospective study in 49 patients. *Neurosurgery* 47:1091–1097, 2000.
25. Schneider BF, Eberhard DA, Steiner LE: Histopathology of arteriovenous malformations after gamma knife radiosurgery. *J Neurosurg* 87:352–357, 1997.
26. Shih Y, Pan DH: Management of supratentorial cavernous malformations: Craniotomy versus gamma knife surgery. *Clin Neurol Neurosurg* 107:108–112, 2005.
27. Steinberg GK, Chang SD, Gewirtz RJ, Lopez JR: Microsurgical resection of brainstem, thalamic, and basal ganglion angiographically occult vascular malformations. *Neurosurgery* 46:260–271, 2000.