

Motor Cortex Stimulation for Refractory Benign Pain

Andre Machado, M.D., Ph.D., Hooman Azmi, M.D., and Ali R. Rezai, M.D.

Chronic pain of benign origin is a very common problem in the population. Headaches and low back pain are among the most common reasons for seeking medical attention and absence from work. Nonmalignant pain as a problem in itself is brought to the neurosurgeon's attention at a late stage. Although individual patients may differ, a common pattern exists in the history of patients referred to the neurosurgeon's pain clinic. The vast majority of patients attempt initial treatment with over-the-counter medications and seek medical attention when symptoms persist. Specialists are then consulted to investigate the etiology of pain and propose treatment options for persistent pain. In a number of patients, surgical interventions are attempted to address the presumed cause of the pain. Pain physicians are then engaged when treatment of an etiological factor has proven ineffective or when the pain becomes more refractory. Medications are attempted in multiple regimens and titrated to optimal dosage. Blocks and ablations are attempted with minimally invasive techniques. Rehabilitation, physical therapy, acupuncture, behavioral therapy, and transcutaneous electrical nerve stimulation (TENS) are among the treatment alternatives offered to patients. Patients who fail to respond to medical, minimally invasive, behavioral, and complementary therapies may be considered candidates for surgical implants, such as spinal cord stimulation and intrathecal pumps for chronic infusion of pharmacological agents. Intracranial procedures for management of chronic benign pain are considered to be the "last resort" options for patients who are otherwise intractable. By then, the original pain is often complicated by intentional or nonintentional iatrogenic deafferentation and chronic use of narcotics. Central pain syndromes may be an exception to this pattern. More commonly caused by strokes, these problems are typically managed by neurologists and are deemed medically refractory at earlier stages. Behavioral problems are typically present in the chronic and treatment refractory pain population, ranging from depression and hopelessness to personality disorders. It is important to highlight that it is not without reason that intracranial neurosurgical interventions are reserved only for the most refractory patients. Deep brain stimulation (DBS) has been studied for the

management of refractory pain syndromes for nearly 40 years. A few reported series have indicated good outcomes after chronic stimulation^{2,5,9,10,12-14,17,22}, but an industry-sponsored randomized trial failed to achieve the proposed end points.⁴ DBS has not been approved by the United States Food and Drug Administration (FDA)⁴ for the management of refractory pain, and continues to be used either under investigational protocols or as "off-label" use of medical devices approved for the treatment of movement disorders. Motor cortex stimulation (MCS) has been investigated in humans for the past 15 years for the treatment of refractory pain syndromes and will be the focus of this chapter. When criticizing the outcomes of MCS, "it must be remembered that the forms of pain for which MCS can be effective, in at least half patients, are those for which there is no, or little other treatment".¹⁵

MCS for the treatment of chronic, refractory pain syndromes was pioneered by Tsubokawa et al.³⁵⁻³⁷. The authors had been motivated to investigate new treatment modalities for central deafferentation pain because of the poor results after chronic sensory thalamic stimulation in this patient population.³⁵ The first papers reported on 12 patients with central pain secondary mostly to intracerebral hemorrhages and infarcts.^{35,36} Five patients had complete resolution of the pain, which was maintained for the first year of follow-up, whereas three additional patients had "considerable" reduction of pain levels.

The Karolinska Institute group lead by Dr. Meyerson was the second to report results on a series of patients with chronic pain of heterogeneous etiologies.¹⁶ The results differed significantly from the index reports. In this study, patients with central deafferentation pain failed to respond to MCS. Only patients with trigeminal neuropathic pain (TNP) or peripheral neuropathies had favorable outcomes. The results were encouraging in the typically challenging group of patients with TNP, who presented with 60 to 90% pain relief. Interestingly, the poor outcomes in DBS for central pain were the driving motivation to explore MCS as a new target for neuromodulation.³⁶ Yet, the results of MCS seemed to follow the same trend as the earlier DBS outcomes reported by the pioneers of MCS, in which peripheral neuropathies had better results than central pain syndromes.³⁴ Subsequent series of MCS have been reported by a number of European and North

American centers. The results of the main series are summarized below.

A series of 32 patients with chronic pain (mean duration, 7.8 yr) was reported by the Creteil group in three main publications.^{18–20} Follow-up ranged significantly (3–50 mo). The authors indicate a switch in image-guidance methodology and surgical technique in the last 13 patients of the series. Instead of a burr-hole insertion of the electrodes, a craniotomy was performed, with the goal of allowing better exposure for electrophysiological recording and localization. Outcomes in this series were favorable in both trigeminal and central pain syndromes. Ten of 13 patients with central pain had greater than 40% pain relief, 5 of whom had greater than 70% relief. Patients with trigeminal pain continued to have a tendency for better outcomes. Nine of 12 patients had greater than 40% relief, 8 of whom had greater than 70% relief. The authors attribute the comparatively better outcomes in central pain to accurate localization of the motor cortex using computerized image guidance and extensive intraoperative electrophysiological localization. The relative short follow-up of some patients in this series after either a new implant or surgical revision of electrode positioning may account at least partially for the favorable outcomes. A gradual decrease in efficacy with long-term stimulation is not uncommon in neuromodulation procedures for chronic pain. The Cleveland Clinic group has reported on loss of efficacy over time and indicated that intensive reprogramming may help recapture benefits. In average, patients had lost benefits from stimulation 7 months after implantation. Use of two quadripolar electrode arrays instead of one improved the investigators' ability to recapture beneficial stimulation.⁶

Long-term outcomes after MCS were reported by Nuti et al.²¹ in 2004, in a series of 31 consecutive patients followed for an average of 4 years (2–104 mo). Most patients enrolled had central pain secondary to either intracerebral hemorrhages or infarcts. Half of the patients implanted presented with greater than 40% pain relief. The authors attribute the relatively worse outcomes of their series to the patient population, which did not include patients with trigeminal pain, thought to respond more favorably to MCS. In correlating outcomes to potential prognostic factors, only early results predicted long-term outcomes. Patients who did not respond to stimulation in the first month after the implant did not gain benefits later in the follow-up. Other factors, including pain characteristics, type and topography of etiological lesion, sensory testing, and motor function did not predict long-term results. In addition to measuring the percentage change in visual analog scale (VAS) scores, the investigators also inquired whether patients would have the procedure performed again to gain the same benefits. Surprisingly, 8 of 11 patients with 10 to 39% pain reduction and 12 of 13 with 40 to 69% alleviation answered “yes,” indicating that even

quantitatively modest results can be meaningful to patients with disabling chronic pain.

Brown and Pilitsis³ reported on the prospective results of MCS in a heterogeneous population of 10 patients with trigeminal pain, postherpetic neuralgia, or central pain. All patients had externalized trial stimulation for a period of 2 to 5 days. Eight of 10 patients experienced greater than 50% pain relief and underwent permanent implantation. At a mean follow-up of 10 months (3 mo–2 yr), six patients had greater or equal than 50% pain relief. Of the four patients who failed to respond either during the trial or after chronic stimulation, two had pain secondary to deep cerebral infarcts, one had trigeminal pain, and one had no clear etiology. Although this is a small sample, it indicates that the etiology of pain may influence long-term outcomes, in agreement with previous studies.¹⁶

Rasche et al.²⁹ reported on their long-term experience with MCS. The mean follow-up of this series was 3.5 years, and one patient was followed for 10 years. A single quadripolar array of electrodes was implanted through a burr hole, in awake patients. Of note, this series emphasized the importance of the trial period to determine good candidates for permanent implantation. The trial included a double-blinded assessment and was considered successful when the VAS scores dropped by 50% or more. Alternatively, a reduction of VAS scores between 30 to 50% was also accepted if the patient would also report a subjective sense of pain reduction along with improved mobility and functionality. Seventeen patients underwent the trial period, 10 with TNP and 7 with poststroke pain. Nine patients failed the trial, five with trigeminal pain and four with poststroke pain. Of these, six failures were determined by the double-blinded assessment, highlighting the presence of placebo effect in the surgical management of chronic pain. All of the eight implanted patients (five with trigeminal pain and three with poststroke pain) presented with sustained pain relief in the long-term follow-up.

MECHANISMS OF ACTION AND PATIENT SELECTION

MCS was proposed as a new method for treating central deafferentation pain.³⁶ The method was tested initially in healthy cats and in cats that had undergone ablation of the anterior spinothalamic tract with the purpose of creating a central deafferentation pain model.⁸ Cats suffering the deafferentation presented with hyperactivity of the sensory nucleus of the thalamus, characterized by increased mean spike density of isolated units and reduced interspike intervals. The finding was consistent with data collected previously from chronic pain patients undergoing microelectrode recording.⁷ Stimulation of the motor cortex increased the interspike intervals in tractotomized animals but not in healthy animals. The results indicated that stimulation of the motor cortex

could influence abnormal thalamic activity caused by deafferentation. These results provided additional scientific foundation for MCS trials in chronic pain patients. The initial positive results were attributed to a reduction of pathological thalamic activity and on increased regional blood flow in the areas affected by stimulation. The latter was thought to indicate a plasticity-mediated mechanism for pain alleviation. It is important to note that although lesions to the spinal cord can be considered “central,” the mechanisms underlying pathological thalamic hyperactivity and chronic pain may differ if the originating lesion is in the spinal cord, thalamus, internal capsule, or subcortical white matter. This may explain, at least partially, why the results of MCS for patients with poststroke central pain have differed so dramatically from series to series. Although stimulation of the motor cortex may indeed reduce thalamic hyperactivity caused by lesions distal to the thalamus (i.e., spinal afferent pathways), it may not be as effective in normalizing function after massive destruction of the thalamocortical loops. Hence, patients with pain after hemorrhages or infarcts of the subcortical white matter may not be good candidates for MCS because of the loss of integrity of the circuits thought to be affected by stimulation. This view is corroborated by the findings of Katayama et al.¹¹ in a study assessing predictive factors in 31 patients. Pain characteristics such as allodynia, dysesthesia, or hyperpathia were not predictive of long-term efficacy of MCS. Stimulation-induced phenomena, such as paresthesias and improvements in motor performance did not predict outcome either. Motor function, however, correlated well with the results of stimulation. Thirteen of 18 patients with minimal or no motor deficits had satisfactory pain alleviation from MCS, whereas only 2 of 13 patients with significant motor deficits had favorable results. In addition, 20 patients presented motor twitches induced by higher amplitude cortical stimulation during the surgical procedure. Fourteen of these patients had favorable long-term results. In contrast, only 1 of 11 patients in whom motor contractions could not be induced by cortical stimulation had good results from chronic stimulation of the motor cortex. The results indicate that preservation of descending pathways is important to accomplish MCS-induced analgesia. Data obtained with positron emission tomography (PET) scanning in patients with implanted motor cortex electrodes indicate that the analgesic effects are associated with increased blood flow to the anterior cingulate cortex, orbital frontal cortex, basal ganglia, and periaqueductal gray matter.²³ Functional connectivity studies indicated the participation of descending connections between the cingulate cortex and the periaqueductal gray. In analyzing the outcomes of the patients with MCS undergoing PET, the two patients with injury (hematoma and trauma) to the subcortical white matter had no long-term benefits, further corroborating that preservation of descending pathways is a necessary condition for favorable out-

comes. It is still unclear whether the analgesic effects of MCS are mediated by association fibers, by corticothalamic pathways,³⁶ or by other descending pathways that result in activation of the cingulate cortex, periaqueductal gray, or basal ganglia.^{23,24} Regardless, radiological and clinical evidence of preservation of descending pathways seems to be a relevant predictor of favorable outcomes.

In addition to clinical history, neurological examination and magnetic resonance imaging (MRI) scanning (to assess the topography of etiological lesions), additional tests may also aid in patient selection. Andre-Obadia et al.¹ applied repetitive transcranial magnetic stimulation (rTMS) in patients selected for MCS. Stimulation at 20 Hz was effective in alleviating pain in selected patients. Six of 11 patients who underwent MCS had satisfactory results from stimulation. Five of these six patients had experienced pain alleviation with rTMS, whereas only one patient responding to MCS had failed rTMS. In this study, rTMS had no false positives when predicting outcomes of MCS. This noninvasive technique may be useful in selecting potential candidates for MCS and may increase the proportion of favorable results among those undergoing MCS trials (see below) or permanent implantation.

When considering a patient with chronic pain as a potential candidate for MCS, a number of issues must be taken into consideration, as follows:

1. Common neurosurgical considerations for patient selection and risk management, such as assessment of cardiovascular risk, major organ disease, overall health, clotting disorders or use of anticoagulating agents.

2. Pain syndrome. Although MCS can be potentially successful in alleviating chronic pain syndromes secondary to various etiologies, including complex regional pain syndrome³³ and traumatic brain injury,³² the effects have been more consistently demonstrated in patients with TNP and central pain^{18,19,27–29,37}. Patients considered for these procedures should not only have high ratings in pain scales but should also be at least partially disabled by their pain condition to justify the degree of intervention and risk imposed by MCS.

3. Previous treatments. MCS should be considered a procedure of last resort. The history and previous treatments should be carefully reviewed and patients should not be considered candidates unless proper trials of first-line therapies have been attempted and failed. These should include extensive medical management with more than one single-drug trial as well as pharmacological combinations. In addition, many patients may also have tried minimally invasive procedures, such as blocks and other nonintracranial surgical procedures, such as intrathecal infusion and spinal cord stimulation.

4. Patient expectations and consent. Outcome expectations should be reasonable. Patients and family should un-

derstand from the beginning what the possible outcomes are. It is useful to ask the patient whether a reduction in pain by 40 to 50% would improve quality of life and enhance productivity and independence. If an externalized trial (see below) will be performed, it is useful to emphasize that the results are not completely predictable and the patient must be ready to accept another failure. It is a common misconception that more invasive (i.e., intracranial) procedures are necessarily more efficacious. These are abstract discussions and patients who cannot understand the relatively conservative odds of success for MCS may not be the best candidates. It is often necessary to have unusually detailed discussions to have a surgical consent that is truly informed.

5. Psychological evaluation. Potential candidates should undergo formal evaluation with a psychologist experienced in the field of chronic pain. Patients suffering from chronic pain that has been refractory to multiple therapies may have personality disorders, untreated psychiatric disease, and other comorbidities. These should be assessed and their presence should be taken into consideration during the decision-making process. Issues of secondary gain and pending legal actions seeking financial compensation may impact patient satisfaction in the future. The psychologist may also be helpful in assessing family dynamics and determine whether the family is ready for the procedure to either succeed or fail. Families tend to be physically, emotionally, and financially exhausted by the time MCS is considered. Failure may result in hopelessness, greatly stressing an already fragile family structure. Alternatively, it is not uncommon to see successful neurosurgical interventions for pain and movement disorders change the dynamics of families already accustomed to the sick and caregiver(s) roles.

6. Hardware maintenance. Patients and family should be educated to deal with the technology of the implantable devices. The postoperative period may be difficult if the patient has difficulty operating new technologies, such as cell phones. Families must have the commitment to bring the patient for programming at the specialized center as needed. Patients coming from remote areas may not be able to comply, and candidacy may have to be reconsidered. The implantable hardware is not compatible with MRI scanning. Individuals with health problems that will require MRI scans for optimal management need an additional layer of decision making. The risk imposed by not having MRI scans has to be balanced against the potential benefits of MCS for quality of life.

MCS EXTERNALIZED TRIAL

MCS is often initiated with an externalized trial of the implanted electrodes. Results from prospective series with long-term follow-ups indicated that early positive responses predicted favorable long-term outcomes with MCS.^{21,29} A rigorous trial period including double-blinded assessments

proved to be helpful in identifying patients who would ultimately fail chronic stimulation.²⁹

The externalized trial is performed with implantation and anchoring of the permanent electrode arrays in the epidural space, guided by imaging and electrophysiology (see the section below regarding technical options). Disposable extensions are attached to the implanted electrodes and externalized. If the trial is successful, the extensions are discarded and new implantable extension wires are used to connect the electrode arrays to the implantable pulse generators (IPGs). Saitoh et al.^{30,31} proposed a technical variation, using subdural grids for the trial period. Grids were implanted through a craniotomy and multiple combinations of electrodes were tried after the location of the central sulcus in relation to the grid was determined with somatosensory evoked potential (SSEP) N20 phase reversals.

The trial period typically ranges from 5 to 10 days. Extending the externalization period may increase the risk of infection but may be necessary when results are not immediately clear. Patients with chronic pain may find it difficult to report accurate pain ratings in the days after surgery because of the interference from the surgical incisional pain. This is particularly relevant in patients with TNP. In selected instances, an “internalized trial” may be preferred, when it is anticipated that programming will be difficult and misleading in the days after the craniotomy. When this approach is chosen, patients are implanted with the electrodes and IPG in the same stage, allowed to recover, and then programmed in the outpatient clinic to determine whether stimulation was effective or not. Explantation can be offered to those failing stimulation.

Programming of MCS can be a challenging, time-consuming task. There are a large number of possible combinations of cathodes, anodes, pulse widths, amplitudes, and stimulation frequencies. It is practical to first determine the combination of contacts to be used and the respective thresholds for motor twitches. Cathodes that cause motor twitching on the topography of the pain can be tested first, because they are likely to be closest to the desired segment of the motor cortex. The thresholds may vary depending on whether the patient is laying or sitting. It is best to maintain amplitudes below the lowest motor threshold to avoid stimulation-induced seizures. Submotor threshold stimulation of the motor cortex is characteristically imperceptible, making it challenging to find the contact combination that will produce the best analgesia. It may take the patients 30 minutes or more to appreciate the analgesic effect of each new stimulation setting, adding to the time consumption of the process. Sham or double-blinded stimulation is often necessary to assess the magnitude of the placebo effect. Trials are considered successful when at least one stimulation setting generates a reproducible reduction in pain, by 40 to 50% or more.

SURGICAL TECHNIQUE AND OPTIONS

Preoperative Planning and Image Guidance

Commercially available computerized frameless navigation stations can be used to accurately plan burr holes and craniotomies over the precentral cortex. Although stereotactic computerized tomography scans can be used for this purpose, volumetric MRI scans allow for more accurate identification and localization of the central sulcus. *Figure 12.1* shows the location of the motor cortex identified in stereotactic reformatted T1-weighted MRI scans used for preoperative planning. Functional MRI (fMRI)-assisted localization of the motor cortex has been recently proposed,^{25,26} showing a high correlation with intraoperative electrophysiological brain mapping. *Figure 12.2* illustrates the use of fMRI to assist in the identification of the motor cortex, using a motor paradigm.

Surgical Approach

Insertion of the electrode arrays was originally proposed through burr holes.^{35,36} Although this can be an effective method of implantation,²⁹ a trend exists toward performing craniotomies of approximately 5 to 6 cm over the sensorimotor cortex.¹⁹ This approach allows for better electrophysiological assessment of the motor cortex. SSEPs and electrical cortical mapping (ECM) can be performed using electrode grids (such as epilepsy grids) instead of the implantable electrode itself. The grids cover a greater cortical surface and help refine the location and orientation of the central sulcus. The generous exposure is also advantageous for securely anchoring the electrode array(s) in position by placing stitches at both ends of the leads (*Fig. 12.3*). A disadvantage of the craniotomy approach is postoperative pain, which can be particularly severe in the chronic pain population.

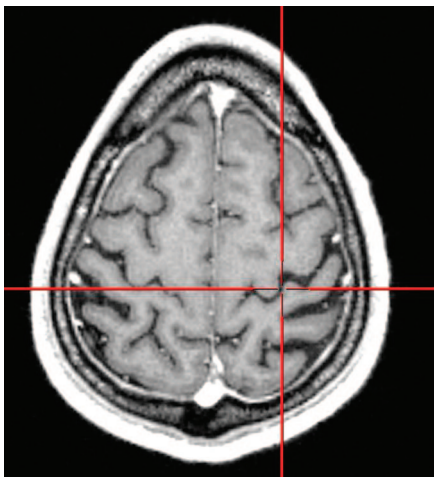

FIGURE 12.1. T1-weighted axial MRI scan showing the central sulcus.

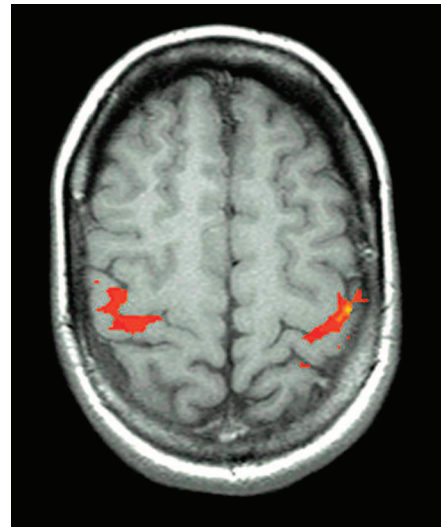


FIGURE 12.2. Functional MRI scan of the brain showing activity of the motor cortex during a bilateral finger-tapping task.

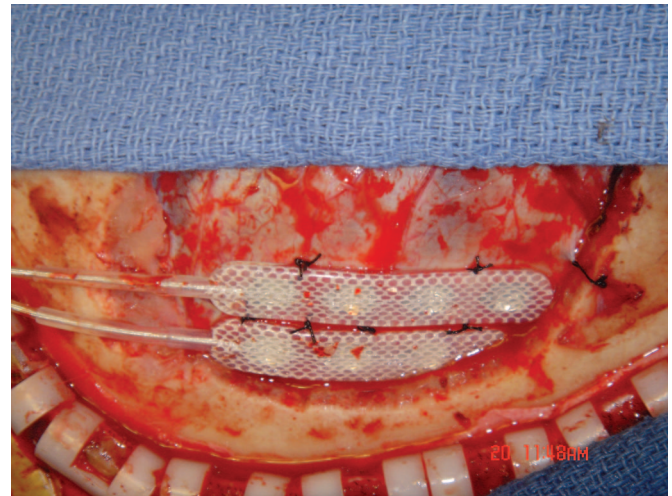


FIGURE 12.3. Intraoperative photograph showing anchoring of the leads to the dura once the central sulcus has been identified.

Intraoperative Mapping and Physiology

SSEPs are used for intraoperative localization of the central sulcus and precentral cortex. If a burr hole approach is chosen, the implantable electrode itself can be used for a relatively limited recording of the evoked potentials. In craniotomies, a grid of corticoelectroencephalography electrodes is preferred, covering a larger area (*Fig. 12.4*). The N20–P20 phase reversal is used to identify the central sulcus and to guide the implantation of the permanent electrodes. The grid allows for localization of the central sulcus at more than one point, determining its course within the craniotomy. This is useful for guiding the orientation in which the elec-

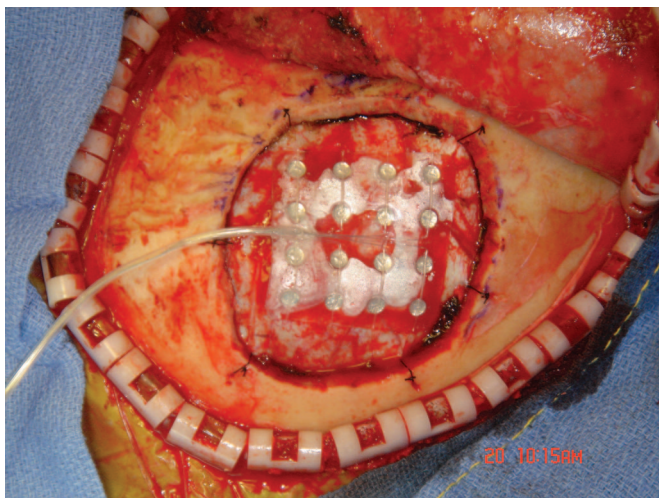


FIGURE 12.4. A grid of corticoelectroencephalography placed over the dura is being used to identify the central sulcus.

trodes will be implanted in relation to the sulcus and the precentral gyrus. Three-dimensional MRI scan reconstructions can also be helpful in determining the orientation of the precentral gyrus along the surface of the cortical convexity (*Fig. 12.5*).

ECM is also routinely used intraoperative and can be accomplished with the implantable electrodes or the monitoring grid. The electrode contact that produces motor twitches at the lowest thresholds in the topography of pain should be identified (patients should not be chemically paralyzed). The surgical and anesthesia teams should be watching carefully for the occurrence of twitches and be prepared to manage intraoperative seizures. If the grid is used for

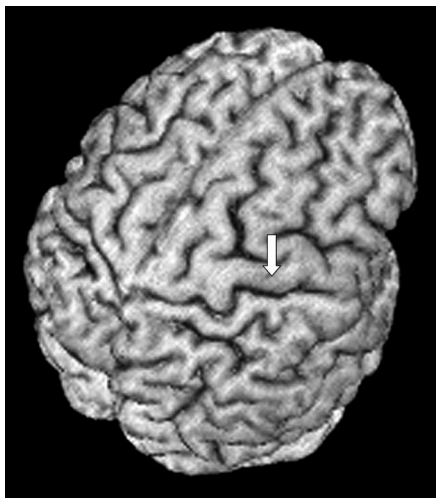


FIGURE 12.5. A three-dimensional MRI reconstruction (MRI-CRO software) of a patient's brain showing the central sulcus and precentral gyrus (*arrow*).

mapping, the dura corresponding to the optimal location for stimulation can be marked with surgical dye to guide implantation of the permanent electrodes. In patients without corticospinal injuries, ECM is likely to be the “gold standard” for localization. The cortical area mapped intraoperatively by stimulation represents the current topography of motor representation, even if cortical reorganization occurred as a consequence of the pathological process.

Electrode Implantation

Electrodes can be positioned parallel to the central sulcus when stimulating the parasylvian region for face or upper extremity pain and anteroposteriorly when stimulating the paramedian region for lower extremity pain. Although the early reports of MCS used predominantly single four-contact electrode arrays, the advent of the eight-channel IPG made it possible to implant two four-contact electrodes, allowing for a greater number of programming options. The additional electrode array often facilitates postoperative programming and has been shown to be useful in recapturing beneficial stimulation months after surgery⁶ (*Fig. 12.6*).

IPG Implantation

Internalization of the system is offered to patients who experience significant analgesic effects during the trial. The skin flap is partially reopened but there is no need to open the craniotomy because the electrode extensions are placed under the galea. The distal ends of the implanted electrodes are disconnected from the externalized extensions, which are discarded. A subcutaneous pocket is created in the subclavicular region to fit the chosen IPG model. In very thin patients, it is useful to create the pocket deep to the fascia to add another layer of protection and minimize the risk for skin erosion and hardware exposure.

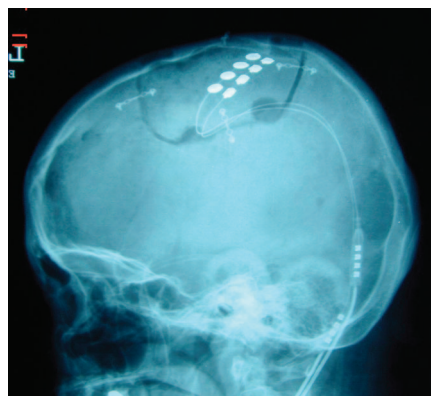


FIGURE 12.6. A lateral cranial x-ray showing two four-contact electrode arrays placed epidurally side by side to provide better coverage and to increase the number of programming options.

COMPLICATIONS

Complications of MCS can occur during the implantation procedure and during stimulation. Complications potentially associated with the procedures are those common to craniotomies in general and those specific to neuromodulation implants.

Infection

If no injury to the dura occurs, any infectious complications should be epidural and related to the flap, without a high risk for meningitis or cerebritis. The trial period with externalized electrodes may raise the infection rate in relation to most craniotomies. If an infection occurs and is thought to involve the implants, the hardware should be removed during a surgical exploration for debridement of the infected tissues to accomplish successful treatment with antimicrobial therapy.

Epidural Hematomas

We prefer central tack-up stitches even in these relatively small craniotomies to prevent epidural hematomas.

Electrode Migration

Suturing the electrodes to the dura of the convexity in several points is likely to prevent the complication of electrode migration (*Fig. 12.3*). Electrode migration is a potential problem in all neuromodulation procedures and is only minimized by adequate anchoring.

Hardware

Failure of the implants is still a common burden in stereotactic and functional neurosurgery. Electrodes, extension wires, IPGs, and, more importantly, the connections, are at risk for failure. Patients with good pain control are likely to complain of loss of efficacy when the hardware presents a defect. Interrogation and electronic analysis of the system may indicate abnormal impedances suggestive of circuit shorting or electrode breakage. Battery depletion is an expected complication of the procedure and requires periodical replacements. Experience with DBS electrodes has indicated that the connector between the intracranial electrode and the extension wire should be placed in the retroauricular region or elsewhere in the cranial segment. Connectors that are implanted in the subcutaneous tissue of the neck are very prone to result in electrode breakage.

Erosion

Segments where the skin is particularly thin or where the implants bulge tend to be at higher risk. In thin patients, it may be wise to implant the IPGs subfascially in the subclavicular region to add another layer of protection.

Stimulation-related Complications

Complications associated with stimulation tend to be transient and readily resolved by turning the pulse generators

off. Seizures can occur during programming and resolve with expedited administration of intravenous benzodiazepines and cessation of stimulation. As mentioned above, motor thresholds can be obtained with the patient lying and sitting, and the lowest threshold should be the reference for programming. Thresholds vary according to patient's position, most likely because of variations in the distances between dura and cortex. Headaches related to stimulation are reported by some patients. It is possible that these arise from stimulation of the dura's innervation. Attempts have been made to denervate the dura with bipolar coagulation to prevent this complication.

CONCLUSION

MCS can be a valuable tool for treating patients with refractory, chronic pain syndromes. MCS has been shown to be effective in patients without other treatment alternatives. Patients with TNP tend to have better results than patients with poststroke central pain syndromes. In the latter group, careful assessment of the neurological examination and lesion topography with neuroimaging may aid in selecting patients who are more likely to respond favorably. Patient selection should be careful and candidates should understand that MCS remains an "off-label" indication of an approved medical device. This reflects the still preliminary, variable, and frequently modest outcomes reported in the literature.

REFERENCES

1. Andre-Obadia N, Peyron R, Mertens P, Mauguiere F, Laurent B, Garcia-Larrea L: Transcranial magnetic stimulation for pain control. Double-blind study of different frequencies against placebo, and correlation with motor cortex stimulation efficacy. *Clin Neurophysiol* 117: 1536–1544, 2006.
2. Bittar RG, Kar-Purkayastha I, Owen SL, Bear RE, Green A, Wang S, Aziz TZ: Deep brain stimulation for pain relief: A meta-analysis. *J Clin Neurosci* 12:515–519, 2005.
3. Brown JA, Pilitis JG: Motor cortex stimulation for central and neuropathic facial pain: A prospective study of 10 patients and observations of enhanced sensory and motor function during stimulation. *Neurosurgery* 56:290–297, 2005.
4. Coffey RJ: Deep brain stimulation for chronic pain: Results of two multicenter trials and a structured review. *Pain Med* 2:183–192, 2001.
5. Hamani C, Schwab JM, Rezai AR, Dostrovsky JO, Davis KD, Lozano AM: Deep brain stimulation for chronic neuropathic pain: Long-term outcome and the incidence of insertional effect. *Pain* 125(1–2):188–196, 2006.
6. Henderson JM, Boongird A, Rosenow JM, LaPresto E, Rezai AR: Recovery of pain control by intensive reprogramming after loss of benefit from motor cortex stimulation for neuropathic pain. *Stereotact Funct Neurosurg* 82:207–213, 2004.
7. Hirayama T, Dostrovsky JO, Gorecki J, Tasker RR, Lenz FA: Recordings of abnormal activity in patients with deafferentation and central pain. *Stereotact Funct Neurosurg* 52:120–126, 1989.
8. Hirayama T, Tsubokawa T, Katayama Y, Yamamoto Y, Koyama S: Chronic changes in activity of the thalamic relay neurons following spinothalamic tractotomy in cats. Effects of motor cortex stimulation. *Pain* 5(suppl):273, 1990.
9. Hosobuchi Y, Adams JE, Linchitz R: Pain relief by electrical stimulation of the central gray matter in humans and its reversal by naloxone. *Science* 197:183–186, 1977.
10. Hosobuchi Y, Adams JE, Rutkin B: Chronic thalamic stimulation for the control of facial anesthesia dolorosa. *Arch Neurol* 29:158–161, 1973.

11. Katayama Y, Fukaya C, Yamamoto T: Poststroke pain control by chronic motor cortex stimulation: Neurological characteristics predicting a favorable response. **J Neurosurg** 89:585–591, 1998.
12. Kumar K, Toth C, Nath RK: Deep brain stimulation for intractable pain: A 15-year experience. **Neurosurgery** 40:736–746, 1997.
13. Kumar K, Wyant GM: Deep brain stimulation for alleviating chronic intractable pain. **Can J Surg** 28:20–22, 1985.
14. Levy RM, Lamb S, Adams JE: Treatment of chronic pain by deep brain stimulation: Long term follow-up and review of the literature. **Neurosurgery** 21:885–893, 1987.
15. Meyerson B: Motor cortex stimulation—Effective for neuropathic pain but the mode of action remains illusive. **Pain** 118:6–7, 2005.
16. Meyerson BA, Lindblom U, Linderöth B, Lind G, Herregodts P: Motor cortex stimulation as treatment of trigeminal neuropathic pain. **Acta Neurochir Suppl (Wien)** 58:150–153, 1993.
17. Nandi D, Liu X, Joint C, Stein J, Aziz T: Thalamic field potentials during deep brain stimulation of periventricular gray in chronic pain. **Pain** 97:47–51, 2002.
18. Nguyen JP, Keravel Y, Feve A, Uchiyama T, Cesaro P, Le Guerinel C, Pollin B: Treatment of deafferentation pain by chronic stimulation of the motor cortex: Report of a series of 20 cases. **Acta Neurochir Suppl** 68:54–60, 1997.
19. Nguyen JP, Lefaucher JP, Le Guerinel C, Eizenbaum JF, Nakano N, Carpentier A, Brugieres P, Pollin B, Rostaing S, Keravel Y: Motor cortex stimulation in the treatment of central and neuropathic pain. **Arch Med Res** 31:263–265, 2000.
20. Nguyen JP, Lefaucher JP, Decq P, Uchiyama T, Carpentier A, Fontaine D, Brugieres P, Pollin B, Feve A, Rostaing S, Cesaro P, Keravel Y: Chronic motor cortex stimulation in the treatment of central and neuropathic pain. Correlations between clinical, electrophysiological and anatomical data. **Pain** 82:245–251, 1999.
21. Nuti C, Peyron R, Garcia-Larrea L, Brunon J, Laurent B, Sindou M, Mertens P: Motor cortex stimulation for refractory neuropathic pain: Four year outcome and predictors of efficacy. **Pain** 118:43–52, 2005.
22. Owen SL, Green AL, Stein JF, Aziz TZ: Deep brain stimulation for the alleviation of post-stroke neuropathic pain. **Pain** 120:202–206, 2006.
23. Peyron R, Faillenot I, Mertens P, Laurent B, Garcia-Larrea L: Motor cortex stimulation in neuropathic pain. Correlations between analgesic effect and hemodynamic changes in the brain. A PET study. **Neuroimage** 34:310–321, 2007.
24. Peyron R, Garcia-Larrea L, Deiber MP, Cinotti L, Convers P, Sindou M, Mauguiere F, Laurent B: Electrical stimulation of precentral cortical area in the treatment of central pain: Electrophysiological and PET study. **Pain** 62:275–286, 1995.
25. Pirotte B, Neugroschl C, Metens T, Wikler D, Denolin V, Voordecker P, Joffroy A, Massager N, Brotchi J, Levivier M, Baleriaux D: Comparison of functional MR imaging guidance to electrical cortical mapping for targeting selective motor cortex areas in neuropathic pain: A study based on intraoperative stereotactic navigation. **AJNR Am J Neuroradiol** 26:2256–2266, 2005.
26. Pirotte B, Voordecker P, Neugroschl C, Baleriaux D, Wikler D, Metens T, Denolin V, Joffroy A, Massager N, Brotchi J, Levivier M: Combination of functional magnetic resonance imaging-guided neuronavigation and intraoperative cortical brain mapping improves targeting of motor cortex stimulation in neuropathic pain. **Neurosurgery** 56:344–359, 2005.
27. Rainov NG, Fels C, Heidecke V, Burkert W: Epidural electrical stimulation of the motor cortex in patients with facial neuralgia. **Clin Neurol Neurosurg** 99:205–209, 1997.
28. Rainov NG, Heidecke V: Motor cortex stimulation for neuropathic facial pain. **Neurol Res** 25:157–161, 2003.
29. Rasche D, Ruppolt M, Stippich C, Unterberg A, Tronnier VM: Motor cortex stimulation for long-term relief of chronic neuropathic pain: A 10 year experience. **Pain** 121:43–52, 2006.
30. Saitoh Y, Hirano S, Kato A, Kishima H, Hirata M, Yamamoto K, Yoshimine T: Motor cortex stimulation for deafferentation pain. **Neurosurg Focus** 11:E1, 2001.
31. Saitoh Y, Shibata M, Hirano S, Hirata M, Mashimo T, Yoshimine T: Motor cortex stimulation for central and peripheral deafferentation pain. Report of eight cases. **J Neurosurg** 92:150–155, 2000.
32. Son BC, Lee SW, Choi ES, Sung JH, Hong JT: Motor cortex stimulation for central pain following a traumatic brain injury. **Pain** 123:210–216, 2006.
33. Son UC, Kim MC, Moon DE, Kang JK: Motor cortex stimulation in a patient with intractable complex regional pain syndrome type II with hemibody involvement. Case report. **J Neurosurg** 98:175–179, 2003.
34. Tsubokawa T, Katayama Y, Yamamoto T, Hirayama T: Deafferentation pain and stimulation of the thalamic sensory relay nucleus: Clinical and experimental study. **Appl Neurophysiol** 48:166–171, 1985.
35. Tsubokawa T, Katayama Y, Yamamoto T, Hirayama T, Koyama S: Chronic motor cortex stimulation for the treatment of central pain. **Acta Neurochir Suppl (Wien)** 52:137–139, 1991.
36. Tsubokawa T, Katayama Y, Yamamoto T, Hirayama T, Koyama S: Treatment of thalamic pain by chronic motor cortex stimulation. **Pacing Clin Electrophysiol** 14:131–134, 1991.
37. Tsubokawa T, Katayama Y, Yamamoto T, Hirayama T, Koyama S: Chronic motor cortex stimulation in patients with thalamic pain. **J Neurosurg** 78:393–401, 1993.