

MSH6 Inactivation and Emergent Temozolomide Resistance in Human Glioblastomas

Daniel P. Cahill, MD, PhD, Patrick J. Codd, MD, Tracy T. Batchelor, MD, William T. Curry, MD, and David N. Louis, MD

Glioblastomas are the most commonly diagnosed primary human brain tumors. Unfortunately, these cancers are almost uniformly fatal; regardless of treatment, median survival is less than 2 years after diagnosis.²⁰ Current standard of care is maximal safe surgical resection followed by combined adjuvant radiation therapy and chemotherapy with the methylating alkylator agent temozolomide. Nonetheless, virtually all patients experience tumor regrowth, which is resistant to prior therapies and ultimately leads to the patient's death. We review recent large-scale molecular genetic studies of glioblastoma treatment resistance.

To identify genetic alterations driving the growth and treatment resistance of glioblastoma, large-scale genomic analysis in malignant gliomas was pursued as part of an international collaborative cancer genome sequencing effort.¹⁴ Unexpectedly, two glioblastomas, which were both recurrent tumors from patients who had received temozolomide, had large numbers of somatic mutations across many genes. By comparison, treatment-naïve tumors had orders-of-magnitude fewer mutations. The overall pattern of mutation suggested that a mutator phenotype had arisen in the recurrent cases during treatment. Thereafter, somatic inactivating mutations of the human DNA mismatch repair (MMR) gene *MSH6* were discovered in these recurrences, but not in any untreated tumors.¹⁶ Across a large number of well-characterized clinical samples, loss of the *MSH6* protein occurred only in the subset of recurrent glioblastomas that had been treated with temozolomide and was associated with progressive growth of these tumors while they were under temozolomide treatment.⁶

These studies represented the first identification of somatic inactivation of *MSH6* in recurrent human tumors of any tissue type and linkage of this loss with therapeutic resistance. Interestingly, these observations in human cancers mirrored prior comprehensive screening analyses identifying MMR pathway inactivation mediating alkylator resistance *in vitro*.^{3,11–13,18,23} Taken together, this work has led to the proposal that MMR inactivation can serve as an *in vivo* route

of emergent temozolomide chemoresistance in patients with glioblastoma. By selectively targeting this molecular pathway of temozolomide treatment escape with newer agents and modalities such as poly (adenosine 5'-diphosphate-ribose) polymerase inhibitors, local drug delivery polymers, or immunotherapeutics, there is hope for the improved design of combination therapeutic regimens.

Case Presentation

A 64-year-old woman presented to the emergency department with headache, nausea, and vomiting. She had difficulty relating the history of her illness, and her family noted that she had a personality change and progressive confusion over the weeks before presentation. She underwent a workup, which ultimately led to a contrast-enhanced magnetic resonance imaging (MRI) scan of the brain demonstrating a 5 cm × 4 cm × 3-cm left frontal enhancing mass with areas of central necrosis (*Fig. 22.1*). Metastatic staging workup was unrevealing, and she underwent craniotomy for tumor resection of a presumptive primary malignant brain tumor.

Histopathologic analysis of the surgical resection sample revealed a highly cellular tumor with numerous mitoses and pseudopalisading areas surrounding central necrosis and abundant microvascular proliferation. Confirming the preoperative diagnostic suspicions, these features were consistent with the diagnosis of glioblastoma (World Health Organization Grade IV/IV).

Postoperative MRI scan demonstrated gross total resection with no evidence of residual disease on the contrast-enhancing sequences. The patient underwent adjuvant therapy with combined involved field radiation therapy and temozolomide followed by monthly cycles of temozolomide maintenance therapy. After her eighth cycle of temozolomide monotherapy, she developed radiologic evidence of recurrent enhancement adjacent to the surgical resection bed. Stereotactic biopsy at 10 months after the initial operation proved equivocal for evidence of recurrent tumor versus a postradiation therapy treatment effect. The enhancement, however, rapidly enlarged despite steroid and continued temozolomide

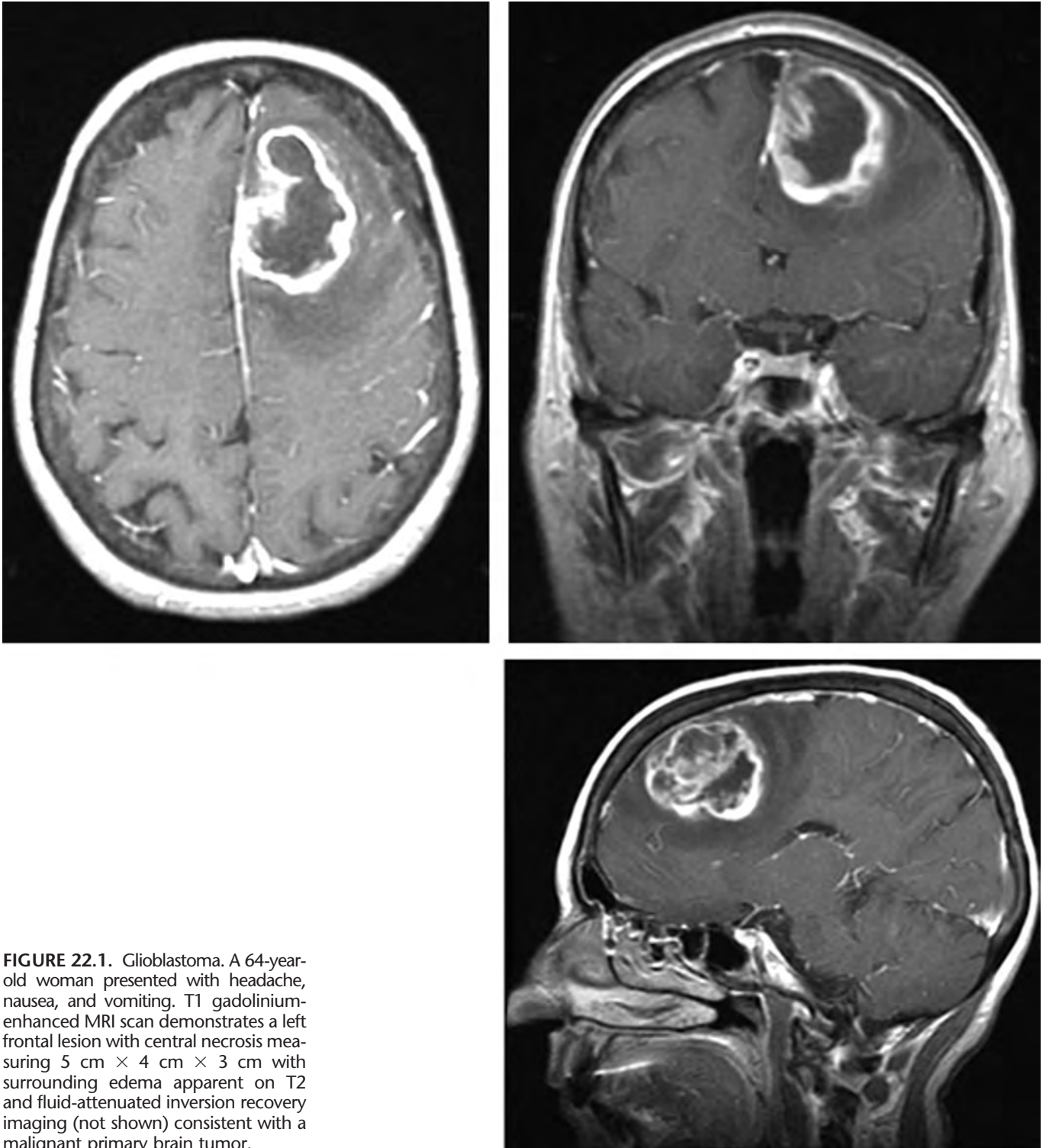


FIGURE 22.1. Glioblastoma. A 64-year-old woman presented with headache, nausea, and vomiting. T1 gadolinium-enhanced MRI scan demonstrates a left frontal lesion with central necrosis measuring 5 cm × 4 cm × 3 cm with surrounding edema apparent on T2 and fluid-attenuated inversion recovery imaging (not shown) consistent with a malignant primary brain tumor.

therapy, and the patient was transitioned to an experimental salvage treatment protocol for recurrent glioblastomas 15 months after her initial presentation. Disease progres-

sion stabilized briefly but then resumed a rapidly progressive course and the patient died 20 months after the date of presentation.

DISCUSSION

This case presents a course typical of primary malignant brain tumors in the early 21st century. Survival has been improved with more aggressive combination therapeutic regimens. The current standard-of-care postresection therapeutic approach with combined adjuvant radiation therapy and chemotherapy with the alkylating agent temozolomide has demonstrated a significant prolongation of life to a median survival of 14.6 months after initial diagnosis.²² Nonetheless, glioblastomas remain almost uniformly fatal. Virtually all patients experience tumor recurrence and ultimately die from their recurrent disease.

To identify the molecular changes driving glioblastoma tumorigenesis, the sequence of 518 known protein kinases was determined in eight gliomas within the context of a large-scale human cancer genome sequence analysis.¹⁴ Prior experience with large-scale kinase sequence screens has had notable success in identifying significant oncogenic mutations in several cancers of different tissue-types.^{2,10,17} Kinase screening is particularly useful from a prioritization standpoint because identification of an activated kinase immediately represents a molecular target for inhibitory drug design. Therefore, it was anticipated that this screening strategy might identify one or two kinases that were targeted by mutation in some glial tumors.

However, two glioblastomas, both recurrent in patients who had received temozolomide, were unexpectedly found to have large numbers of somatic mutations across many genes, whereas untreated tumors had few or no mutations.¹⁶ One of the recurrent tumors had 32 mutations, the other had 34 mutations, an observed mutation rate of one base pair change in every 10,000 to 20,000 base pairs (Fig. 22.2), and orders of magnitude higher than expected rates from known mutation rates in human cancers.²⁴ Because no kinase proved to be a common target in these screens, these data definitively excluded the possibility that activating point mutations of any known kinase underlie the development of a significant fraction of glioblastomas. More importantly, however, they represented a fortuitous discovery of the critical fingerprint of cancer evolution in response to treatment.

It has been hypothesized that an elevated mutation rate is required for the formation of tumors.¹⁹ This “mutator hypothesis” posits that an intrinsic genetic instability is required to permit a tumor cell mass to have enough intercellular diversity to clonally overcome the selection barriers faced during the course of tumorigenesis. Further studies in vitro have demonstrated that the pattern of genetic instability in the final tumor can be a reflection of the selection barriers that were faced during its initial evolution.^{1,5} The initial sequencing findings of increased mutations were in recurrent posttreatment tumors and thus plausibly a reflection of the evolutionary response of the tumor cell mass to the selection

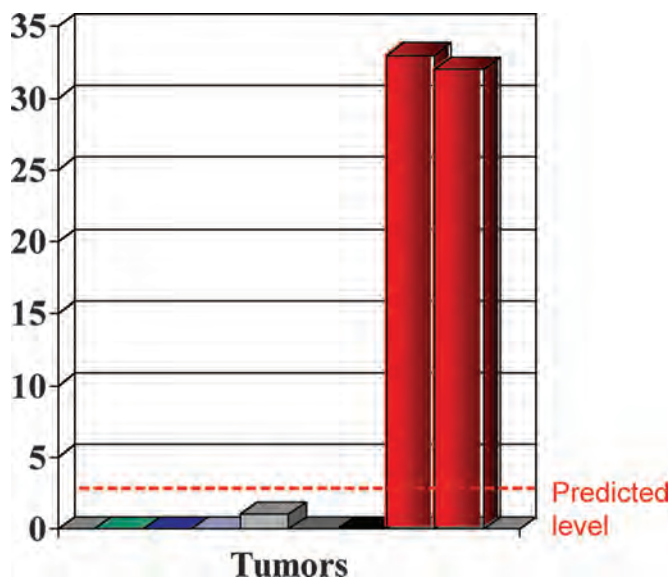


FIGURE 22.2. Evidence of a hypermutator phenotype. Large-scale genomic sequencing of 518 kinases in eight malignant gliomas identified unexpectedly large numbers of mutations in two glioblastomas, both of which were recurrent after treatment with the alkylating agent temozolomide. The y-axis shows the number of mutations observed, the x-axis has each individual tumor represented, and the expected rate of mutation based on empiric large-scale cancer genome sequencing analyses is indicated by the dashed horizontal line.

barrier imposed by the alkylating chemotherapeutic treatment itself. Because it had been well established that the DNA mismatch repair pathway mediated alkylator resistance in vitro,^{3,11,12,18} these mutational data pointed directly to the possibility that a human mismatch repair gene was inactivated to allow for tumor evolution and survival despite treatment. It was therefore hypothesized that genetic inactivation of MMR genes would be found in the recurrent tumors, but not in untreated tumors.

With this logic, somatic inactivating mutations of the human MMR gene *MSH6* in these two recurrent tumors, but not in any untreated tumors, were subsequently discovered. Furthermore, the overall pattern of mutation suggested that a mutator phenotype had arisen in the recurrent cases during treatment, directly matching the known spectrum of mutation from in vitro exposure of *MSH6*-null cells to alkylating agents.²³ Although MMR genes have been studied in gliomas and other noncentral nervous system neoplasms, these findings represented the first identification of somatic inactivation of *MSH6* in recurrent human tumors.¹⁶

These data raised the direct possibility that MMR pathway inactivation by mutation of *MSH6* or other MMR genes plays an important role in emergent glioblastoma chemoresistance (Fig. 22.3). It has been well documented that upfront analysis of *MGMT* expression status can be

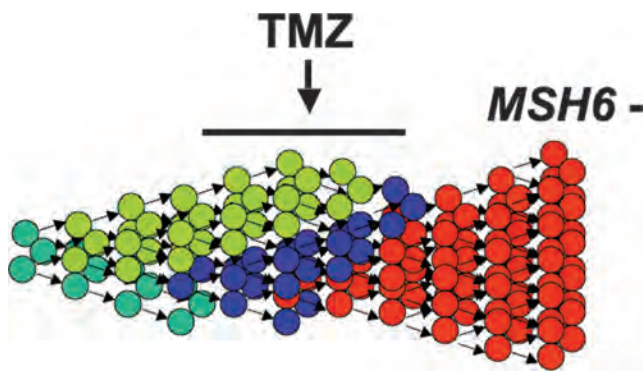


FIGURE 22.3. Model for the clonal emergence of *MSH6* inactivated recurrences. A tumor cell mass is a heterogeneous population, which undergoes selection based on intrinsic microenvironmental and extrinsic treatment-related pressures. Our working hypothesis is represented in this diagram; of note, we were unable to determine whether the *MSH6* inactivation was caused by the temozolomide treatment itself, was present in a small population of cells before treatment, or both.

predictive of temozolomide response in glioblastomas,¹⁵ and temozolomide has become the standard on which novel regimens for glioblastoma treatment are based.^{7,8,21} In vitro glioblastoma cell culture experiments have demonstrated that MMR pathway inactivation can supersede *MGMT* status as a mechanism for temozolomide chemoresistance.¹⁸ Thus, it became imperative to determine the frequency and clinical significance of *MSH6* inactivation and what relationship, if any, there was to *MGMT* status in actual specimens from patients who had undergone treatment for glioblastoma.

Description of Clinical Study Results

To test the hypothesis that *MSH6* or other MMR gene inactivation accounts for a significant fraction of temozolomide-treated recurrent glioblastomas, the coding sequence of *MSH6* was analyzed in both untreated and recurrent human glioblastomas.

The coding sequence of *MSH6* was determined in a total of 54 glioblastomas. The tumors assembled for sequencing analysis were identified based on two criteria: histologically confirmed glioblastoma (World Health Organization Grade IV) and availability of appropriate quality specimen (i.e., fresh-frozen surgical resection or early cell-culture passage) for genomic DNA sequence-based analyses. In total, 40 pretreatment tumors and 14 recurrent tumors were included in the study. The recurrent samples were selected broadly and had previously received a range of alkylator, nonalkylator, or even no chemotherapy (i.e., only receiving radiation therapy).

No mutations of *MSH6* were identified in any of the 40 pretreatment tumors. Therefore, germline or somatic *MSH6* mutations did not appear to contribute significantly to the pretreatment development of glioblastomas in typical sporadically presenting adult patients.

Strikingly, however, three *MSH6*-mutant cases were found among the 14 recurrent tumors when none of the pretreatment tumors had mutations. Because the recurrence rate of glioblastoma is near 100%, random sampling of recurrences is unlikely to introduce significant selection bias with respect to prior pretreatment status. Thus, comparison of the frequency of mutation in our pre- and posttreatment samples suggested that *MSH6* mutation is associated with recurrence.

These results, given the known function of the MMR pathway in mediating alkylator resistance in vitro, suggested that selection for *MSH6* inactivation could be a phenomenon associated specifically with alkylator treatment. Because the treatment regimens varied among these patients, the fact that only some of the recurrent samples had been exposed to temozolomide or other alkylators could account for the few recurrent cases with detectable *MSH6* mutations.

Therefore, to test the hypothesis that *MSH6* inactivation was a temozolomide-specific phenomenon, a panel of well-characterized untreated and recurrent tumors was studied at the histopathologic level with immunohistochemistry to determine the relationship among treatment, recurrence, and loss of detectable *MSH6* protein expression.

A second sample set of glioblastomas that had undergone adjuvant treatment with the standard-of-care alkylating agent temozolomide was assembled using three criteria to identify patients: histologically confirmed glioblastoma (World Health Organization Grade IV), treatment with a chemotherapeutic regimen that included temozolomide, and availability of an appropriate formalin-fixed, paraffin-embedded specimen. In total, 46 glioblastomas were scored for *MSH6* status by immunohistochemistry. Within this group, 38 specimens were from 21 patients who had received treatment with radiation therapy and temozolomide.

Of the tumors studied, 34 were matched pairs derived from 17 patients' pre- and postradiation therapy and temozolomide surgical resections, providing the additional benefit of certainty regarding the pretreatment *MSH6* status. In these matched specimens, every pretreatment tumor examined (17 of 17) stained positively for *MSH6* expression, consistent with previous immunohistochemistry studies of *MSH6* in other tumor types.

In matched postradiation therapy and temozolomide tumors from the same patients, staining for *MSH6* was completely absent in seven cases. Furthermore, in four additional postradiation therapy and temozolomide tumors, three had absence of *MSH6* protein. Therefore, in total, 10 of 21 postradiation therapy and temozolomide recurrent tumors displayed absence of *MSH6* by immunohistochemistry analysis (Fig. 22.4).

Interestingly, loss of *MSH6* was not observed in eight cases of recurrent glioblastomas that had been treated with radiation therapy only. Thus, *MSH6* loss was specifically

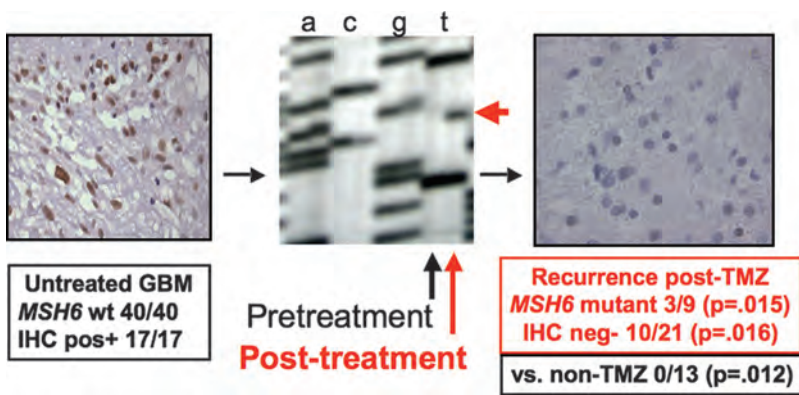


FIGURE 22.4. Evidence of clonal emergence of an *MSH6*-inactivated temozolomide-resistant subclone in recurrent glioblastomas. By a combination of DNA sequencing analyses and histopathologic immunohistochemical analyses, evidence consistent with the model of *MSH6* inactivation as a route of emergent temozolomide resistance was assembled.

associated with temozolomide treatment. Furthermore, loss of *MSH6* was not associated with upfront *MGMT* status as determined by immunohistochemistry. Other methods for determining *MGMT* status such as promoter methylation analysis or direct enzymatic assay may show a more closely linked association, and such studies are ongoing.

To test the hypothesis that *MSH6* inactivation results in clinically observed chemoresistance and tumor progression despite treatment, the relationship between *MSH6* inactivation and subsequent chemotherapeutic response was studied in patients with recurrent glioblastoma. Tumor growth rates were measured on gadolinium-enhanced MRI scans to perform in vivo calculations of growth-under-temozolomide treatment in patients stratified for *MSH6* status. We calculated in vivo tumor growth-under-treatment rates by comparing the volume of tumor on the initial scan with the volume present at cessation of temozolomide treatment. Strikingly, *MSH6*-negative glioblastomas demonstrated a markedly increased rate of growth while being treated with temozolomide with a median T1 gadolinium-enhancing signal change of +3.17 cm³/month (0.106 cm³/day), whereas median *MSH6*-positive tumor growth was only +0.04 cm³/month (0.001 cm³/day) under temozolomide treatment (Fig. 22.5). This increased growth rate suggested that *MSH6* loss in vivo corresponds to decreased clinical responsiveness to temozolomide and subsequent recurrent tumor growth during treatment, mirroring the alkylator resistance conferred by *MSH6* inactivation in vitro.

In summary, across a large number of well-characterized clinical samples, loss of the *MSH6* protein occurred only in the subset of recurrent glioblastomas that had been treated with temozolomide and was associated with progressive growth of these tumors while they were under temozolomide treatment.⁶ This evidence supports the proposal that *MSH6* inactivation serves as an in vivo mechanism of emergent chemoresistance in patients with glioblastoma.

CONCLUSION

These summarized studies demonstrate that loss of *MSH6* expression occurs in a significant subset of post-radiation therapy and temozolomide recurrent glioblastomas and is associated with the progressive growth of these tumors while they are under temozolomide treatment. These findings parallel in vitro studies documenting the frequent emergence of MMR deficiency in cell line subclones after selection and outgrowth in alkylating agents. Importantly, although many factors have been proposed to mediate therapeutic resistance based on studies of cancer cells exposed to differing doses of chemotherapeutic agents in vitro, these observations were made in patients receiving the clinical standard-of-care doses of temozolomide, indicating that *MSH6* loss appears to recapitulate its known in vitro alkylator resistance role in patients with glioblastoma in vivo.

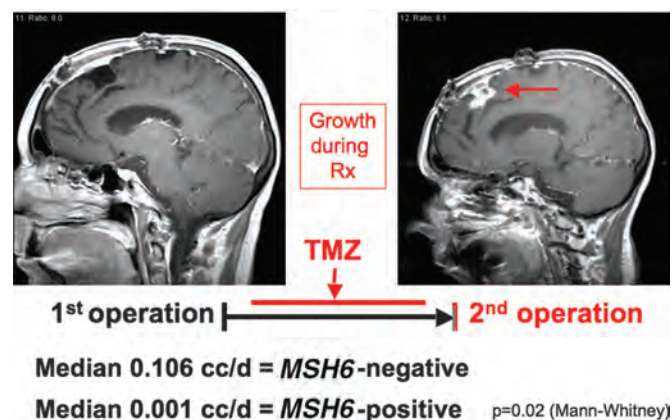


FIGURE 22.5. Association of *MSH6* inactivation with clinical temozolomide treatment failure in patients. Direct tumor volume measurements of patients undergoing standard-of-care treatment with temozolomide demonstrate a statistically significant difference in the rate of growth under treatment of *MSH6*-negative glioblastomas versus *MSH6*-positive glioblastomas. This observation provided in vivo evidence of treatment failure in humans.

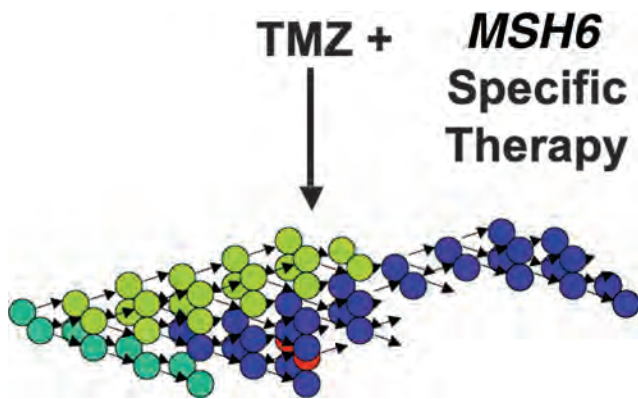


FIGURE 22.6. Future goals of combination therapy. Should *MSH6* inactivation prove to be a successful molecular target for future therapeutics, we can envision additive or even synergistic control of a subset of glioblastomas by combination with the existing standard-of-care radiation therapy and temozolomide.

One critical clinical question, given the apparent frequency of MMR emergence, arises: Can we test upfront for *MSH6* loss to better guide our therapies? Currently, the answer is no; using Sanger sequencing technologies and standard immunohistochemical techniques, *MSH6* scored as wild type in all pretreatment specimens. However, one can reasonably anticipate that a significant subset of the treatment failures will be associated with *MSH6* loss, and therefore introduce *MSH6*-specific therapeutic agents in combination with temozolomide upfront to selectively close off a common route of treatment escape (Fig. 22.6).

With the work described here serving as a foundation, we are now poised to directly test novel therapeutics in an isogenic glioblastoma cell culture system to evaluate these agents for their potential synergism with current therapeutic modalities. We can specifically evaluate the hypothesis that selective targeting of *MSH6* can identify new combination strategies for therapeutic consideration and also more generally evaluate novel agents with alternative mechanisms of action such as immunotherapeutic strategies, which could target the more than 200,000 new potential antigens present in *MSH6*-lost cells.

In vitro studies have shown that chemoresistant tumor cell lines frequently display differing degrees of crossresistance to other chemotherapeutic agents with similar mechanisms of action. Despite this evidence of crossresistance, it is apparent that loss of DNA damage checkpoint function can result in hypersensitivity to certain chemotherapeutic agents.^{4,9} Loss of MMR proteins is known to lead to aberrant checkpoint response to DNA-damaging agents, suggesting that chemotherapeutics that differ in mechanistic classification from alkylating agents could selectively target this escape pathway.⁸ With the isogenic glioblastoma cell systems

developed in our work, we can experimentally isolate both the various pharmacologic combinations and genetic backgrounds to strictly test proposed modalities and offer in vitro guidance for which cancer genetic profiles might yield the greatest benefit from these new regimens. The implication for combination therapy would be clear; successful targeting of *MSH6* inactivation in parallel with existing treatments could markedly improve tumor control for a significant proportion of patients with glioblastoma.¹¹

Disclosure

The authors did not receive financial support in conjunction with the generation of this article. The authors have no personal or institutional financial interest in drugs, materials, or devices described in this article.

REFERENCES

- Bardelli A, Cahill DP, Lederer G, Speicher MR, Kinzler KW, Vogelstein B, Lengauer C: Carcinogen-specific induction of genetic instability. *Proc Natl Acad Sci U S A* 98:5770–5775, 2001.
- Bardelli A, Parsons DW, Silliman N, Ptak J, Szabo S, Saha S, Markowitz S, Willson JK, Parmigiani G, Kinzler KW, Vogelstein B, Velculescu VE: Mutational analysis of the tyrosine kinome in colorectal cancers. *Science* 300:949, 2003.
- Branch P, Aquilina G, Bignami M, Karran P: Defective mismatch binding and a mutator phenotype in cells tolerant to DNA damage. *Nature* 362:652–654, 1993.
- Bryant HE, Schultz N, Thomas HD, Parker KM, Flower D, Lopez E, Kyle S, Meuth M, Curtin NJ, Helleday T: Specific killing of BRCA2-deficient tumours with inhibitors of poly(ADP-ribose) polymerase. *Nature* 434:913–917, 2005.
- Cahill DP, Kinzler KW, Vogelstein B, Lengauer C: Genetic instability and darwinian selection in tumours. *Trends Cell Biol* 9:M57–60, 1999.
- Cahill DP, Levine KK, Betensky RA, Codd PJ, Romany CA, Reavie LB, Batchelor TT, Futreal PA, Stratton MR, Curry WT, Iafrate AJ, Louis DN: Loss of the mismatch repair protein *MSH6* in human glioblastomas is associated with tumor progression during temozolomide treatment. *Clin Cancer Res* 13:2038–2045, 2007.
- Chang SM, Lamborn KR, Malec M, Larson D, Wara W, Sneed P, Rabbitt J, Page M, Nicholas MK, Prados MD: Phase II study of temozolomide and thalidomide with radiation therapy for newly diagnosed glioblastoma multiforme. *Int J Radiat Oncol Biol Phys* 60:353–357, 2004.
- Cheng CL, Johnson SP, Keir ST, Quinn JA, Ali-Osman F, Szabo C, Li HS, Salzman AL, Dolan ME, Modrich P, Bigner DD, Friedman HS: Poly(ADP-ribose) polymerase-1 inhibition reverses temozolomide resistance in a DNA mismatch repair-deficient malignant glioma xenograft. *Mol Cancer Ther* 4:1364–1368, 2005.
- Curtin NJ: PARP inhibitors for cancer therapy. *Expert Rev Mol Med* 7:1–20, 2005.
- Davies H, Bignell GR, Cox C, Stephens P, Edkins S, Clegg S, Teague J, Woffendin H, Garnett MJ, Bottomley W, Davis N, Dicks E, Ewing R, Floyd Y, Gray K, Hall S, Hawes R, Hughes J, Kosmidou V, Menzies A, Mould C, Parker A, Stevens C, Watt S, Hooper S, Wilson R, Jayatilake H, Gusterson BA, Cooper C, Shipley J, Hargrave D, Pritchard-Jones K, Maitland N, Chenevix-Trench G, Riggins GJ, Bigner DD, Palmieri G, Cossu A, Flanagan A, Nicholson A, Ho JW, Leung SY, Yuen ST, Weber BL, Seigler HF, Darrow TL, Paterson H, Marais R, Marshall CJ, Wooster R, Stratton MR, Futreal PA: Mutations of the *BRAF* gene in human cancer. *Nature* 417:949–954, 2002.
- Fink D, Aebi S, Howell SB: The role of DNA mismatch repair in drug resistance. *Clin Cancer Res* 4:1–6, 1998.
- Friedman HS, Johnson SP, Dong Q, Schold SC, Rasheed BKA, Bigner SH, Ali-Osman F, Dolan E, Colvin OM, Houghton P, Germain G, Drummond JT, Keir S, Marcelli S, Bigner DD, Modrich P: Methylator

- resistance mediated by mismatch repair deficiency in a glioblastoma multiforme xenograft. **Cancer Res** 57:2933–2936, 1997.
13. Goldmacher VS, Cuzick RA Jr, Thilly WG: Isolation and partial characterization of human cell mutants differing in sensitivity to killing and mutation by methylnitrosourea and N-methyl-N'-nitro-N-nitrosoguanidine. **J Biol Chem** 261:12462–12471, 1986.
 14. Greenman C, Stephens P, Smith R, Dalgleish GL, Hunter C, Bignell G, Davies H, Teague J, Butler A, Stevens C, Edkins S, O'Meara S, Vastrik I, Schmidt EE, Avis T, Barthorpe S, Bhamra G, Buck G, Choudhury B, Clements J, Cole J, Dicks E, Forbes S, Gray K, Halliday K, Harrison R, Hills K, Hinton J, Jenkinson A, Jones D, Menzies A, Mironenko T, Perry J, Raine K, Richardson D, Shepherd R, Small A, Tofts C, Varian J, Webb T, West S, Widaa S, Yates A, Cahill DP, Louis DN, Goldstraw P, Nicholson AG, Brasseur F, Looijenga L, Weber BL, Chiew YE, DeFazio A, Greaves MF, Green AR, Campbell P, Birney E, Easton DF, Chenevix-Trench G, Tan MH, Khoo SK, Teh BT, Yuen ST, Leung SY, Wooster R, Futreal PA, Stratton MR: Patterns of somatic mutation in human cancer genomes. **Nature** 446:153–158, 2007.
 15. Hegi ME, Diserens A, Gorlia T, Hamou M, de Tribolet N, Weller M, Kros JM, Hainfellner JA, Mason W, Mariani L, Bromberg JEC, Hau P, Mirimanoff RO, Cairncross JG, Janzer RC, Stupp R: MGMT gene silencing and benefit from temozolomide in glioblastoma. **N Engl J Med** 352:997–1003, 2005.
 16. Hunter C, Smith R, Cahill DP, Stephens P, Stevens C, Teague J, Greenman C, Edkins S, Bignell G, Davies H, O'Meara S, Parker A, Avis T, Barthorpe S, Brackenbury L, Buck G, Butler A, Clements J, Cole J, Dicks E, Forbes S, Gorton M, Gray K, Halliday K, Harrison R, Hills K, Hinton J, Jenkinson A, Jones D, Kosmidou V, Laman R, Lugg R, Menzies A, Perry J, Petty R, Raine K, Richardson D, Shepherd R, Small A, Solomon H, Tofts C, Varian J, West S, Widaa S, Yates A, Easton DF, Riggins G, Roy JE, Levine KK, Mueller W, Batchelor TT, Louis DN, Stratton MR, Futreal PA, Wooster R: A hypermutation phenotype and somatic MSH6 mutations in recurrent human malignant gliomas after alkylator chemotherapy. **Cancer Res** 66:3987–3991, 2006.
 17. Levine RL, Wadleigh M, Cools J, Ebert BL, Wernig G, Huntly BJ, Boggon TJ, Wlodarska I, Clark JJ, Moore S, Adelsperger J, Koo S, Lee JC, Gabriel S, Mercher T, D'Andrea A, Frohling S, Dohner K, Marynen P, Vandenberghe P, Mesa RA, Tefferi A, Griffin JD, Eck MJ, Sellers WR, Meyerson M, Golub TR, Lee SJ, Gilliland DG: Activating mutation in the tyrosine kinase JAK2 in polycythemia vera, essential thrombocythemia, and myeloid metaplasia with myelofibrosis. **Cancer Cell** 7:387–397, 2005.
 18. Liu LL, Markowitz S, Gerson SL: Mismatch repair mutations override alkyltransferase in conferring resistance to temozolomide but not to 1,3-bis(2-chloroethyl)nitrosourea. **Cancer Res** 56:5375–5379, 1996.
 19. Loeb LA, Loeb KR, Anderson JP: Multiple mutations and cancer. **Proc Natl Acad Sci U S A** 100:776–781, 2003.
 20. Louis DN, Ohgaki H, Wiestler OD, Cavenee WK (eds): *World Health Organization Histological Classification of Tumours of the Central Nervous System*. Lyon, International Agency for Research on Cancer, 2007.
 21. Quinn JA, Desjardins A, Weingart J, Brem H, Dolan ME, Delaney SM, Vredenburgh J, Rich J, Friedman AH, Reardon DA, Sampson JH, Pegg AE, Moschel RC, Birch R, McLendon RE, Provenzale JM, Gururangan S, Dancey JE, Maxwell J, Tourt-Uhlig S, Herndon JE, Bigner DD, Friedman HS: Phase I trial of temozolomide plus O-6-benzylguanine for patients with recurrent or progressive malignant glioma. **J Clin Oncol** 23:7178–7187, 2005.
 22. Stupp R, Mason WP, van den Bent MJ, Weller M, Fisher B, Taphoorn MJB, Belanger K, Brandes AA, Marosi C, Bogdahn U, Curschmann J, Janzer RC, Ludwin SK, Gorlia T, Allgeier A, Lacombe D, Cairncross JG, Eisenhauer E, Mirimanoff RO, Van Den Weyngaert D, Kaendler S, Krausenec P, Vinolas N, Villa S, Wurm RE, Maillot MHB, Spagnoli F, Kantor G, Malhaire JP, Renard L, De Witte O, Scandolaro L, Vecht CJ, Maingon P, Lutterbach J, Kobierska A, Bolla M, Souchon R, Mitine C, Tzuk-Shina T, Kuten A, Haferkamp G, de Greve J, Priou F, Menten J, Rutten I, Clavere P, Malmstrom A, Jancar B, Newlands E, Pigott K, Twijnstra A, Chinot O, Reni M, Boiardi A, Fabbro M, Campone M, Bozzino J, Frenay M, Gijtenbeek J, Delattre JY, De Paula U, Hanzen C, Pavanato G, Schraub S, Pfeffer R, Soffiotti R, Kortmann RD, Taphoorn M, Torrecilla JL, Grisold W, Huget P, Forsyth P, Fulton D, Kirby S, Wong R, Fenton D, Cairncross G, Whitlock P, Burdette-Radoux S, Gertler S, Saunders S, Laing K, Siddiqui J, Martin LA, Gulavita S, Perry J, Mason W, Thiessen B, Pai H, Alam ZY, Eisenstat D, Mingrone W, Hofer S, Pesce G, Dietrich PY, Thum P, Baumert B, Ryan G: Radiotherapy plus concomitant and adjuvant temozolomide for glioblastoma. **N Engl J Med** 352:987–996, 2005.
 23. Taverna P, Liu L, Hanson AJ, Monks A, Gerson SL: Characterization of MLH1 and MSH2 DNA mismatch repair proteins in cell lines of the NCI anticancer drug screen. **Cancer Chemother Pharmacol** 46:507–516, 2000.
 24. Wang TL, Rago C, Silliman N, Ptak J, Markowitz S, Willson JK, Parmigiani G, Kinzler KW, Vogelstein B, Velculescu VE: Prevalence of somatic alterations in the colorectal cancer cell genome. **Proc Natl Acad Sci U S A** 99:3076–3080, 2002.