

Neurological Society of India Guest Lecture: Optimally Invasive Skull Base Surgery

Basant Kumar Misra, MBBS, MS, MCh, Diplomate National Board

Skull base surgery has been an established neurosurgical discipline since the late 1980s. The initial enthusiasm of achieving eradication of a seemingly inoperable lesion by novel skull base approaches led many neurosurgeons to use radical surgery. The accompanying high morbidity was accepted as inevitable. Over the years, however, many started questioning this philosophy, and the last decade saw the pendulum swing to the other extreme with the increasing popularity of endoscopic surgery and radiosurgery. Thus, minimally invasive neurosurgery became the fashion. However, it is important to remember “the pearl” that inadequate treatment through a less invasive approach is maximally invasive. Realization has now dawned that endoscopic surgery, endovascular treatment, and radiosurgery cannot replace but should complement skull base surgery. A judicious use of skull base approaches with appropriate adjuncts and radiosurgery is the best way forward in dealing with various skull base lesions. Measures preventing neurovascular damage during surgery, adequate closure to prevent cerebrospinal fluid leaks, the nemesis of skull base surgery, and quick remedial measures to prevent and treat complications will go a long way toward achieving optimal results. Some examples of skull base tumors and complex aneurysms are shown here to answer some questions neurosurgeons face almost daily: whether to treat or not, whether to use microsurgery or radiosurgery, which surgical approach to use, and whether to attempt total or subtotal excision.

Our philosophy is that of optimally invasive skull base surgery, individualizing the approach to suit the given patient with a goal of achieving maximal result with minimal damage. Neuroendoscope, image guidance, endovascular therapy, and radiosurgery are used as pillars on the foundation of microsurgery.

NEUROLOGICAL SOCIETY OF INDIA AND THE STATUS OF NEUROSURGERY IN INDIA

The Neurological Society of India (NSI) was found in 1951, the same year as the Congress of Neurological Surgeons. Four neuroscientists—2 neurosurgeons, Jacob

Chandy and B. Ramamurthi; 1 neurologist, Baldev Singh; and 1 physician-electrophysiologist, S.T. Narasimhan—were the founding members.¹ The NSI had its first meeting in 1952 at Hyderabad with Dr Chandy as its first president. In this meeting, NSI decided to publish its own journal, *Neurology India*, which continues to be published regularly and is a highly acclaimed, indexed journal today, publishing all aspects of neuroscience. Until 1963, NSI held its annual meeting with the Association of Physicians of India. Beginning 1964, NSI started to have its own annual meetings. By 2009, NSI has 1489 full members, of whom 928 are neurosurgeons. As was envisaged by the founding members, NSI remains a society catering to all neuroscientists in India. Further information on NSI can be accessed at its website (www.neurosocietyindia.org). There is roughly 1 neurosurgeon for 1 million people in India. There are neurosurgery departments in 276 medical colleges and 75 major private hospitals. Currently, residency programmers in India take about 110 neurosurgery trainees per year.

The 2 major problems that affect everyone in India also affect neurosurgeons: a huge population with a vast proportion being below the poverty line. The neurosurgical community in India is thus often overworked, stretched to the limit, and sometimes frustrated by not being able to offer adequate/modern neurosurgical care to its country's poor. With more and more state-of-the-art neuroscience centers coming in India in both the private and public sectors, the burden is becoming manageable, and the neurosurgeon in India has quickly realized the opportunity knocking at the door. The combination of a large volume of clinical work and access to modern neurosurgical facilities has made the Indian neurosurgeon an enviable species. For example, while neurosurgeons in Europe and some other Western countries are clipping fewer and fewer aneurysms, the number of microsurgically managed aneurysms in India is increasing every month. There is similar high clinical load across the whole spectrum of neurosurgery. This leads to a significant exposure of residents to a variety of neurosurgical problems and hands-on experience. However, despite the great advances in the field of neurosurgery in India, there are major problems: variability of the quality of care across institutions, no defined minimum standard of care, long

distances that patients have to travel for treatment, inadequate follow-up, and inadequate neurorehabilitation facilities.

One method to ease some of the problems is the optimal use of resources. It is thus desirable not to duplicate facilities and have a 3-tier system: a peripheral center, a standard neurosurgical care center, and a tertiary referral center. It could be possible for everyone to have access to emergency neurosurgery, eg, for evacuation of extradural hematoma, at peripheral centers. Patients requiring complex neurosurgical procedures, eg, excision of a complex brain tumor or clipping of an aneurysm, can be referred to standard neurosurgical facilities. Patients requiring a multidisciplinary approach may then be referred to a tertiary referral center for radiosurgery, endovascular procedures, etc. However, this is easier said than done. One of the dreams of the NSI leadership is to make standard neurosurgical care available to every Indian.

OPTIMALLY INVASIVE SKULL BASE SURGERY

I have, in the last 3 decades, practiced neurosurgery mainly in tertiary referral centers in both public and private institutions and thus have been privileged to have access to the best facilities in India. The following paragraphs describe the philosophy of optimally invasive skull base surgery, a philosophy we have pursued for more than a decade. Optimally invasive skull base surgery may be defined as skull base surgery that is as minimally invasive as possible to achieve maximum efficiency, because inadequate treatment through a small approach is maximally invasive and adequate treatment through avoidable large approach is undesirable. When faced with a neurosurgical problem, particularly a skull base lesion, one is often faced with various dilemmas: whether to treat or not; whether to use microsurgery, radiosurgery, or endovascular therapy; which surgical approach to use; and whether to attempt total or subtotal excision. The decision-making process is very important but difficult and depends on environmental factors, patient factors, and pathological factors.

Environmental Factors

Rapidly advancing technology and newer modalities of treatment often require significant infrastructure development and additional training by the neurosurgeon, not to mention the increasing financial burden on the institution to remain up to date. Intense competition among the institutions and the industry and “one-up-manship” often result in the introduction of inadequately tested technology, sometimes without significant additional benefit. It is essential, particularly in India, a country with limited resources, to be able to deploy resources sensibly. An additional problem is the maintenance and after-sales service of extremely expensive machines. Many technologies are suboptimally utilized in India because of unacceptable downtime. One of the solutions lies in the technology development in the country of origin. Until that happens, it is a reality that the treatment offered to a given patient across many parts of India is

often dictated by the available facilities and not necessarily the most appropriate treatment.

Patient Factors

Important patient factors that affect decision making are age, comorbidity, neurological deficit at presentation, and to a certain extent, the patient's occupation and socioeconomic status. Advanced age and associated comorbidities often influence us to prefer a less invasive approach, for example, Gamma Knife radiosurgery (GKR) for an elderly patient or a patient with multiple comorbidities having a 2.5-cm vestibular schwannoma or jugular foramen tumor.^{2,3} On the contrary, a more radical microsurgical approach may be the better choice for a patient with affected neurology, eg, a patient with cavernous sinus neoplasm with ophthalmoplegia, a jugular foramen tumor with lower cranial nerve palsy, or a giant carotico-ophthalmic aneurysm with visual deficit, rather than radiosurgery and endovascular therapy.

Finally, although socioeconomic factors and occupation ideally should not influence treatment decision making, in practice they always do. A professional singer with a jugular foramen tumor or a preacher or an actor with a vestibular schwannoma may opt for a subtotal/nearly total excision of the tumor with or without adjunct GKR to guarantee normal function so that he or she can pursue his or her career. On the other hand, a manual laborer or an economically underprivileged person from a remote part of the country may prefer a 1-time microsurgical excision of a benign tumor or microsurgical clipping of an cerebral aneurysm to achieve a cure and to avoid multiple long-term visits for follow-up to evaluate the durability of treatment that he or she can ill afford.²

Pathological Factors

The last but probably most critical factors in the decision making are pathological factors. Where is the lesion? What is the lesion? A parasellar extracavernous tumor like a trigeminal schwannoma or meningioma can and should be cured by microsurgical total excision (Figure 1). On the other hand, the intracavernous component of a parasellar meningioma may be left without excision and observed safely or treated by radiosurgery.^{4,5} I do not prescribe primary GKR for cavernous sinus lesions without histological verification because of the risk of misdiagnosis and inappropriate treatment because some granulomatous lesions can mimic a meningioma.⁴ Since Yasargil's report on microsurgery of petroclival meningioma (PCM), many impressive series were published in the 1990s on the microsurgical management of PCM demonstrating the possibility of total excision of this formidable tumor.⁶⁻¹² The recent emphasis on the quality of life and the fact that total excision of the tumor, although it is good for the tumor and yields a great postoperative scan, may not be always the best for the patient have led many neurosurgeons to change the emphasis of total excision to tailored excision and risk

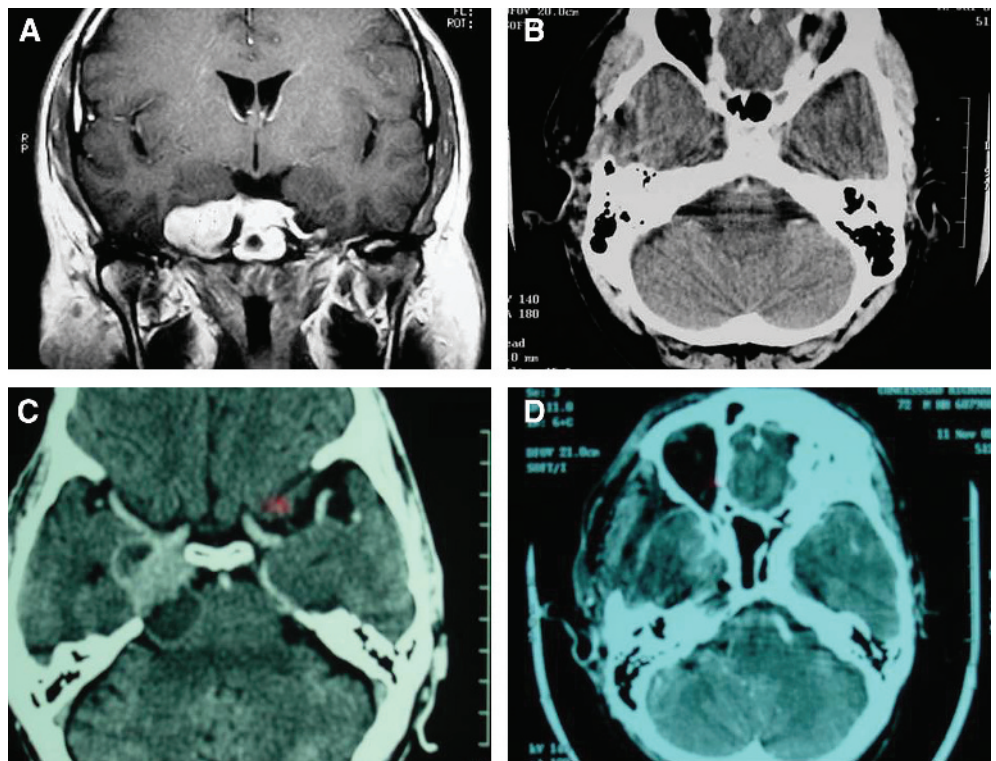


FIGURE 1. A and B, preoperative and postoperative contrast-enhanced (CE) scans in a case of right parasellar meningioma. C and D, preoperative and postoperative CE computed tomography scan in a case of right trigeminal schwannoma. Both the cases were operated via a right subtemporozygomatic craniotomy, and microvascular total excision was achieved.

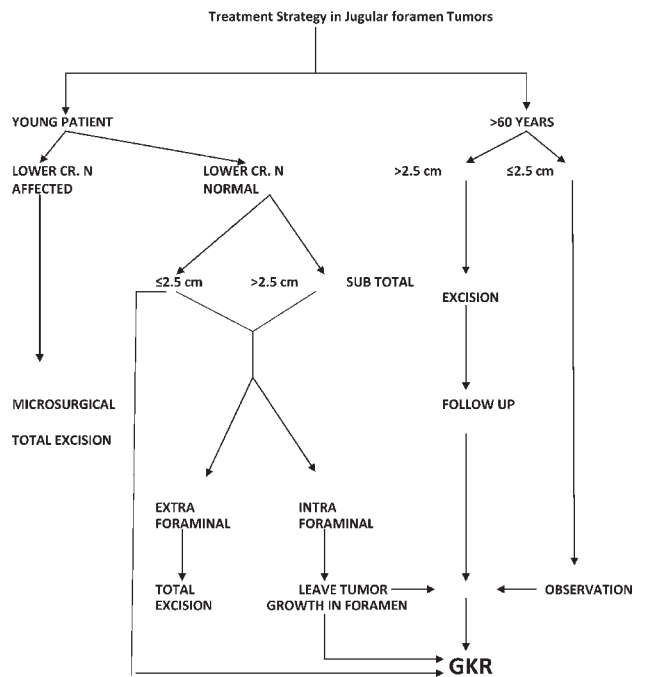
reduction.¹³⁻¹⁵ The total excision rates of 70% to 80% of PCMs during the 1990s have now fallen to around 40% in many series.¹³⁻¹⁶ This change is a result of the evidence that radiosurgery for small-volume tumors results in successful long-term control and that the natural history of untreated and subtotally resected PCMs is not too bad after all.¹⁷⁻²¹

Another issue that is constantly debated is the type of surgical approach, whether the surgeon should use a more extensive skull base approach, a conventional microsurgical approach, or a minimally invasive keyhole approach. It is essential that the surgeon is familiar with the various approaches and uses the one that is most appropriate for a particular patient. A patient-oriented and not a surgeon-oriented approach results in a happy patient. For example, in a suprasellar tumor, I practice a minimally invasive supraorbital approach for suprasellar meningioma arising from the tuberculum and planum sphenoidale and prefer a conventional pterional approach for most craniopharyngiomas, suprasellar meningiomas with significant hyperostosis and wide attachment, and most anterior circulation aneurysms. A more extensive frontotemporal orbitozygomatic approach is used for dorsum sellae meningioma, recurrent craniopharyngioma, and high basilar top aneurysms, and a minimally invasive endoscopy/endoscopy-assisted endonasal approach is used for a pituitary tumor, cystic craniopharyngioma, and Rathke cleft cyst. Sphenopetroclival meningioma (SPCM) without posterolateral and inferior extension beyond the internal acoustic meatus is best managed by a middle cranial

fossa/petrous apex approach. An orbitozygomatic craniotomy is added for tumors extending high up into the dorsum. SPCM with significant posterior fossa extension is best managed by a 2-stage anterior and posterior petrosal approach or anterior petrosal and retrosigmoid approach. In the last decade, I have reverted back in most cases to a retrosigmoid craniotomy and supraparacerebellar approach rather than a posterior petrosal approach in such a scenario and a 2-stage rather than a long 1-stage approach. A similar trend has been reported by other authors as well.¹⁴ Although the trend in my practice has been to revert back to conventional microsurgical approach in many skull base tumors that were previously operated on by extensive skull base approach, the reverse is true in the microsurgery of aneurysm. Endovascular treatment of cerebral aneurysm gained momentum with the advent of Guglielmi detachable coils in 1991 and has been accepted as a safer modality for mainly small aneurysms of the anterior circulation after the International Subarachnoid Aneurysm Trial in 2002.^{22,23} As a result, a greater proportion of aneurysms are complex, large, and giant aneurysms, which are still inadequately treated by endovascular treatment, that are treated by microsurgery. Unlike a large tumor that provides space for dissection after debulking, adequate exposure can be achieved in a giant aneurysm only by a dedicated skull base approach. Such an approach is especially critical for posterior circulation aneurysms.²⁴⁻²⁶

The nature of the lesion under treatment is as important as the location of the lesion. Ample evidence is available from

TABLE 1. Treatment Strategy.



NB, Modified, reproduced with permission from B.K. Misra; Treatment Strategy in Jugular Foramen Tumors.³¹

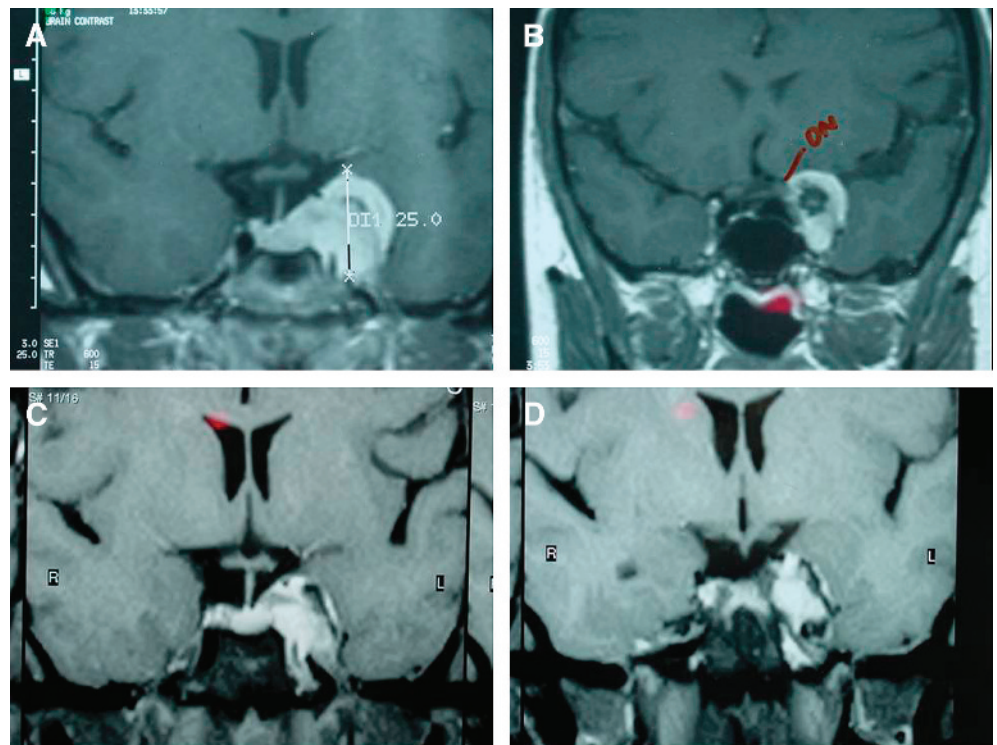
natural history studies regarding the benign nature of some pathologies that merit a period observation rather than upfront intervention.²⁷ An intracanalicular vestibular schwannoma and a < 7-mm unruptured aneurysm in the anterior circulation are some examples.²⁸⁻³⁰ More and more incidental lesions are picked up today because of easy availability of neuroimaging. It is vitally important that the natural history of these lesions, especially benign lesions at the skull base, is studied by multicentre cooperative trials to arrive at evidence-based guidelines of treatment. I have in many instances followed up patients with benign skull base tumors with minimal or no symptoms for many years without any worsening. An example is a jugular foramen tumor (schwannoma or glomus) with minimal or no symptoms, especially in a middle-aged or elderly patient who may not require treatment in his or her lifetime³¹ (Table 1).

Finally, it is important to anticipate the expected postoperative quality of life. Once in a while, one comes across a patient in whom any intervention would result in significant morbidity without any realistic chance of cure. It is prudent to allow nature take its course in such a scenario rather than playing God.

CASE ILLUSTRATIONS

The following cases illustrate how different approaches have been used to suit a particular patient for optimizing the outcome.

FIGURE 2. T1-weighted contrast-enhanced (CE) coronal magnetic resonance imaging (MRI) of the brain showing (A) left parasellar meningioma with sellar, intracavernous, and extracavernous extension (B) demonstrating hyperostosis of anterior clinoid and proximity of the tumor to the left optic nerve, (C) postoperative CE MRI demonstrating residual tumor in the cavernous sinus, and (D) 8-year follow-up CE MRI after Gamma Knife radiosurgery showing a decrease in the intracavernous component of the tumor.



Case 1

A 47-year-old woman, a practicing psychiatrist, presented to us with off-and-on double vision and headache for 6 months. On examination, she had minimal ptosis of the left eye with occasional double vision on looking upward and laterally. On examination, there was minimal left third and sixth paresis. Magnetic resonance imaging (MRI) demonstrated a parasellar tumor suggestive of meningioma with extension into the cavernous sinus and sella. The tumor was abutting against the left optic nerve, there was hyperostosis of anterior clinoid process, and the left internal carotid artery was narrowed by the tumor. A frontotemporal craniotomy and microsurgical excision of the parasellar tumor was done without entering the cavernous sinus in January 2000. The histopathology was, as expected, a grade I meningioma. Follow-up MRI of the brain with contrast enhancement (2 months after surgery) showed residual tumor inside the cavernous sinus. The options of periodic follow-up or adjunct GKR was explained to the patient. The patient, a physician herself, opted for upfront GKR, and she was thus treated. At the 9-year follow-up, the patient was fully functional without any deficit, and the tumor has decreased in size (Figure 2).

Case 2

A 43-year-old woman presented with left hemifacial spasm and hearing loss of 2 months' duration. On examination, there was no focal neurological deficit. MRI of the brain demonstrated a left PCM without any supratentorial extension. A retrosigmoid parasupracerebellar approach was used in April 2005, and total excision of the benign meningioma was achieved. Postoperatively, patient developed transient left facial hyperesthesia and left sixth and lower motor neuron seventh nerve paresis that improved over a few weeks. On review at 8 weeks, the patient had no neurological deficit, and MRI confirmed complete excision of the tumor. The patient remained asymptomatic without any recurrence of tumor at the 4-year follow-up (Figure 3).

Case 3

A 43-year-old woman, an Omani national, was referred to us with headache, left facial hypoesthesia, and double vision

of 6 months' duration. On examination, she had left fifth (V2-3 hypoesthesia), left lower motor neuron facial paresis, left sensorineural hearing loss, and pyramidal signs. MRI of the brain with contrast enhancement showed a left SPCM. A petrosal translabyrinthine approach was used in February 2002, and total excision of the intradural component of the meningioma was achieved, leaving the intracavernous tumor behind. Because the patient was from another country, periodic follow-up was difficult, and the patient had presented with a large symptomatic tumor, upfront GKR was done for the residual tumor in cavernous sinus. After 7.5 years of follow-up, the tumor in the cavernous sinus remained controlled. The patient remained symptom free with grade II facial paresis until 2007, when she developed trigeminal neuralgia that responded to carbamazepine (Figure 4).

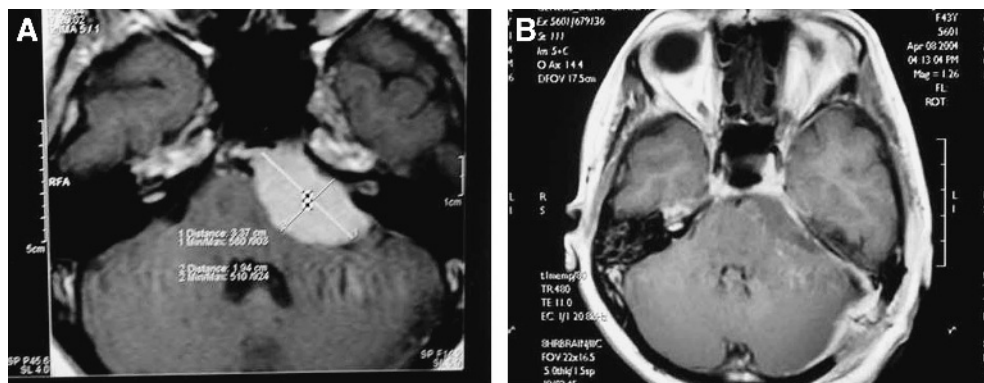
Case 4

A 44-year-old woman, a Pakistani national, was referred to us after an unsuccessful attempt at excision of a giant SPCM at another center in 2008. She had presented with headache, double vision, and difficulty in walking and swallowing of 5 months' duration. On examination, she had left 3rd, 6th, 7th, 9th, and 10th cranial nerve paresis. A planned 2-stage surgery strategy was decided. Initially, a left retrosigmoid supra-paracerebellar approach was used, and the posterior fossa component of the tumor was removed. A few months later, a second-stage frontotemporal craniotomy and extradural/subdural approach was performed, and near total excision of the intradural component of the tumor was achieved. The residual tumor in the cavernous sinus was treated by adjunct GKR. The patient at the 1-year follow-up was fully functional with facial numbness on the left side, grade II facial paresis, and no recurrence of the tumor (Figure 5).

Case 5

A 34-year-old man from a neighboring country presented to us with history of headache and hoarseness of voice of 6 months' duration. He had a 2-month history of imbalance and some difficulty in swallowing liquids. A retrosigmoid craniotomy and unsuccessful attempt at excision

FIGURE 3. T1-weighted contrast-enhanced axial magnetic resonance imaging showing (A) preoperative image demonstrating a left petroclival meningioma and (B) 3-month postoperative image confirming complete excision



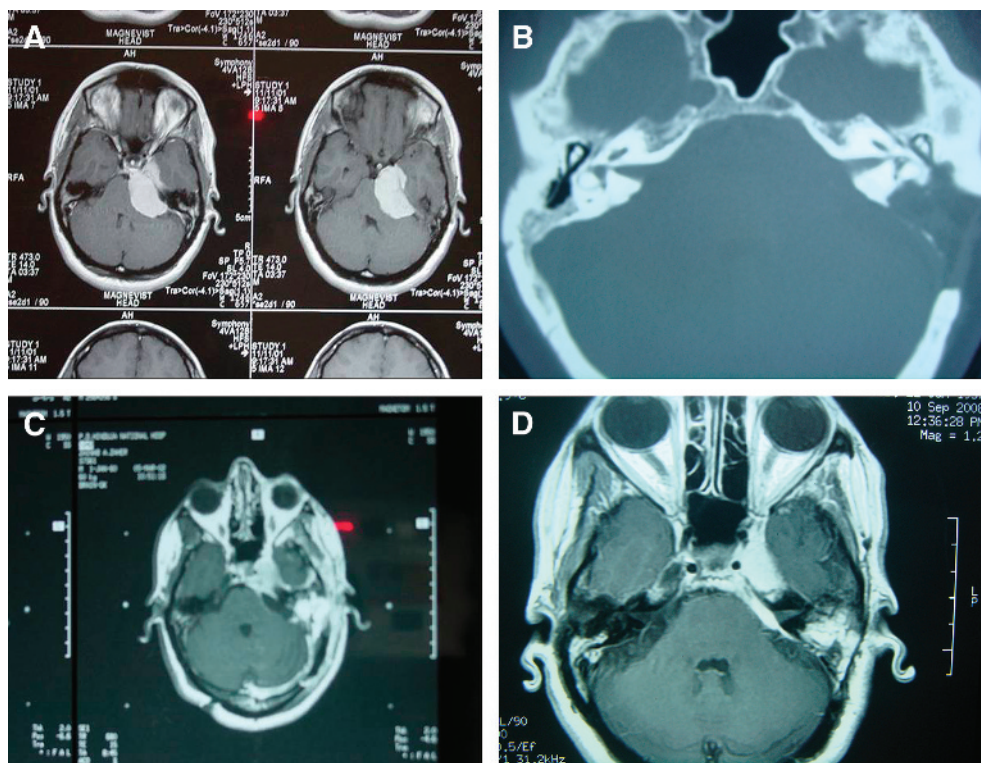


FIGURE 4. A, T1-weighted contrast-enhanced (CE) magnetic resonance imaging (MRI) of the brain showing a left sphenopetroclival meningioma. B, postoperative computed tomography scan brain showing the extent of petrous bone resection in the translabyrinthine approach. C, T1-weighted CE MRI of the brain at the time of Gamma Knife radiosurgery for the residual tumor in the cavernous sinus. D, 7-year follow-up CE MRI axial images showing a static tumor in the cavernous sinus.

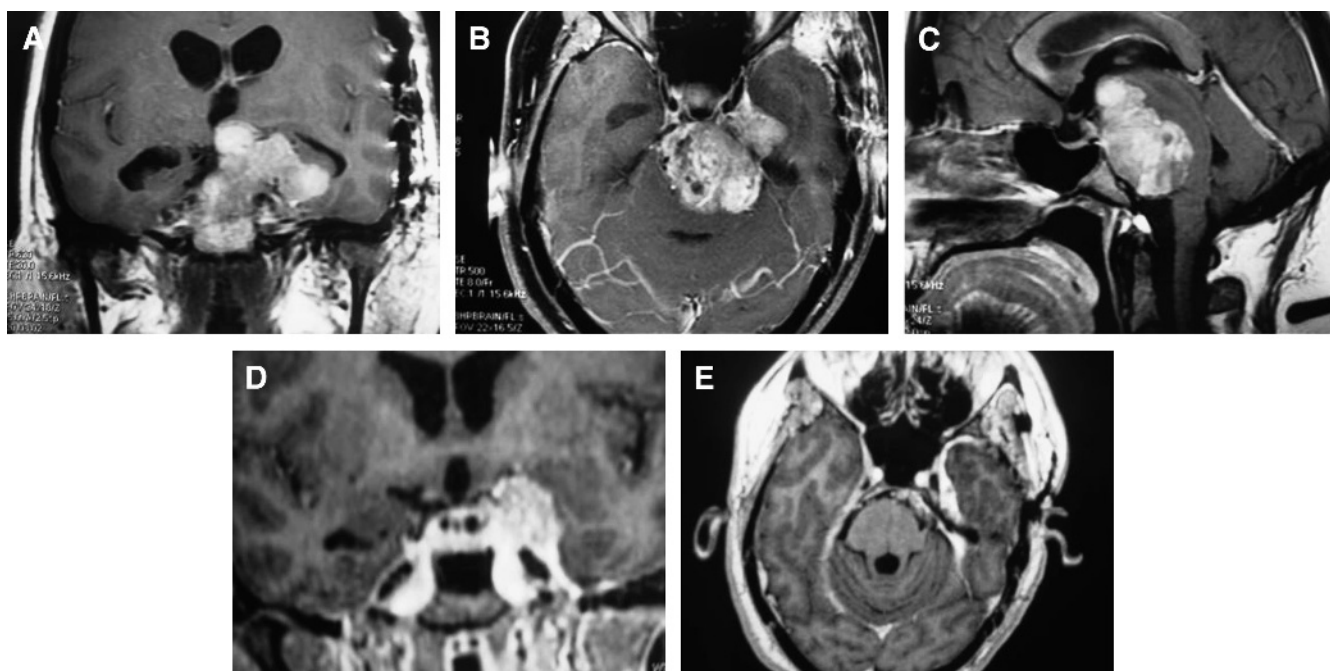


FIGURE 5. Contrast-enhanced (CE) magnetic resonance imaging (MRI) in the (A) coronal, (B) axial, and (C) sagittal views of the brain demonstrating a large left sphenopetroclival meningioma (after an attempted excision in an outside facility). D, postoperative CE MRI coronal image after the first stage of retrosigmoid craniotomy with residual tumor in middle cranial fossa. E, postoperative CE MRI axial image after the second-stage frontotemporal craniotomy and nearly total excision of the tumor (reproduced with permission from B.K. Misra).⁴

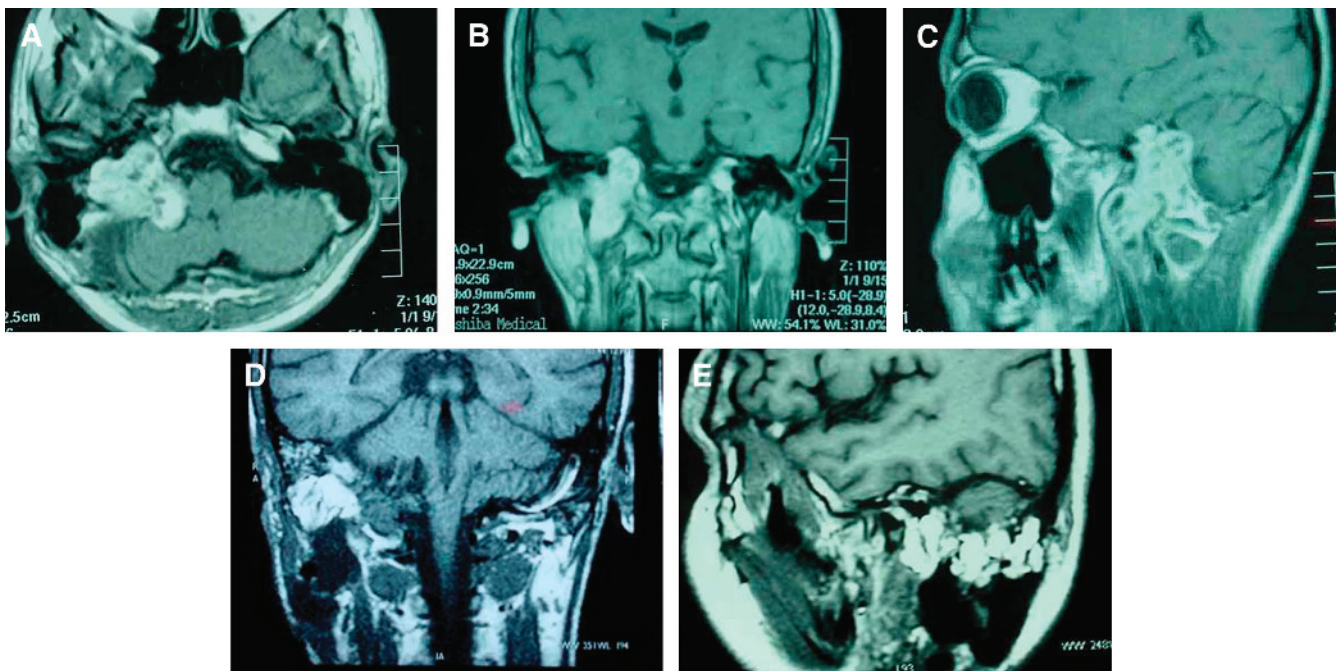


FIGURE 6. A, axial; B, coronal; and C, sagittal T1-weighted contrast-enhanced (CE) magnetic resonance imaging (MRI) of the brain showing a large right jugular foramen schwannoma extending from the cerebellopontine angle through the jugular foramen to the cervical region. Postoperative T1-weighted CE MRIs in the (D) coronal and (E) sagittal views showing complete excision of the tumor after a combined retrosigmoid, infralabyrinthine, and cervical approach.

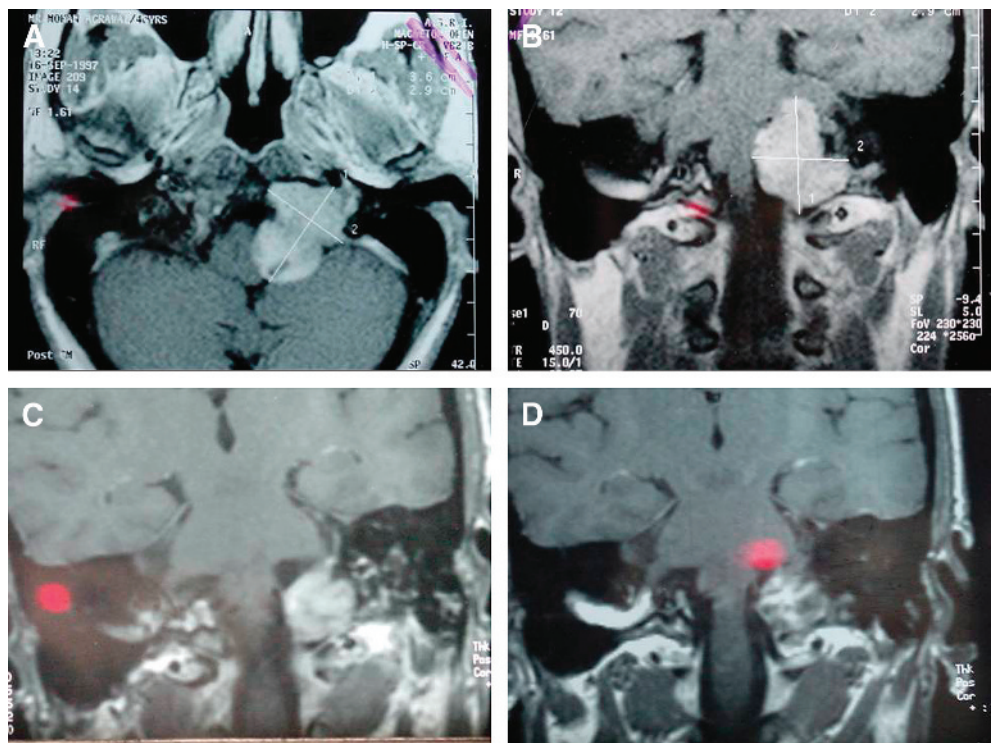
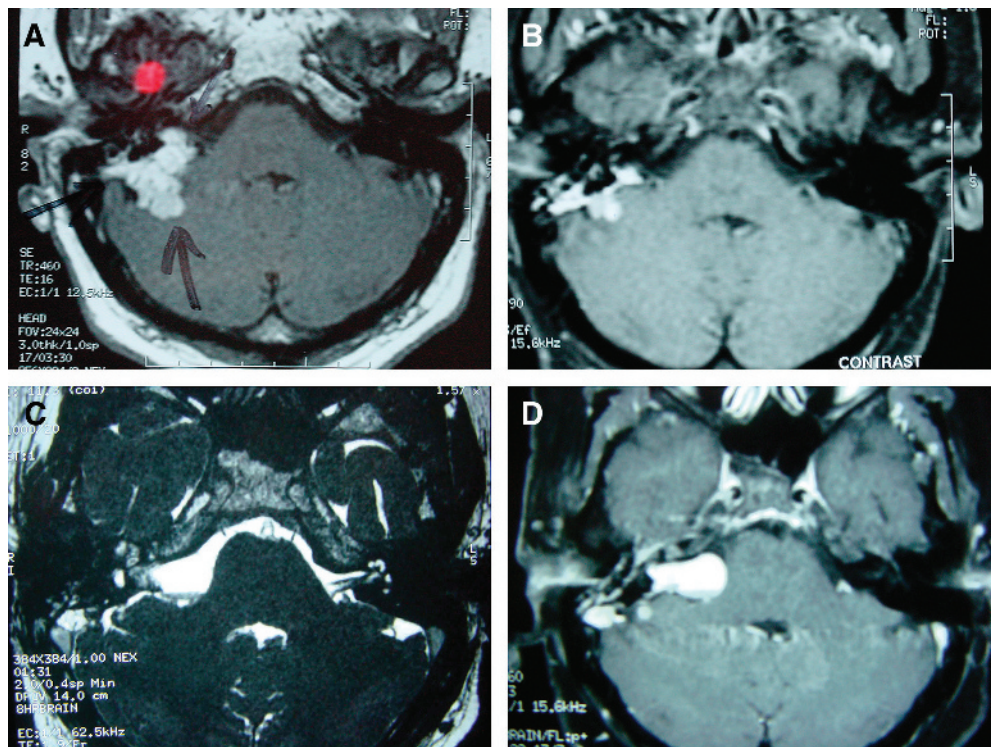


FIGURE 7. Preoperative T1-weighted contrast-enhanced (CE) magnetic resonance images (MRIs) in the (A) axial and (B) coronal views of the brain showing a jugular foramen schwannoma extending from the cerebellopontine angle to the jugular foramen. C, postoperative CE coronal MRI of the brain showing residual tumor in the jugular foramen that was treated by Gamma Knife radiosurgery. D, 12-year follow-up CE coronal images of the brain showing a reduction in the size of residual tumor.

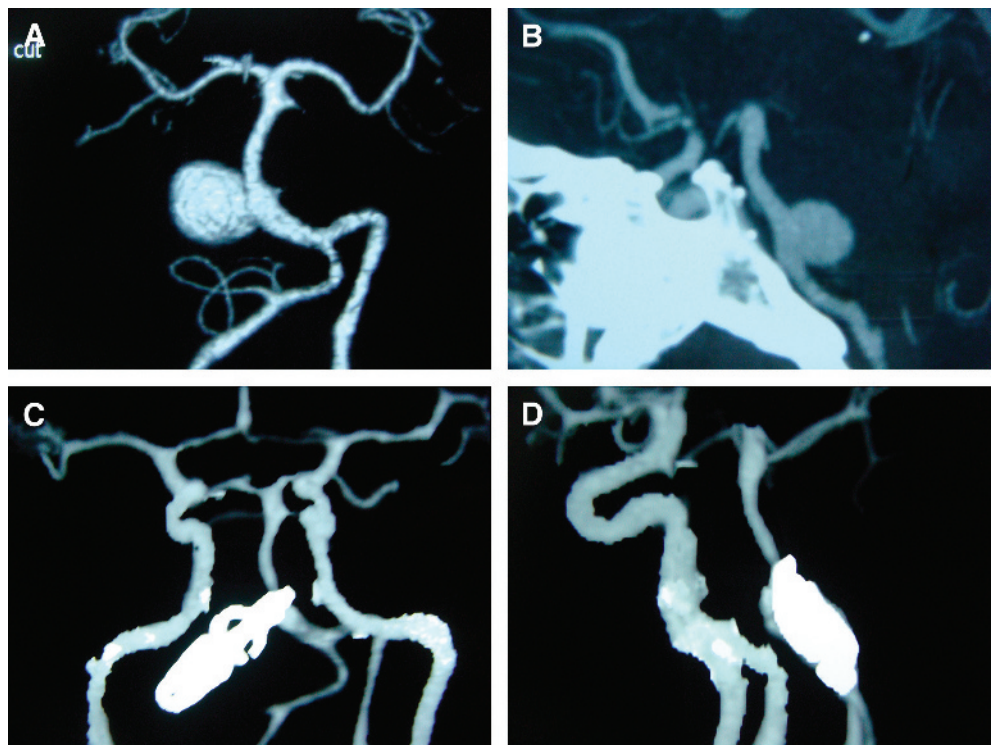
FIGURE 8. A, T1-weighted contrast-enhanced (CE) magnetic resonance imaging (MRI) axial image of the brain showing a medium-sized glomus jugulare. The patient was treated by primary Gamma Knife radiosurgery, and the tumor was decreased significantly at 18 months. B, 7-year follow-up T1-weighted CE MRI axial images showing significant reduction of the tumor. C and D, 9-year follow-up T1-weighted and T1-weighted CE MRIs of the brain showing cystic lesion with peripheral enhancement at the previous tumor site. The patient is being closely observed.



of the posterior fossa tumor had been done in another center 3 months previously. On examination, the patient had papilloedema, left IX, X nerve palsy, bilateral pyramidal and left cerebellar signs, and a retrosigmoid scar from a previous

operation. MRI demonstrated a giant right jugular foramen tumor extending from cerebellopontine angle to the neck through the jugular foramen. A combined retrosigmoid, infralabyrinthine, and cervical approach was used, and total

FIGURE 9. A and B, preoperative computed tomography (CT) angiogram of brain vessels showing a large aneurysm of the basilar trunk. C and D, post-operative CT angiogram showing complete obliteration of the aneurysm with preservation of the normal vessels after a petrosal retrolabyrinthine approach.



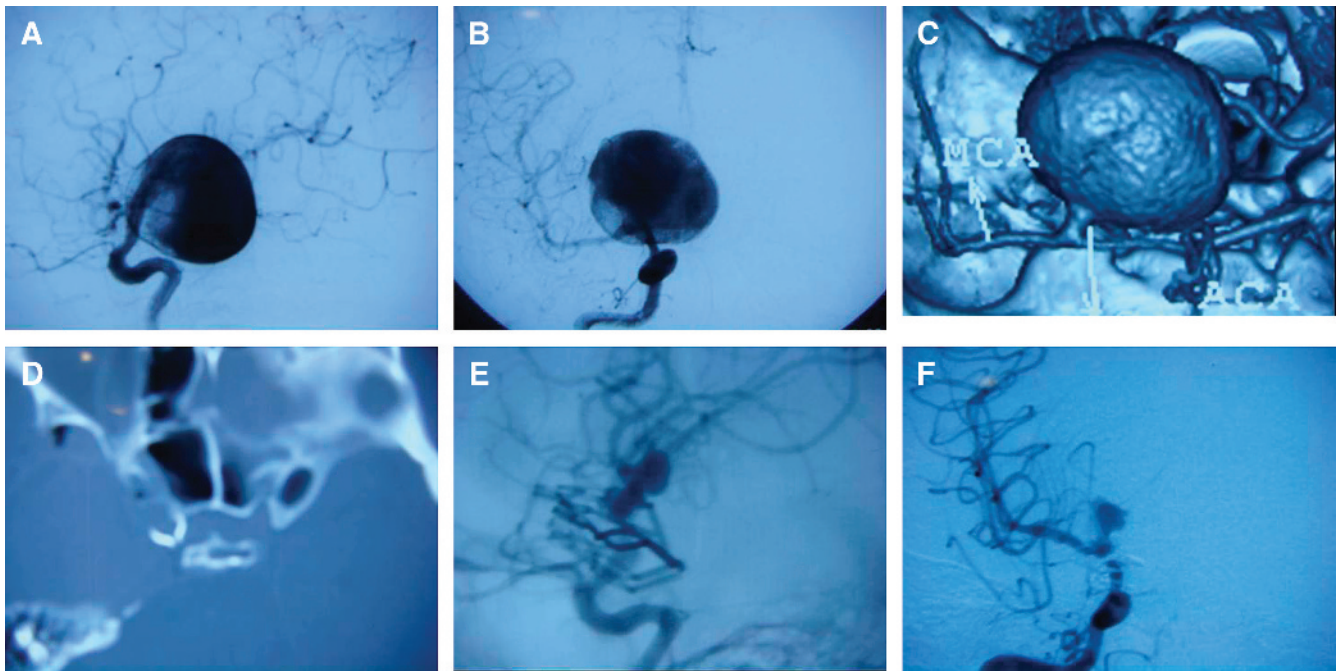


FIGURE 10. A and B, digital subtraction angiography; and C, computed tomography (CT) angiogram showing a giant aneurysm of distal supraclinoid internal carotid artery of the right side. D, postoperative CT showing the direction of clip and extent clinoid drilling. E and F, postoperative digital subtraction angiography demonstrating small residual filling of the aneurysm but preservation of all normal arteries.

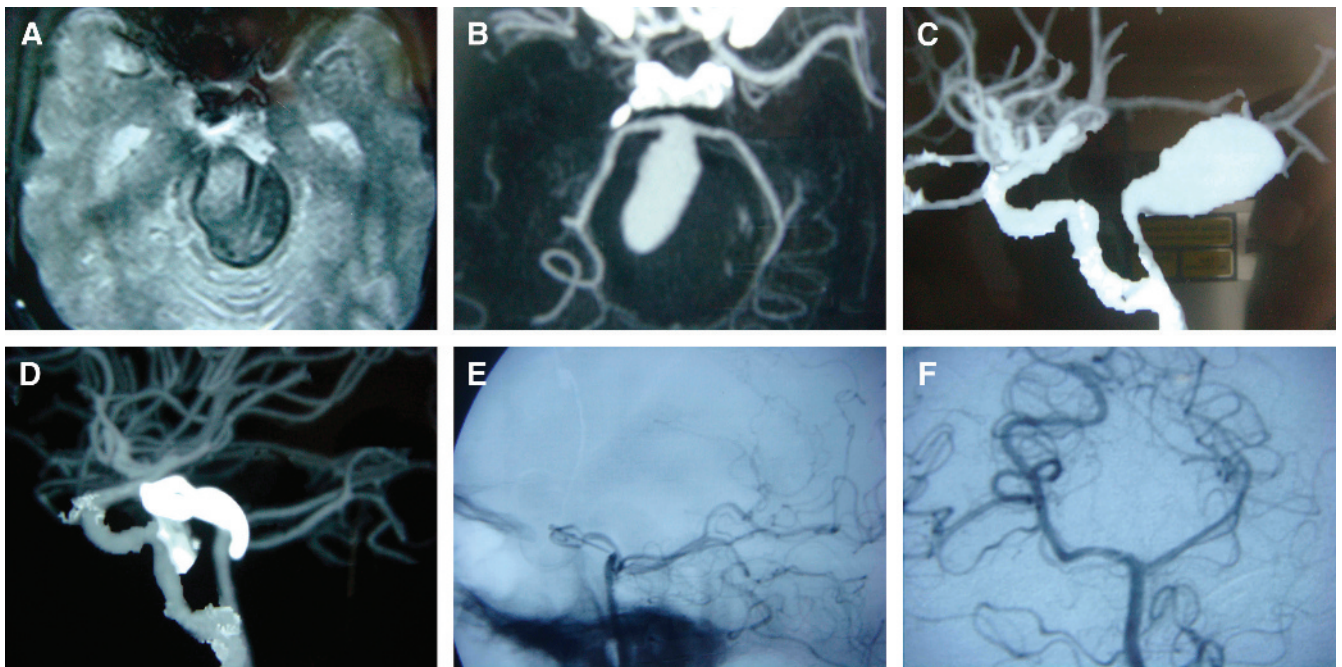


FIGURE 11. A, T2-weighted magnetic resonance imaging of the brain. B and C, computed tomography (CT) angiogram demonstrating a giant partially thrombosed basilar top aneurysm with a significant mass effect on the brainstem. D, postoperative; E, CT angiogram; and F, digital subtraction angiography showing complete obliteration of the aneurysm and preservation of all normal arteries.

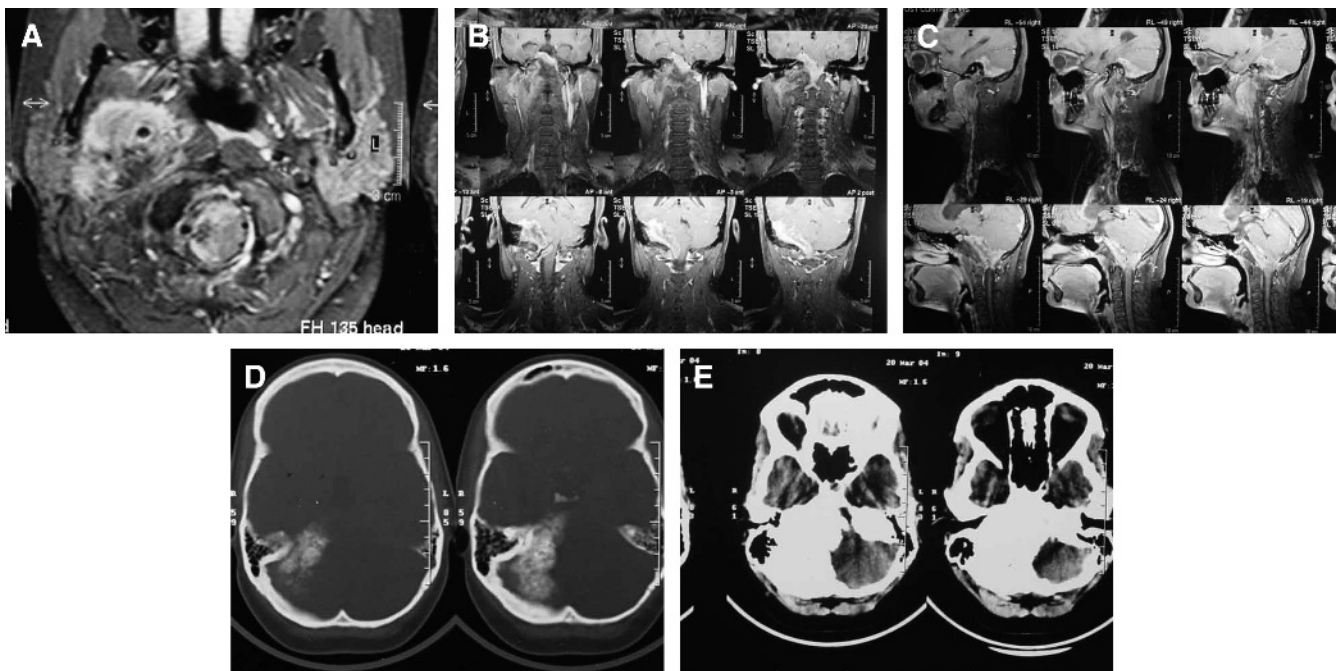


FIGURE 12. Contrast-enhanced magnetic resonance imaging of the brain in the (A) axial, (B) coronal, and (C) sagittal views showing an en plaque–enhancing lesion from the right petrous apex down to the infratemporal fossa. Both the carotid and vertebral arteries are engulfed by the tumor. D and E, computed tomography scan of the brain showing hyperostosis of petrous bone and extensive calcification in the tumor.

excision of benign schwannoma of the jugular foramen was carried out in 2003. Postoperatively, there was dramatic improvement. Except for persistent compensated left 9th and 10th paresis, the patient had no deficit. He continued to have some hoarseness of voice, but swallowing was normal. Follow-up MRI of the brain with contrast showed complete excision of the tumor (Figure 6).

Case 6

A 47-year-old man presented to us in September 1997 with 1-week duration of headache, hoarseness of voice, and mild dysphagia. On examination, he had subtle left IX, X paresis and no other deficit. MRI of the brain demonstrated a jugular foramen tumor occupying the cerebellopontine and cerebellomedullary cistern and the jugular foramen. He was operated on through a retrosigmoid route, and total excision of the cisternal component was achieved, leaving the tumor in the jugular foramen intact in an attempt to preserve lower cranial nerve function. Postoperatively, the patient had persistent hoarseness of voice, but swallowing was normal. At discharge, he had mild left 9th and 10th paresis. Follow-up MRI of the brain confirmed residual tumor in the jugular foramen and complete excision of the intracranial component. The patient was treated by GKR in January 1998. At 11 years of follow-up, the patient continued to have hoarseness of voice but otherwise was asymptomatic. Follow-up MRI of the brain

with contrast enhancement showed a decrease in the residual tumor (Figure 7).

Case 7

A 45-year-old man presented to us in 2000 with a 1-week history of tinnitus and transient right-side hearing impairment. On examination, the patient had no deficit. The hearing had improved, and the audiogram was normal. The patient was advised microsurgery. However, in view of the risks involved, the patient wanted to have GKR. Reluctantly, we treated the patient with GKR. The tumor regressed dramatically by 2 years and remained reduced. The patient over the next 3 years had fluctuating hearing loss and became deaf in the right ear but remained otherwise asymptomatic. At 7 years of follow-up, he developed facial paresis, and imaging showed a cystic lesion. At the 9-year follow-up, the patient had a grade II facial paresis and deafness on right side, but the lower cranial nerve function was normal. MRI of the brain showed regression of the tumor but a small cystic lesion. The patient is under observation (Figure 8).

Case 8

This 61-year-old woman was found unconscious in the bathroom. She was resuscitated in a hospital and brought to the emergency room with endotracheal intubation in May 2009. At admission, her Glasgow Coma Scale score was $E_2M_4V_{ET}$. She improved rapidly and was extubated the next day. Plain

computed tomography (CT) brain scan did not show any evidence of subarachnoid hemorrhage. MRI of the brain and MR angiography demonstrated a large (1.5 cm) basilar trunk aneurysm with mass effect on right side of pons. There was no evidence of any ischemia or infarct of the brain. She had a history of giddiness and imbalance while walking for 2 days before she became unconscious. After discussing the various options for the management of the aneurysm, we decided on microsurgical clipping because the intracranial and neck vessels were very tortuous and the aneurysm was large with a wide neck. A left retrolabyrinthine petrosal approach was used, and the aneurysm was clipped successfully with 2 large titanium clips after a period of temporary clip of the proximal basilar trunk. Postclipping patency of the basilar artery and perforators was checked with indocyanine green dye angiography and microvascular Doppler. Postoperatively, the patient developed right sixth and seventh nerve paresis, and her cerebellar signs worsened. Postoperative CT angiography showed complete occlusion of the aneurysm with patency of all normal arteries. At the 3-month follow-up, the patient had only grade II facial paresis and minimal cerebellar signs (Figure 9).

Case 9

This 24-year-old man was referred to us in October 2009 from an endovascular interventionist colleague with a history of headache, blurred vision of 3 months' duration, and weakness of the right upper limb and face of 2 months. CT angiography and digital subtraction angiography (DSA) revealed a right supraclinoid ventral wall giant aneurysm with a 3.5-cm diameter at its largest. An attempt at endovascular stenting had failed. On admission, the patient was found to have left homonymous hemianopia, left upper motor neuron facial paresis, and a mild left hemiparesis. He was operated on by a right frontotemporal craniotomy, and extradural anterior clinoidectomy was performed. Under propofol burst suppression, temporal clipping of the supraclinoid internal carotid artery, proximal to the aneurysm, was done, and aneurysmorrhaphy was performed by multiple angled fenestrated clips. A small part of the aneurysm was left patent to avoid compromising the anterior choroidal artery. Peroperative indocyanine green dye angiography and microvascular Doppler demonstrated good patency of the parent carotid artery and some residual filling of the aneurysm, which was confirmed by postoperative check DSA. Postoperatively, his headache disappeared and vision improved. He was referred back to the endovascular interventionist for the treatment of the residual aneurysm (Figure 10).

Case 10

This 35-year-old man presented to us in January 2009 with history of instability of gait of 5 months with recent worsening, an inability to perform fine movements of both hands of

3 months' duration, and unprovoked, inappropriate, and uncontrolled spells of laughter of 3 months' duration. On examination, he had left-side deafness, had bilateral cerebellar and pyramidal signs, and was unable to walk without support. MRI, DSA, and CT angiography revealed a partially thrombosed giant (3 cm) basilar top aneurysm with significant mass effect on the brainstem and associated hydrocephalus. Patient was operated through a right frontotemporal orbitozygomatic craniotomy with extradural anterior clinoidectomy and intradural drilling of dorsum sellae. A ventricular drain was inserted, and the aneurysm was exposed through a transylvian route. After defining both the posterior cerebral arteries and dissecting away the perforators, the aneurysm neck was secured by 2 large curved titanium clips. Peroperative indocyanine green dye angiography showed satisfactory, complete occlusion of the aneurysm with good filling of the basilar and all its branches. The patient made a slow recovery and needed ventilatory support and an external ventricular drain in the postoperative period. At 3 weeks, the patient was fully conscious, was ambulatory with support, and had right third nerve palsy and left hemiparesis. At 3 months, the patient was independent with significant recovery of third nerve and minimal cerebellar signs. Postoperative DSA, CT, and CT angiography demonstrated complete occlusion of the aneurysm and no evidence of infarct (Figure 11).

Case 11

This 29-year-old woman, a physical education instructor and avid outdoors person, presented to us in 2004 with a long history of a weak voice at the end of the day and a diagnosis of idiopathic left vocal cord paralysis by an otolaryngologist. On examination, she had left 9th and 10th nerve palsy and no other deficit.

Her imaging, CT, MRI, and DSA revealed an extensive, heavily calcified, en plaque lesion extending from the petrous apex to the infratemporal fossa. Both the left carotid and left vertebral arteries were completely engulfed by tumor, as were the lower cranial nerves. The working diagnosis was hyperostosing meningioma of the left petrous bone (Figure 12). Because she had very minimal nondisabling symptoms and because the risk of any intervention was significantly high without any possibility of eradicating the lesion, the patient was counseled and advised periodic follow-up with yearly MRI of the brain. At 5 years, the lesion remained static, and the patient had not developed any new clinical features (Figure 12).

CONCLUSION

Skull base surgery requires dedicated personnel who are willing to undergo rigorous specialized training, including many months in the laboratory for cadaver dissection, and are prepared to commit to long hours in the operating theater. Surgeons are then often rewarded with successful outcomes in seemingly hopeless cases. No effort should be spared to cure a fellow human being whenever possible. However, it is

essential to remember that there are occasions when the nature of the lesion does not allow the neurosurgeon to eradicate it without damaging the patient, no matter how radical the approach and how competent the surgeon. It is also true that some of these problems can be better managed by less invasive methods. Optimal use of all available modalities of treatment needs the right judgment, and the ability to judge comes from experience. Although one's own experience is the best teacher, it is also painful, the pain of complications. Some alleviation of this pain is possible by spending time with master surgeons, being current on the evidence in the literature, and never forgetting one's own complication.

Disclosure

The author has no personal financial or institutional interest in any of the drugs, materials, or devices described in this article.

REFERENCES

- Pandya SK. Neurological Society of India: a brief history. In: Pandya SK, ed. *Neurosciences in India: Neurosciences in India Retrospect and Prospect*. Trivandrum, India: Neurological Society of India; 1989:683-690.
- Misra BK. Jugular foramen tumors: how I do it? *Prog Clin Neurosci*. 2003;18:88-93.
- Misra BK, Purandare HR, Ved RS, Bagadia AA, Mare PB. Current treatment strategy in the management of vestibular schwannoma. *Neurol India*. 2009;57(3):257-263.
- Misra BK. Management of central skull base tumors. In: Sindou M, ed. *Practical Handbook of Neurosurgery*. New York, NY: Springer Wien; 2009:115-128.
- Sindou M, Wydh E, Jouanneau M, Nebbal M, Liehtared T. Long term follow up of meningiomas of the cavernous sinus after surgical treatment alone. *J Neurosurg*. 2007;107(5):937-944.
- Al Mefty O, Fox JK, Smith RR. Petrosal approach for petroclival meningiomas. *Neurosurgery*. 1988;22:510-517.
- Bricolo AP, Turazzi S, Takachi A, Cristofori L. Microsurgical removal of petroclival meningiomas: a report of 33 patients. *Neurosurgery*. 1992;31(5):813-828.
- Kawase T, Shiobara R, Toya S. Anterior transpetrosal transtentorial approach for sphenopetroclival meningiomas: surgical method and results in 10 patients. *Neurosurgery*. 1991;28(6):869-876.
- Misra BK. Surgical approaches to petroclival region. *Prog Clin Neurosci*. 1999;14:183-192.
- Sami M, Ammirati M, Mahran A, Bini W, Sefhria A. Petroclival meningiomas: report of 24 cases. *Neurosurgery*. 1989;24(1):12-17.
- Sekhar LN, Jannetta PJ, Burkhart L, Janosky JE. Meningiomas involving the clivus: a six year experience with 41 patients. *Neurosurgery*. 1990;27(5):764-781.
- Yasargil MG, Mortara RW, Curic M. Meningiomas of the basal posterior cranial fossa. In: Krayenbuhl H, ed. *Advances and Technical Standards in Neurosurgery*. Vienna, Austria: Springer Verlag; 1980:7:1-115.
- Adachi K, Kawase T, Yoshida K, Yazaki T, Oruzuka. ABC surgical risk scale of skull base meningioma: a new scoring system for predicting the extent of tumor removal and neurological outcome. *J Neurosurg*. 2009;111(5):1053-1061.
- Bombakidis NC, Kakarla UK, Kim LJ, et al. Evolution of surgical approaches in the treatment of petroclival meningiomas: a retrospective review. *Neurosurgery*. 2007;61(5)(Suppl 2):ONS202-ONS211.
- Little KM, Friedman AH, Simpson JH, Wanibuchi M, Fukushima T. Surgical management of petroclival meningiomas: differing resection goals bases on risk of neurological morbidity and tumor resection rates in 137 patients. *Neurosurgery*. 2005;56:546-559.
- Natarajan SK, Sekhar LN, Schessel D, Morita A. Petroclival meningiomas: multimodality treatment and outcomes at long term follow-up. *Neurosurgery*. 2007;60(6):965-981.
- Bindal R, Goodman JM, Kawasaki A, Purvin V, Kuzma S. The natural history of untreated skull base meningiomas. *Surg Neurol*. 2003;59(2):87-92.
- Jung HW, Yoo H, Park SH, Choi KS. Long term outcome and growth rate of subtotally resected petroclival meningiomas: experience with 38 cases. *Neurosurgery*. 2000;46(3):567-575.
- Mathiesen T, Gerlich A, Kihlstrom L, Svensson M, Sjoback DB. Effects of using combined transpetrosal surgical approaches to treat petroclival meningiomas. *Neurosurgery*. 2007;60(6):982-992.
- Roche PD, Pellet W, Fuentes S, Thomassini JM, Regis J. Gammaknife radiosurgical management of petroclival meningiomas: results and indications. *Acta Neurochir (Wien)*. 2003;145(10):883-888.
- Takamashi M, Fukoka S, Hojyo A, Sasaki T, Nakagawara J, Nakamura H. Gammaknife Radiosurgery for skull base meningioma. *Prog Neurol Surg*. 2009;22:96-111.
- Guglielmi G, Vinuela F, Dion J, et al. Electrothrombosis of saccular aneurysms via an endovascular approach, part 2: preliminary clinical experience. *J Neurosurg*. 1991;75(1):8-14.
- International subarachnoid Aneurysm Trial (ISAT) Collaborative Group. International Subarachnoid Aneurysm Trial (ISAT) of neurosurgical clipping versus endovascular coiling in 2143 patients with ruptured intracranial aneurysms: a randomized trial. *Lancet*. 2002;360:1267-1274.
- Gonzalez LF, Amin Harjani S, Bambakidis NC, Spetzler RF. Skull base approaches to the basilar artery. *Neurosurg Focus*. 2005;19(2):E3.
- Krisht AF, Krayenbuhl N, Sercel Di Bikmaz K, Kadri PA. Results of microsurgical clipping of 50 high complexity basilar apex aneurysms. *Neurosurgery*. 2007;60(2):242-250.
- Misra BK. Posterior circulation aneurysm: surgical approach. *Prog Clin Neurosci*. 2000;15:83-89.
- Ojemann RG. Management of acoustic neuroma. *Clin Neurosurg*. 1993;40:498-535.
- Misra BK. Management strategy in acoustic neuroma. In: Garcia-Ibanez E, Tran Ba Huy P, eds. *5th International Conference on Vestibular Schwannoma and Other CP Angle Lesions*. Bologna: Medimond. 2007;47-52.
- Raut VV, Walsh RM, Bath AP, et al. Conservative management of vestibular schwannomas: second review of a prospective longitudinal study. *Clin Otorhinolaryngol Allied Sci*. 2004;29(5):505-514.
- Wiebers DO, Whistnaut JP, Huston J III, et al. Unruptured intracranial aneurysms natural history, clinical outcome, and risks of surgical and endovascular treatment. *Lancet*. 2003;362(9378):103-110.
- Misra BK. Treatment strategy in jugular foramen tumors. In: Garcia-Ibanez E, Tran Ba Huy P, eds. *5th International Conference on Vestibular Schwannoma and Other CP Angle Lesions*. Bologna: Medimond. 2007;71-76.